

DIU D'ECHOGRAPHIE ET TECHNIQUES ULTRA SONORES

MODULE DIGESTIF

2020/2021



Notion d'écho-anatomie et de pathologie des gros vaisseaux abdominaux

Professeur Etienne DANSE

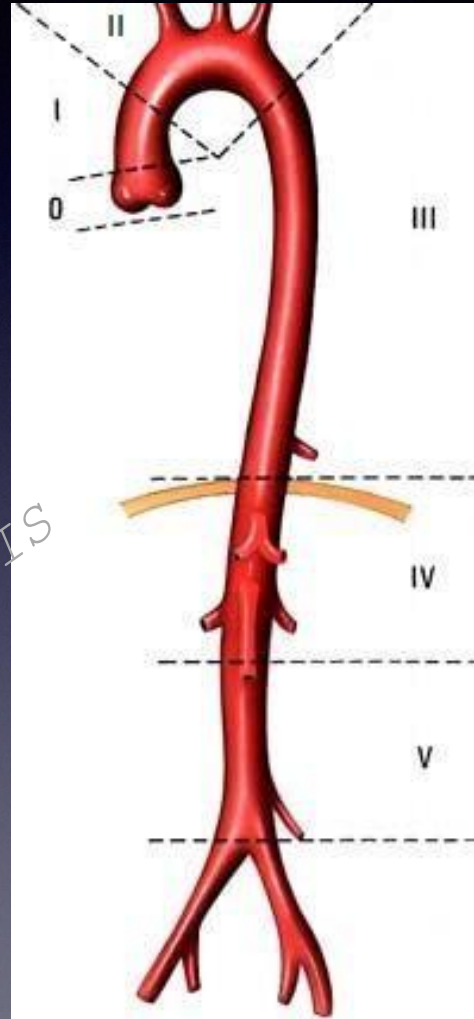
Université Catholique de Louvain Cliniques Universitaires St Luc , 1200
Bruxelles

Docteur Pascale PLAQUET CAMUS

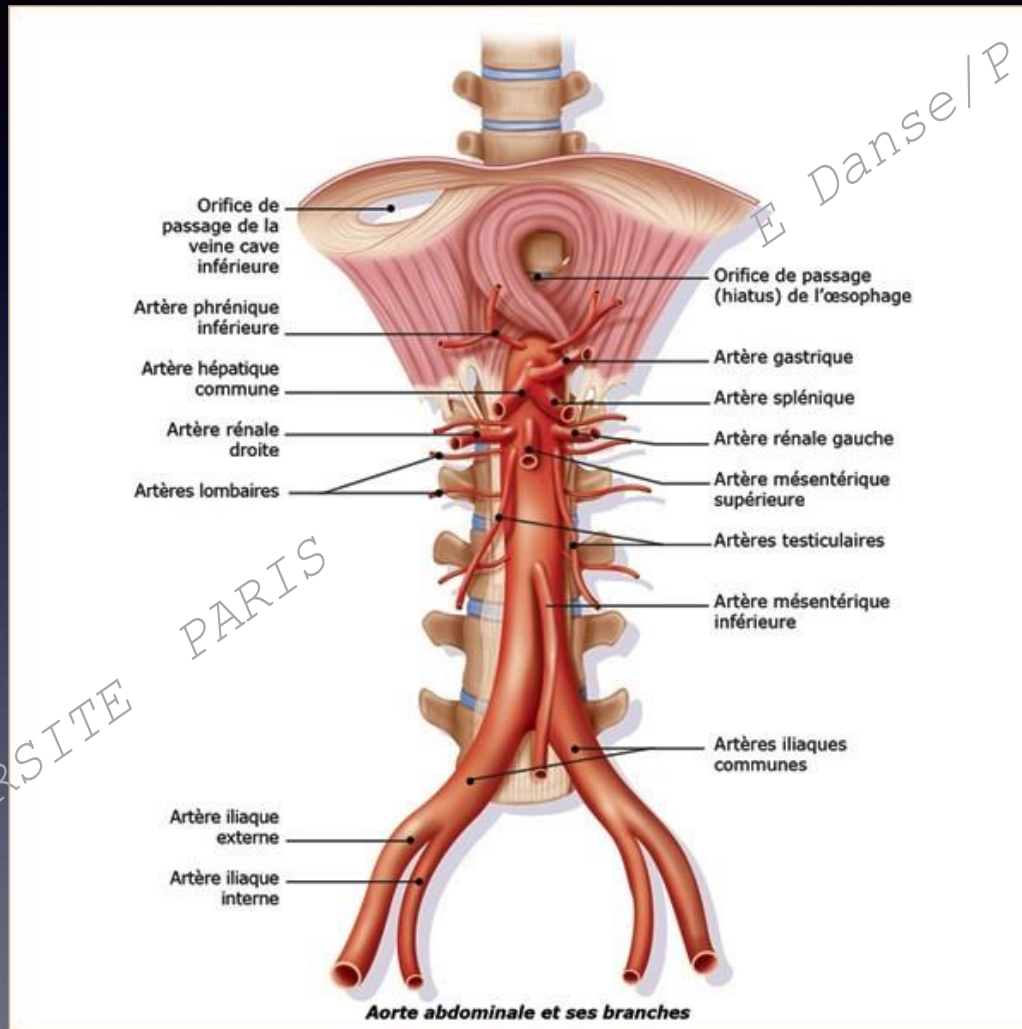
Docteur Pascale PLAQUET CAMUS

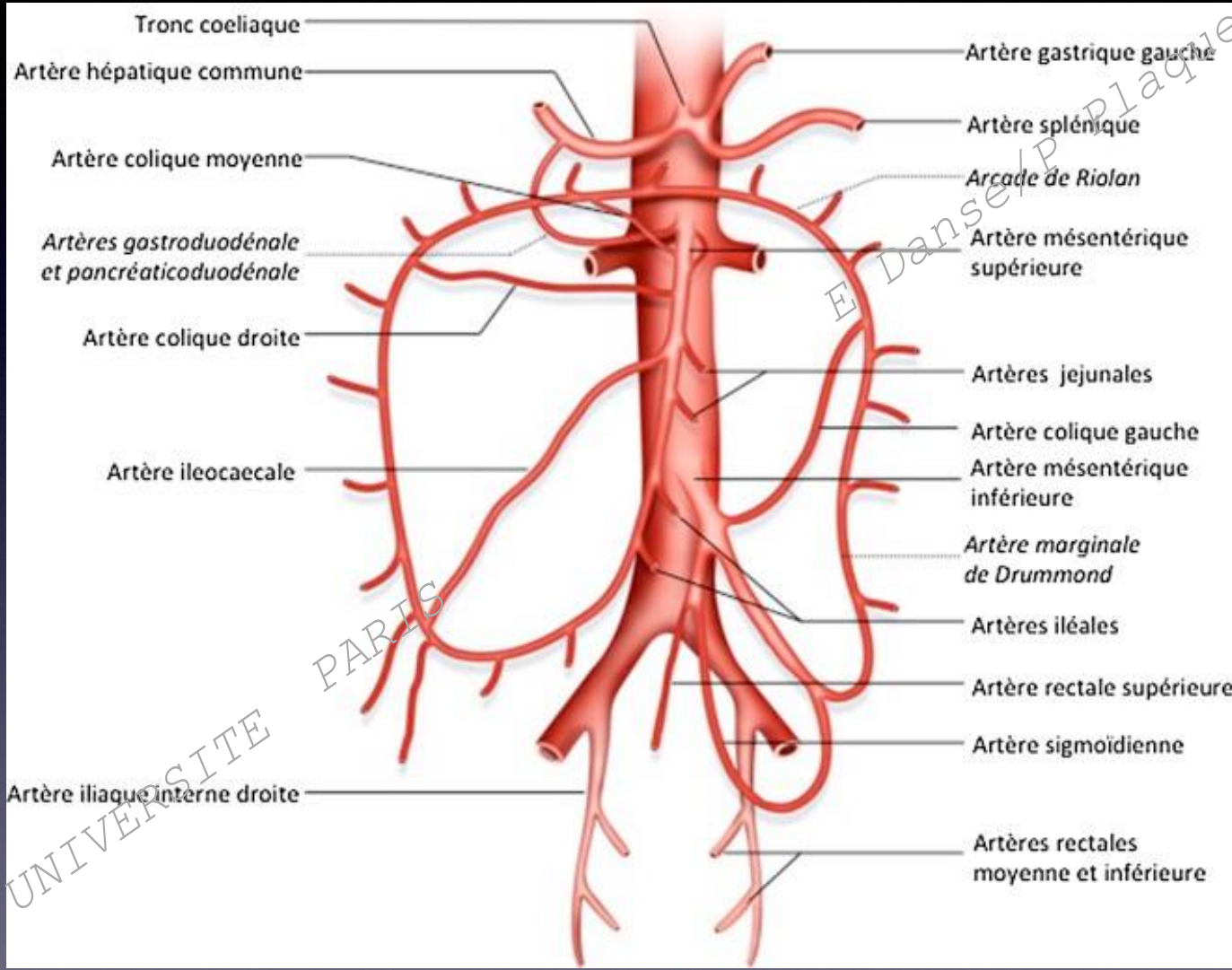
CHU Amiens - Péronne

Echo-anatomie des gros vaisseaux abdominaux



Echo-anatomie des gros vaisseaux abdominaux





DIU UNIVERSITE PARIS

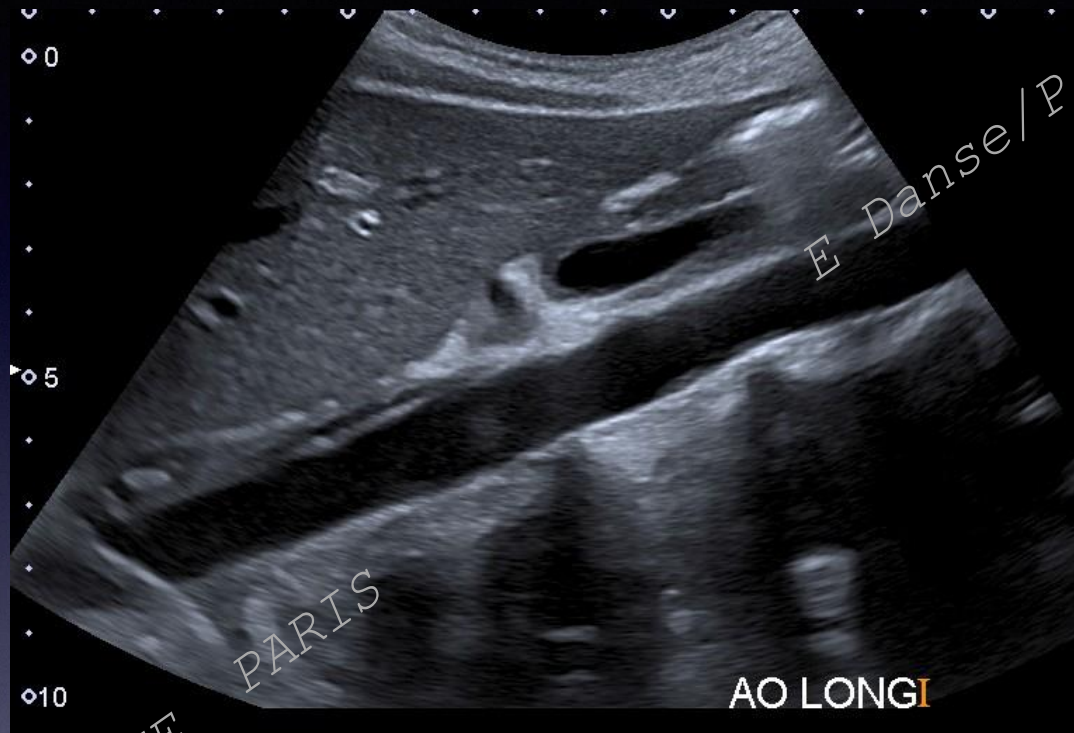E. Dansel/Plaquelet

Echo-anatomie des gros vaisseaux abdominaux

Technique d'examen

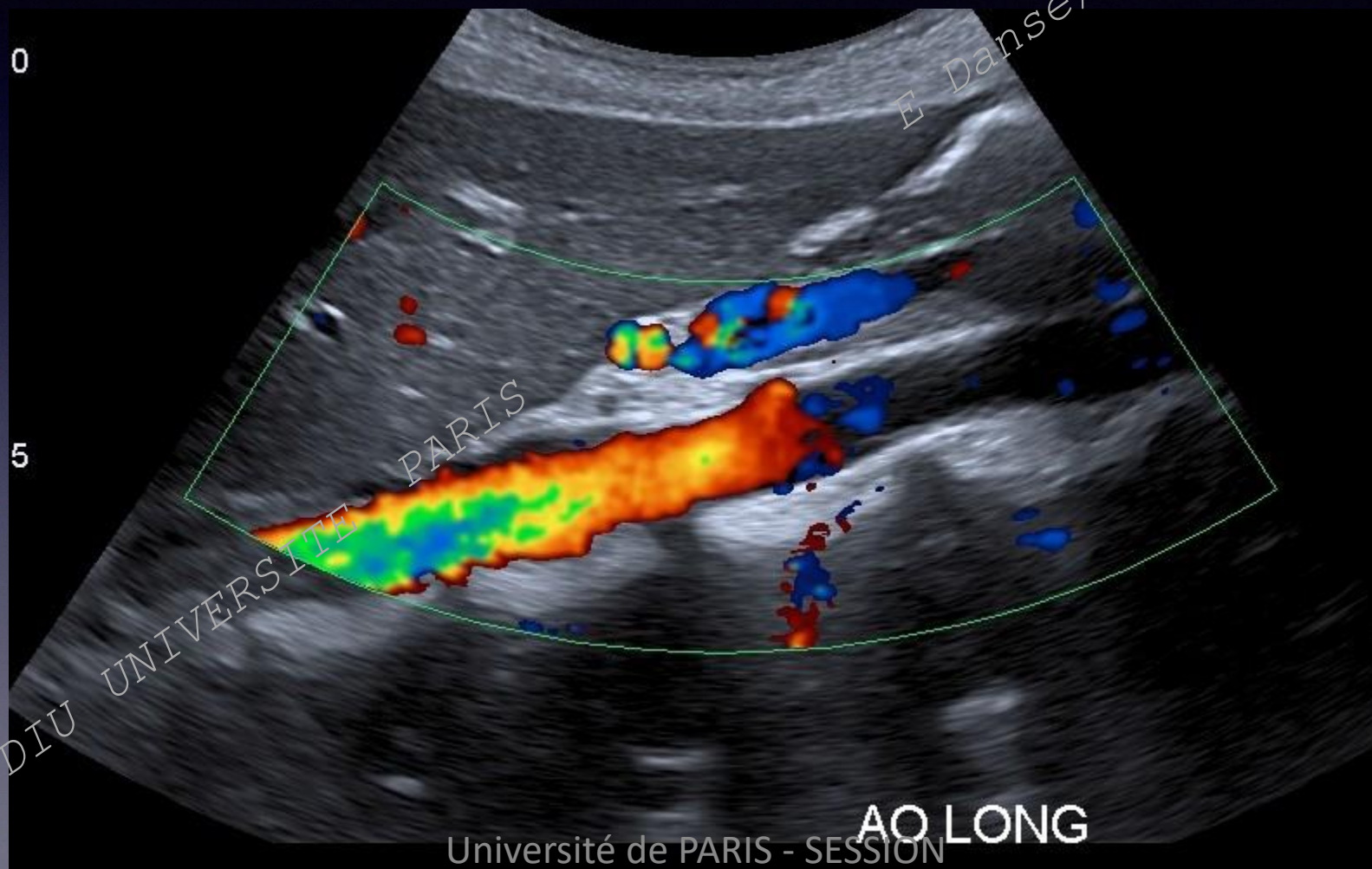
- Décubitus dorsal +/- latéral
- À jeun ,
- pression/ tube digestif
- Coupe transversale et longitudinale
- Sonde sectorielle fréquences adaptées
3/10 mhz THI

Aorte abdominale

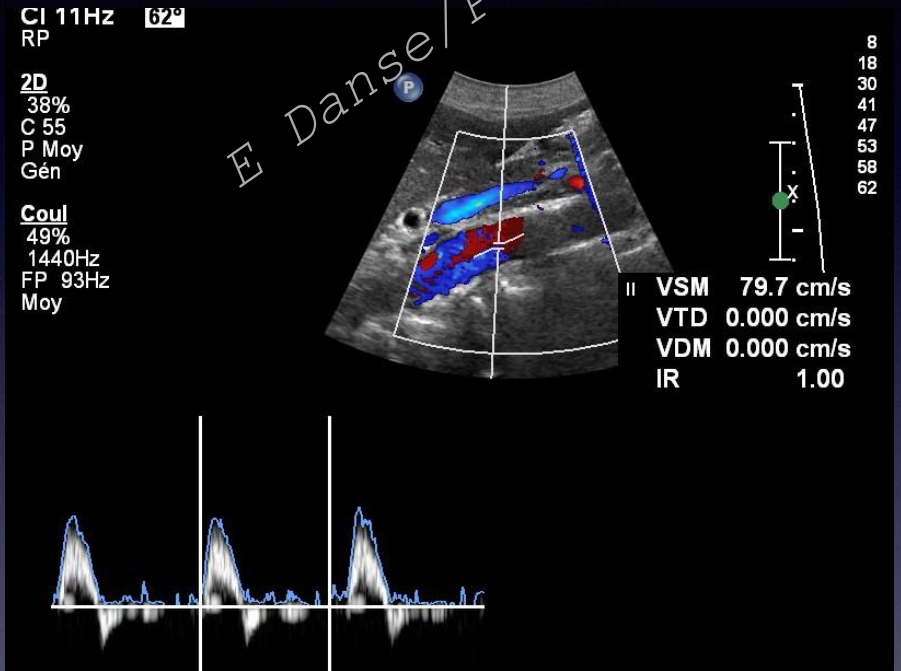
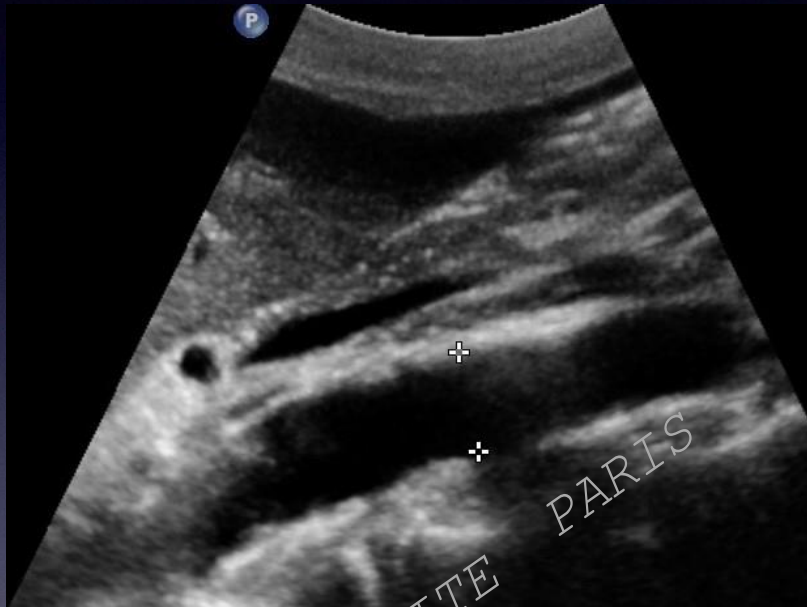

Calibre normal : <28 mm sus rénal
<18 mm sous rénal
Lumière hypo/ anéchogène
Paroi fine et régulière

Aorte abdominale



Aorte abdominale

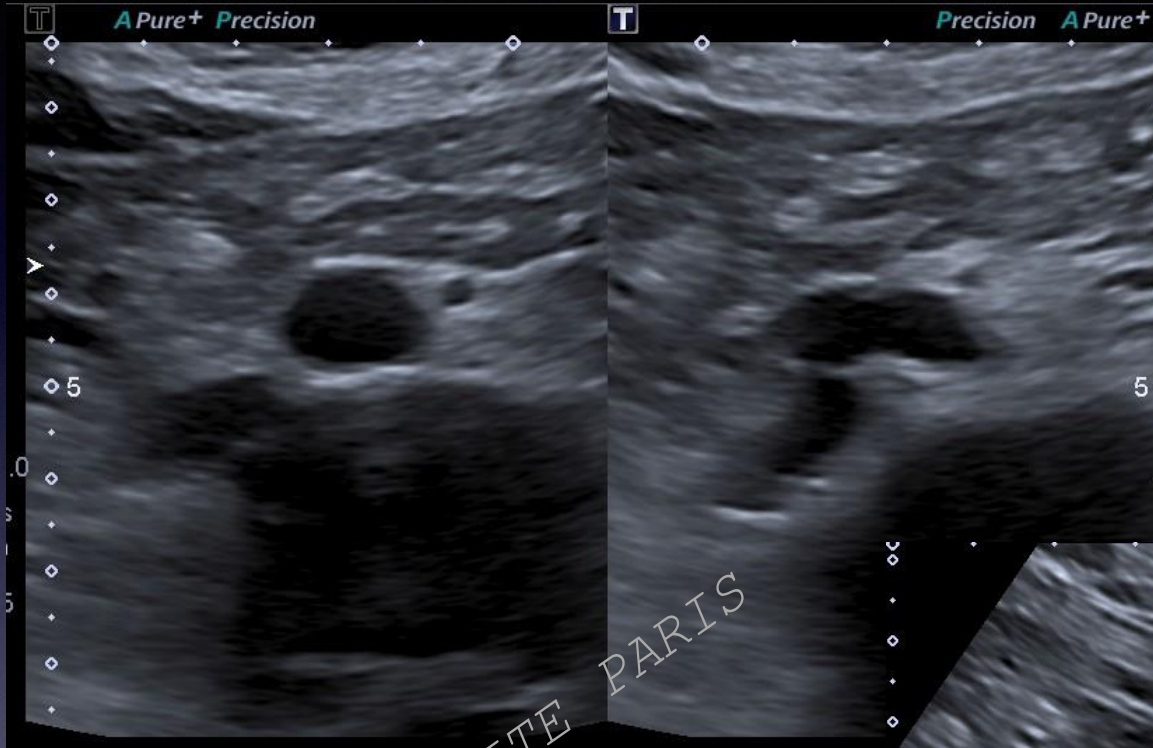


Doppler : flux triphasique
Reflux proto diastolique
v 50- 180 cm/s. v moyenne 40-80 cm/s

Université de PARIS - SESSION

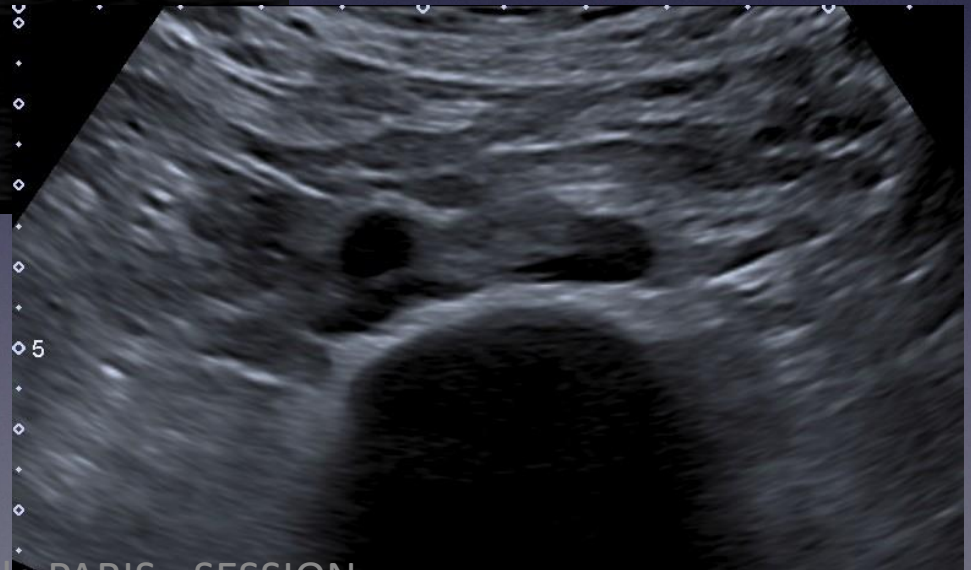2020/2021

Aorte abdominale



E Danse/P Plaquet

Bifurcation



Anévrisme aortique

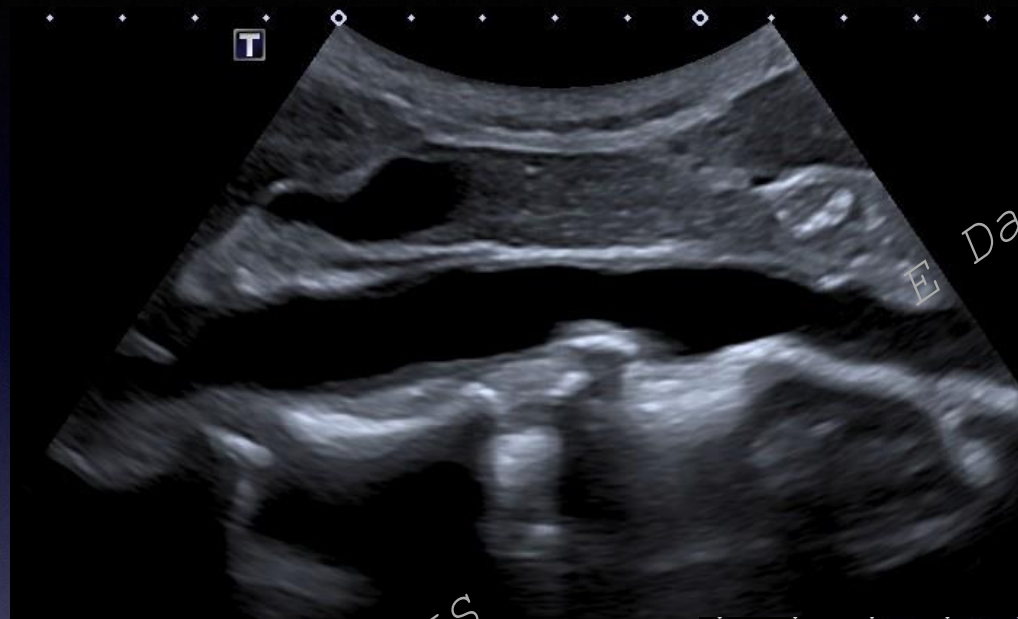E Danse/P Plaquet

Diamètre transverse
> 30 mm
> 40 mm risque de rupture
Plan de coupe / surveillance

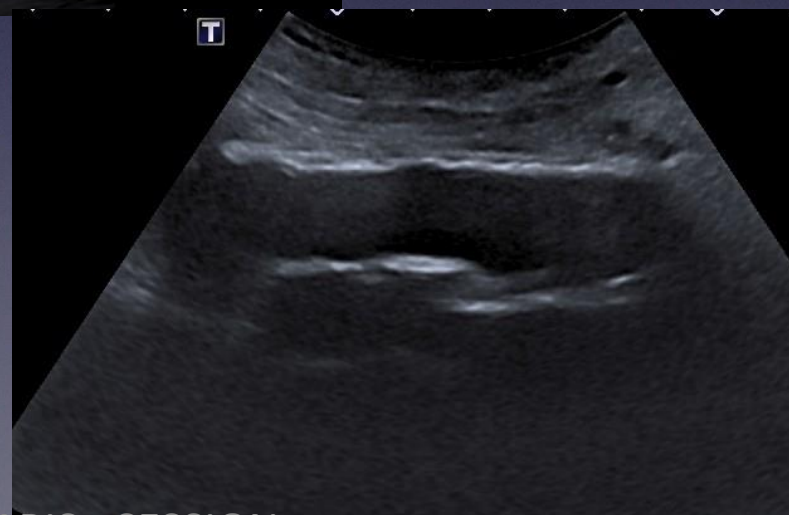
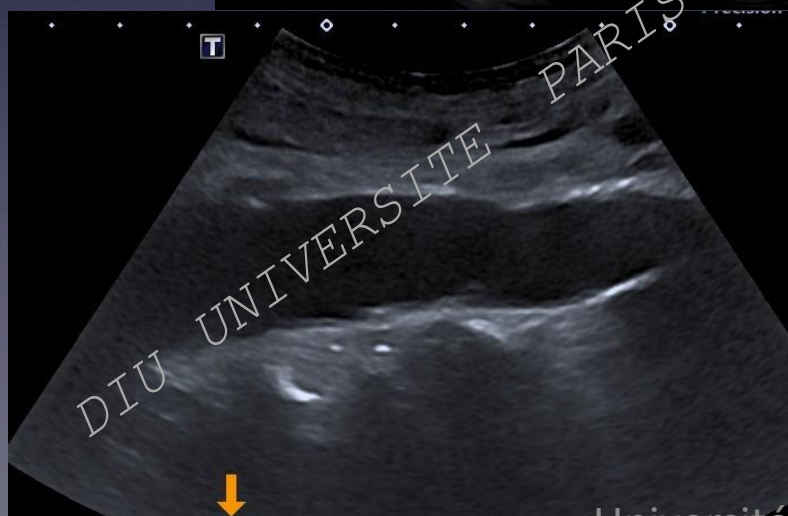Sous rénal ++

Thrombus
Hématome

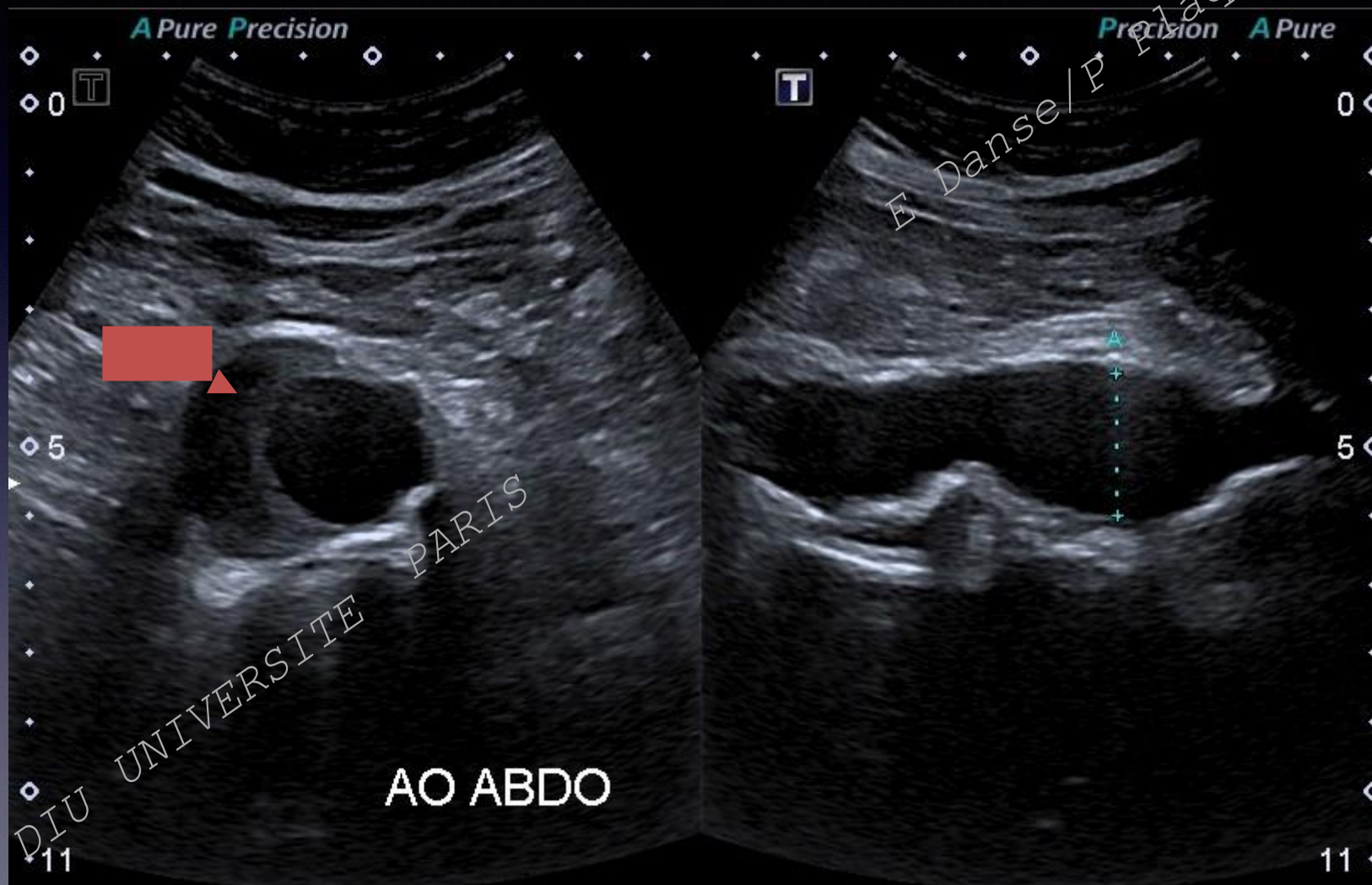
Aorte abdominale contours , paroi



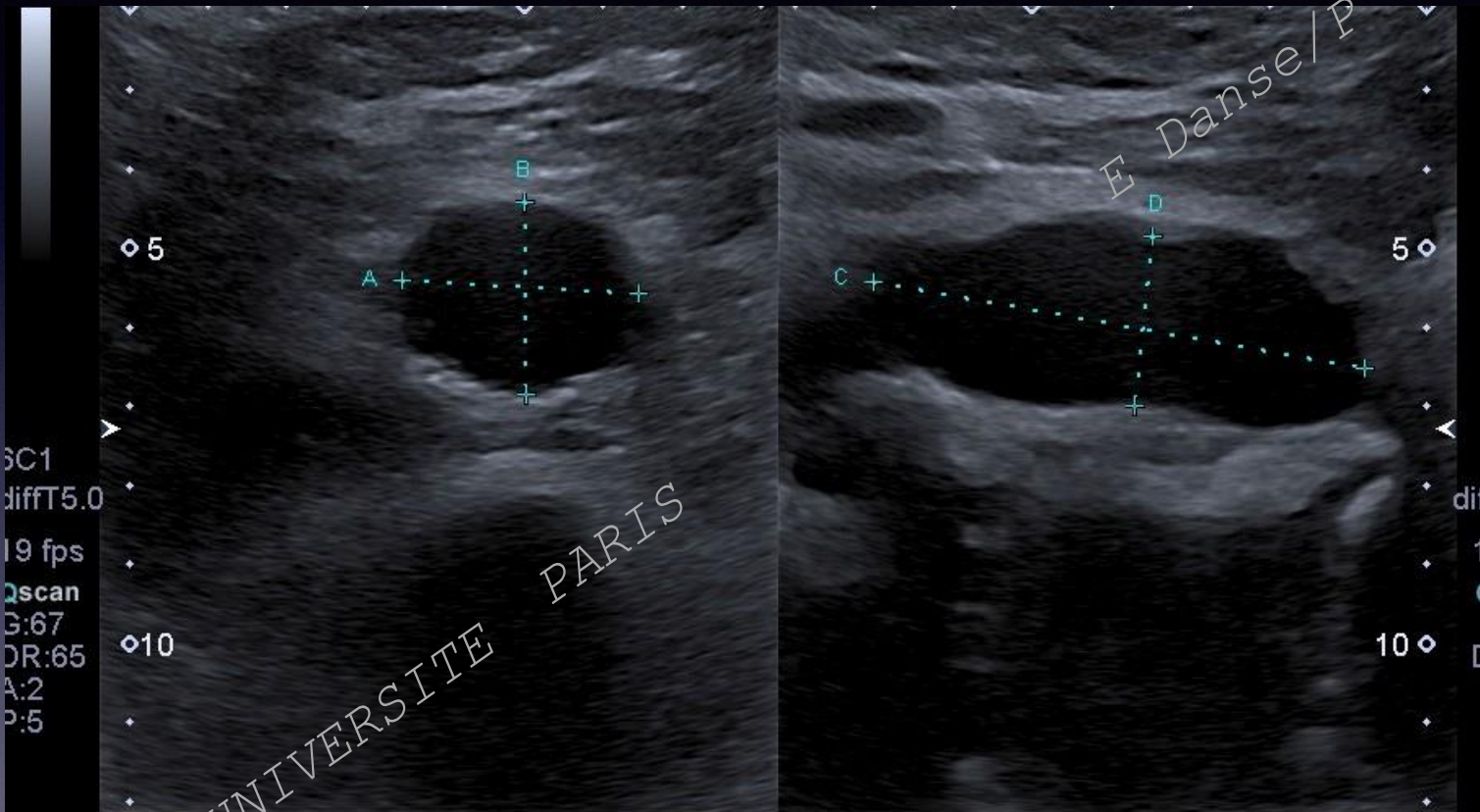
E Danse/P Plaquet



Anévrysme aortique

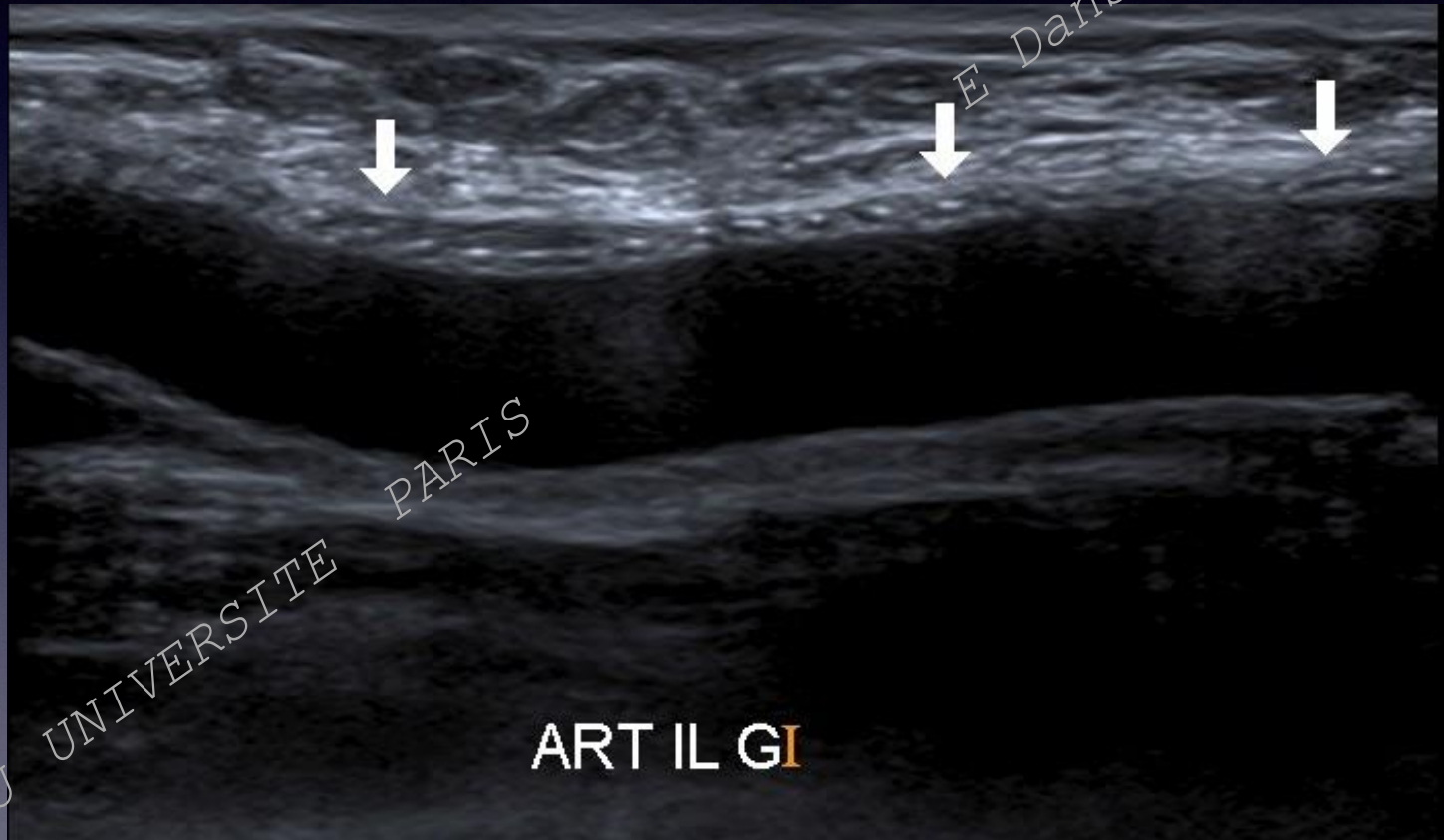


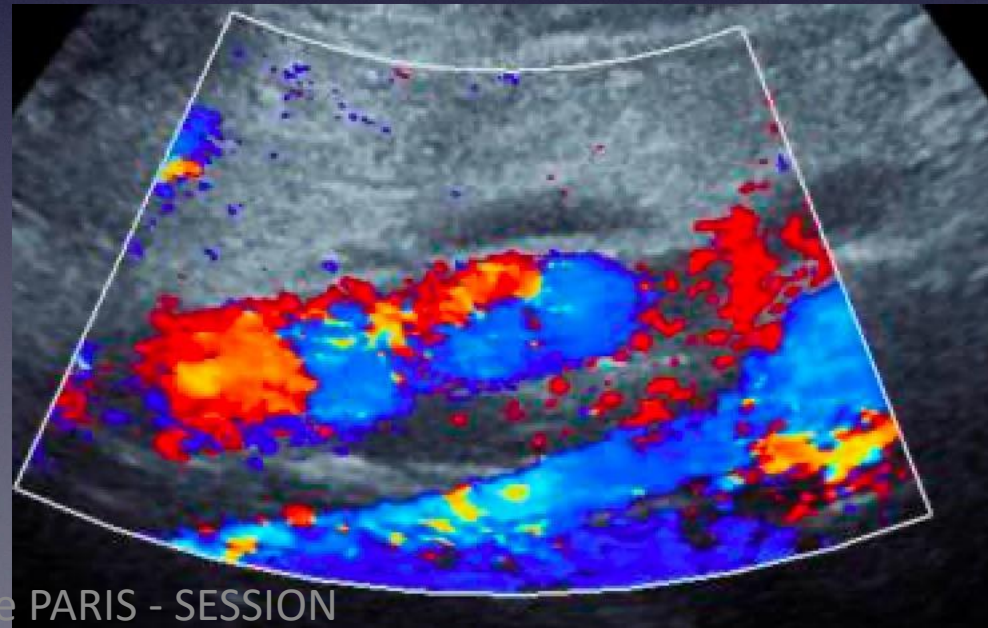
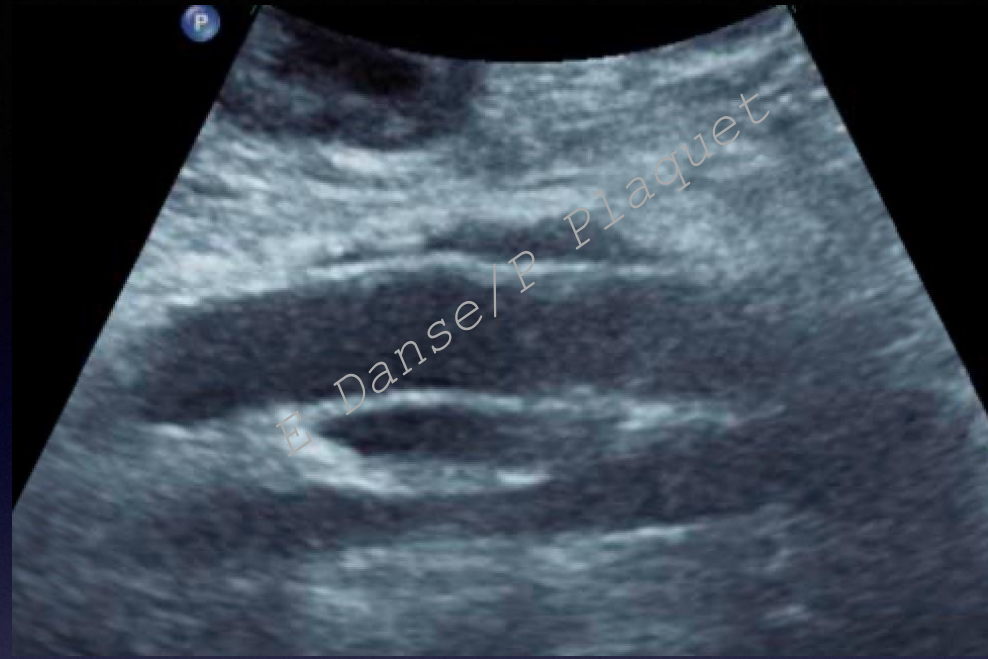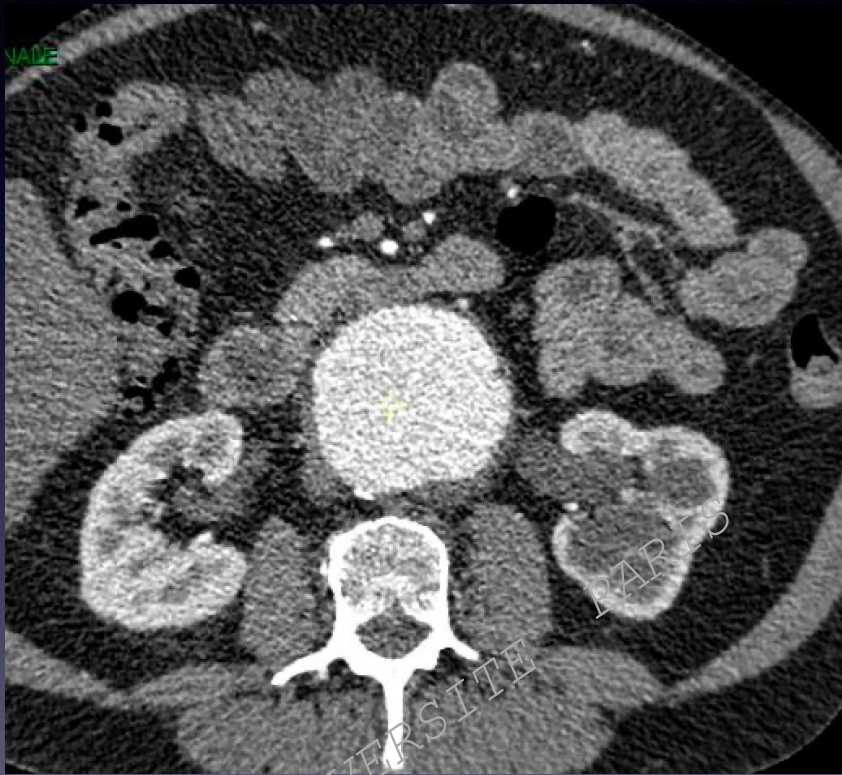Anévrysme aortique



Dist A	30.0 mm	Dist B	24.3 mm	Dist C	63.0 mm
Dist D	21.6 mm	Université de PARIS - SESSION			

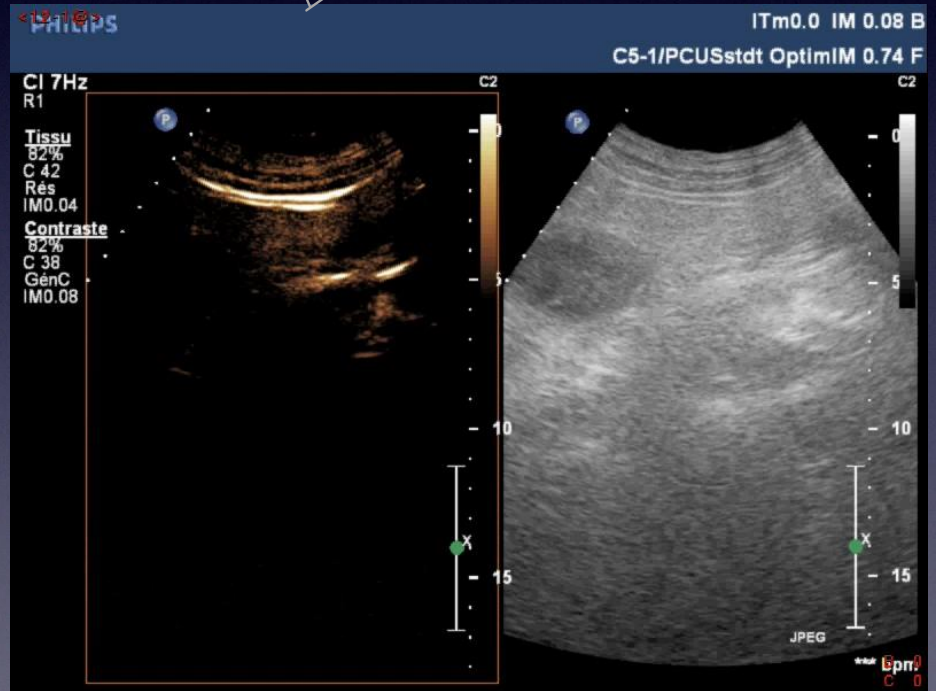
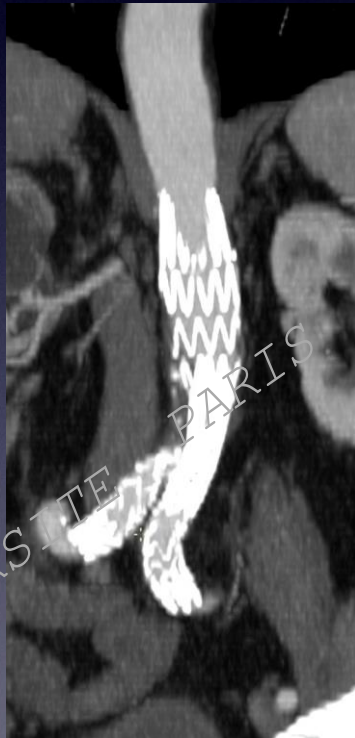
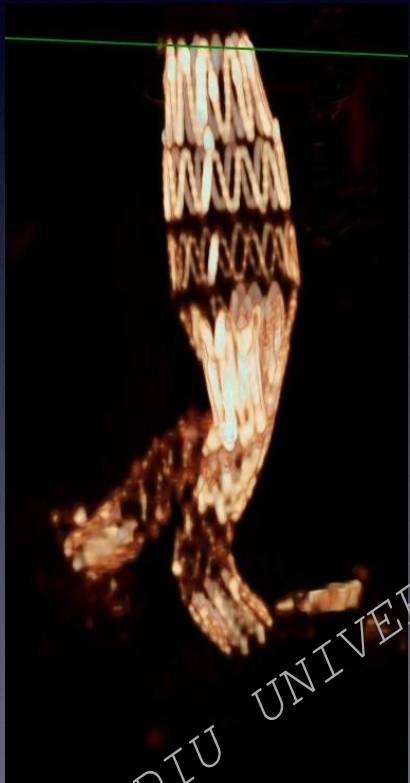
Endoprothèse

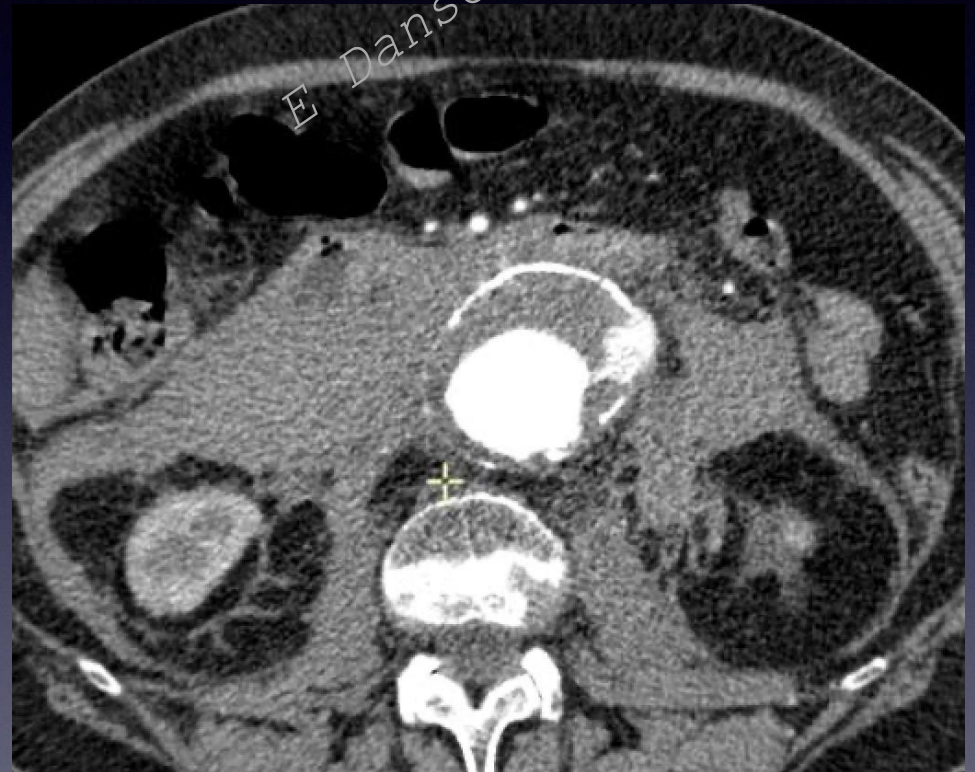
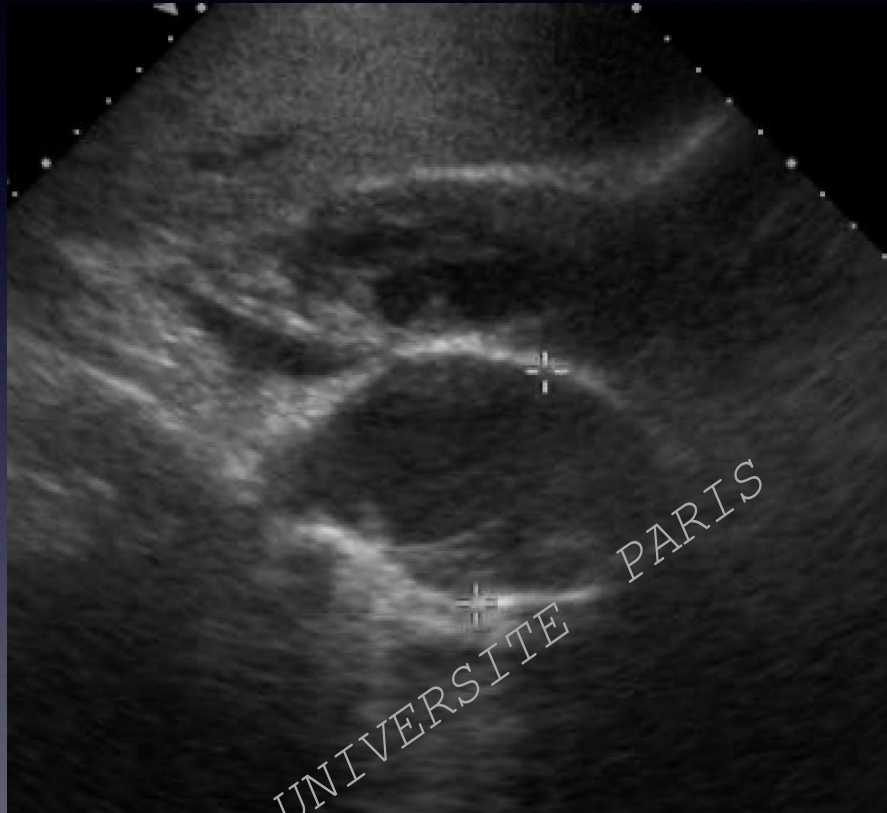
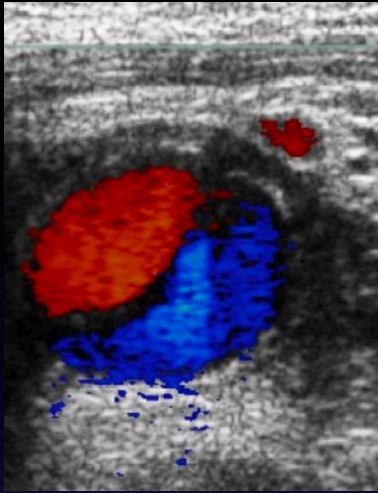


Endoprothèse

E Danse/P Plaquet

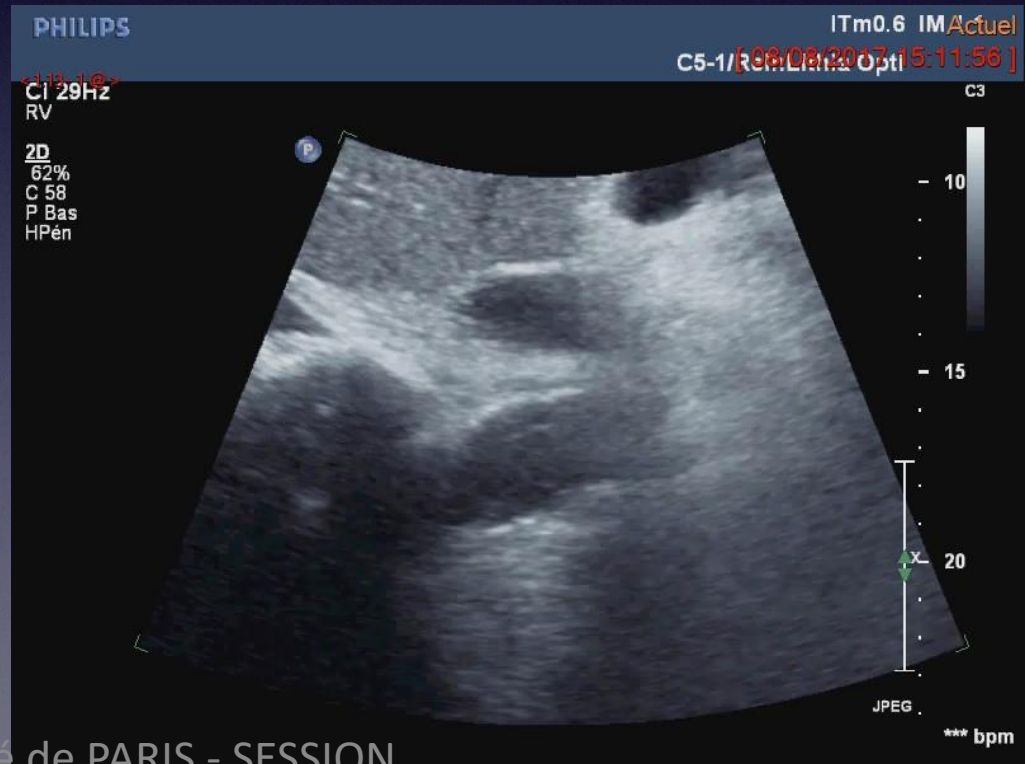
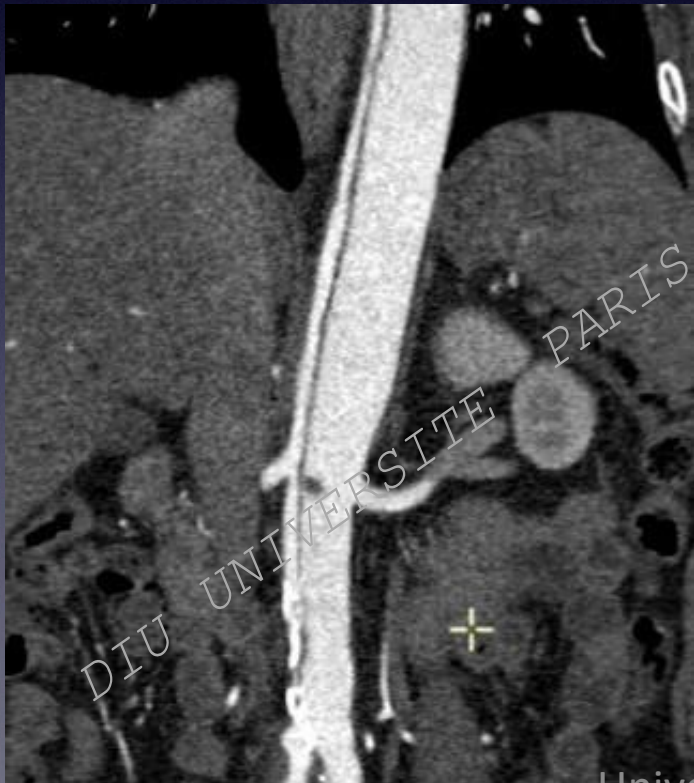


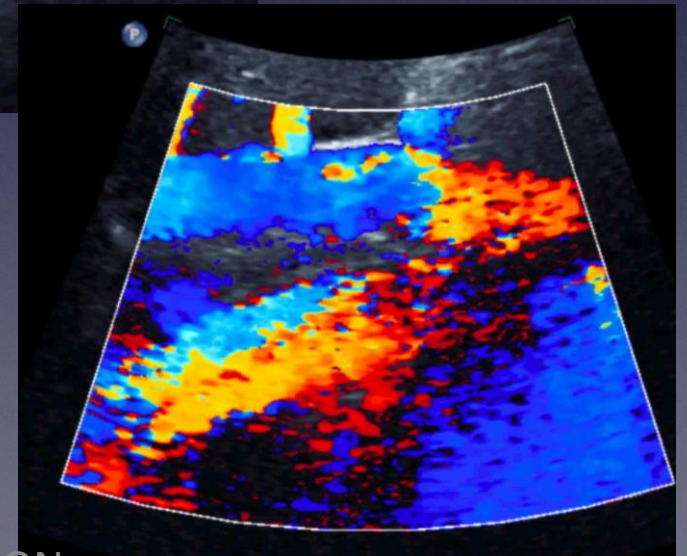
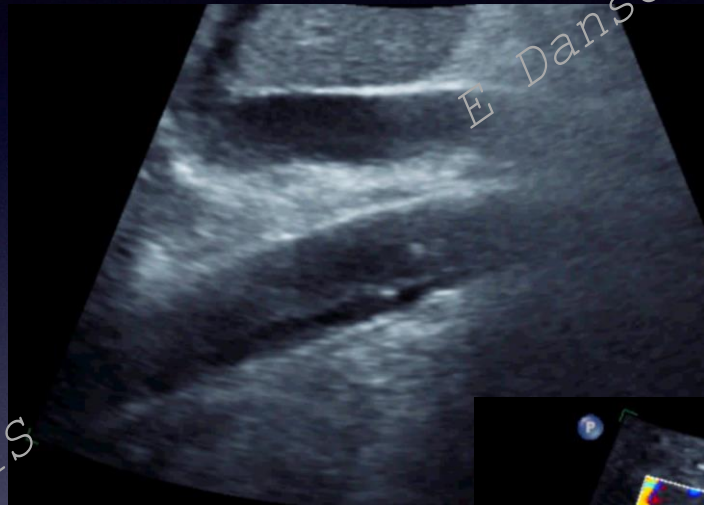


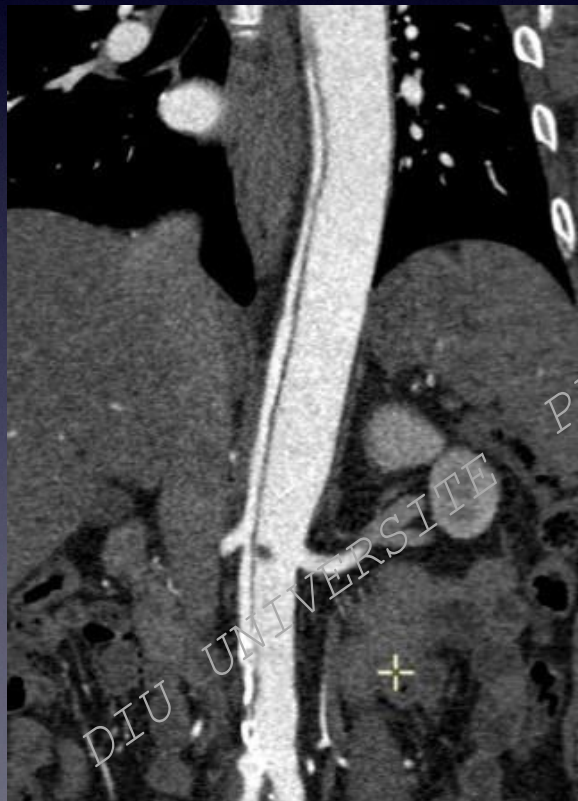Dissection aortique

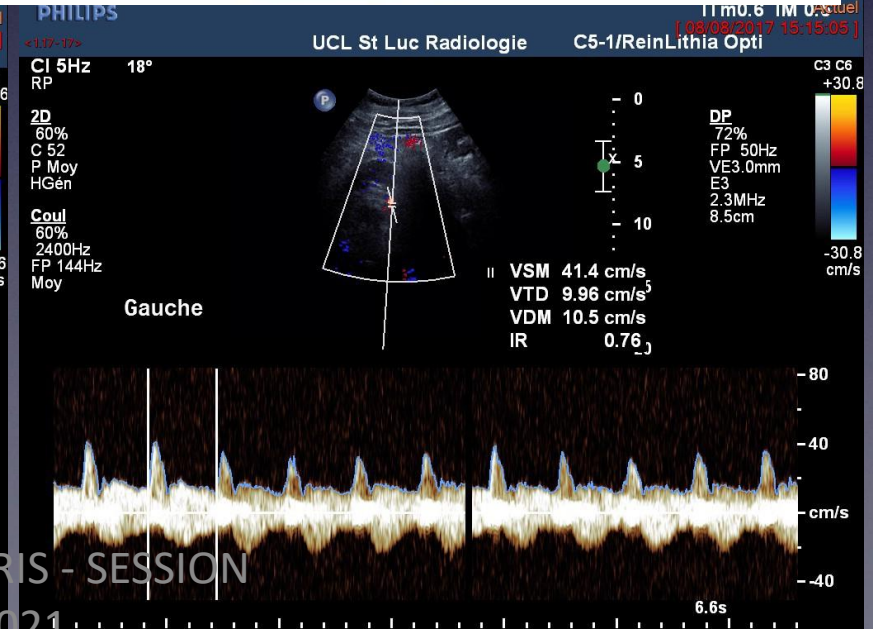
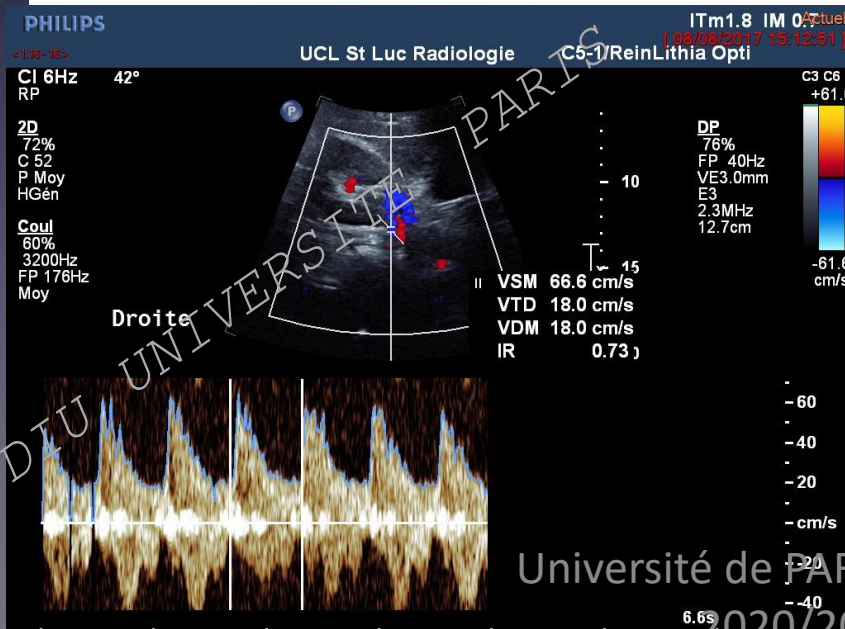
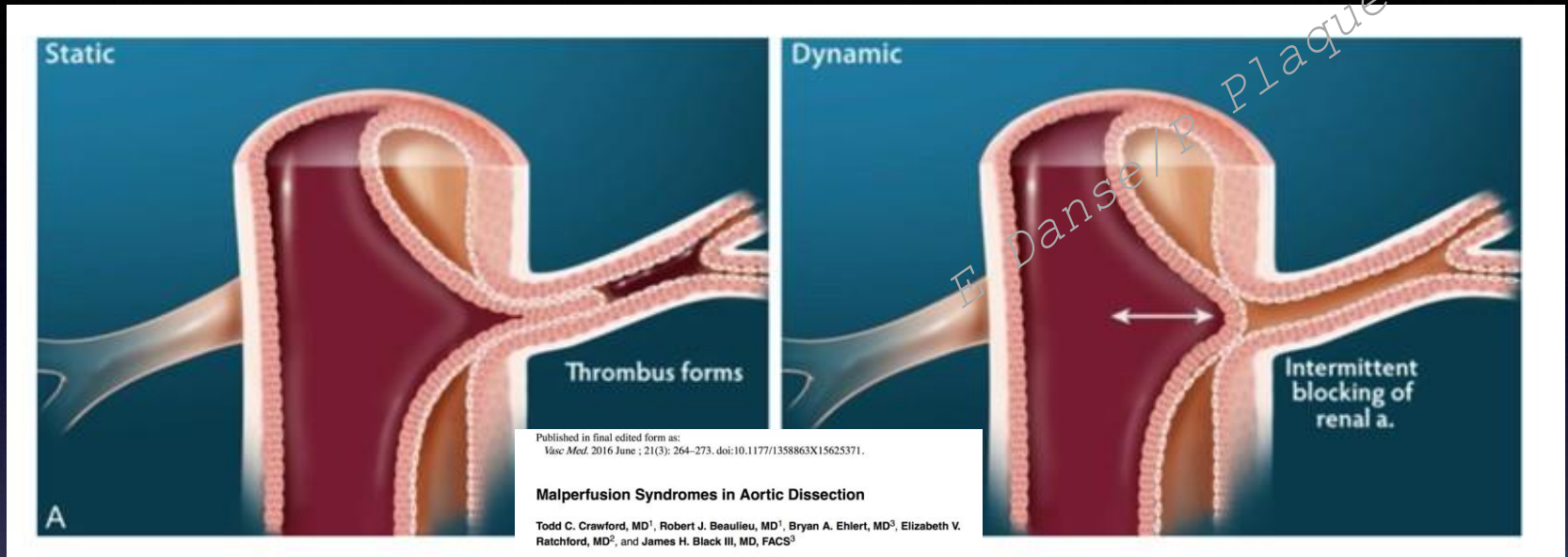E Danse / P Plaquet



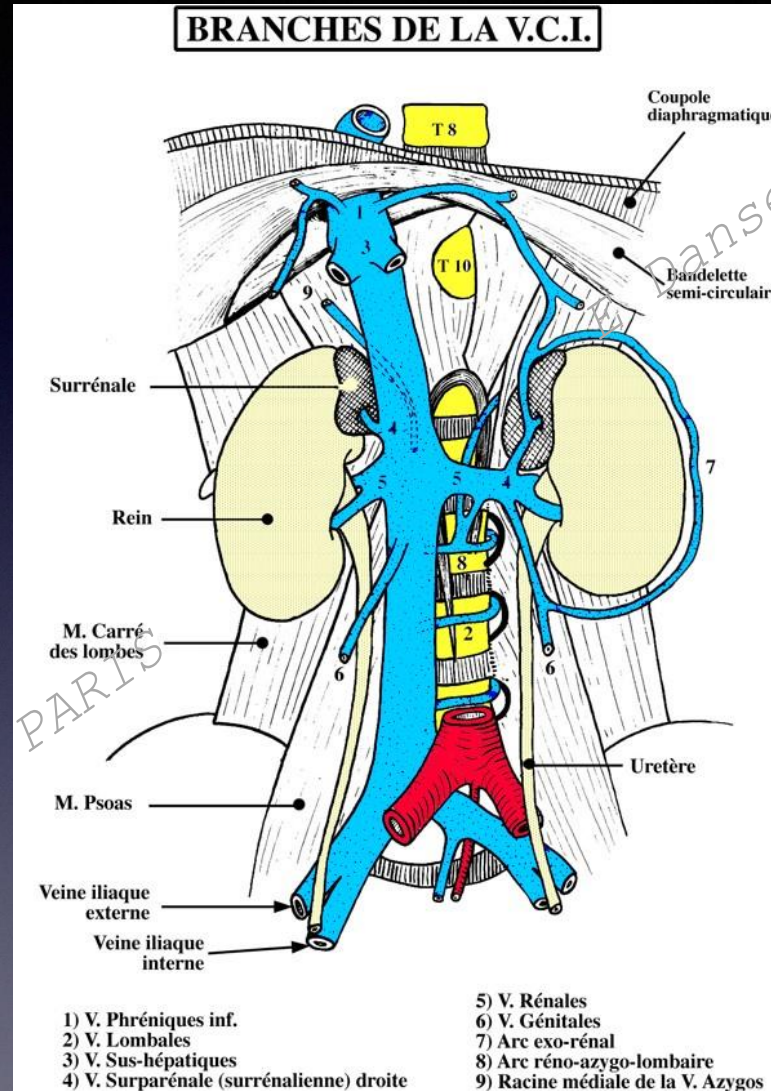
Dissection aortique



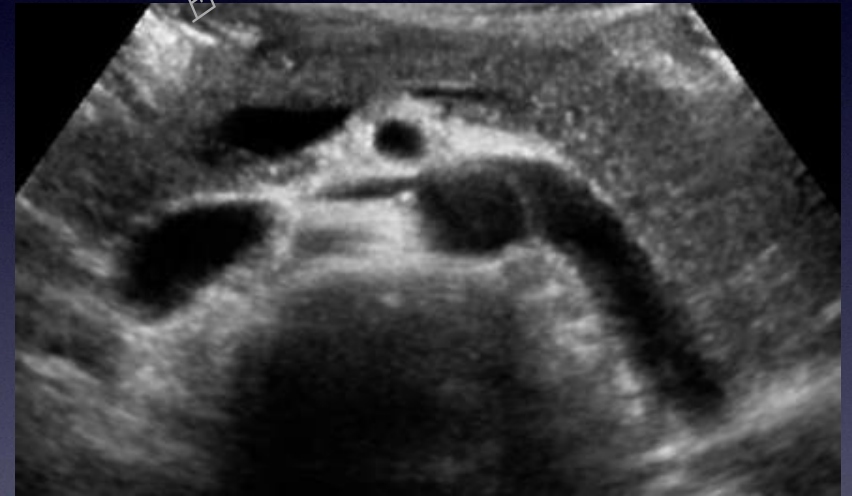
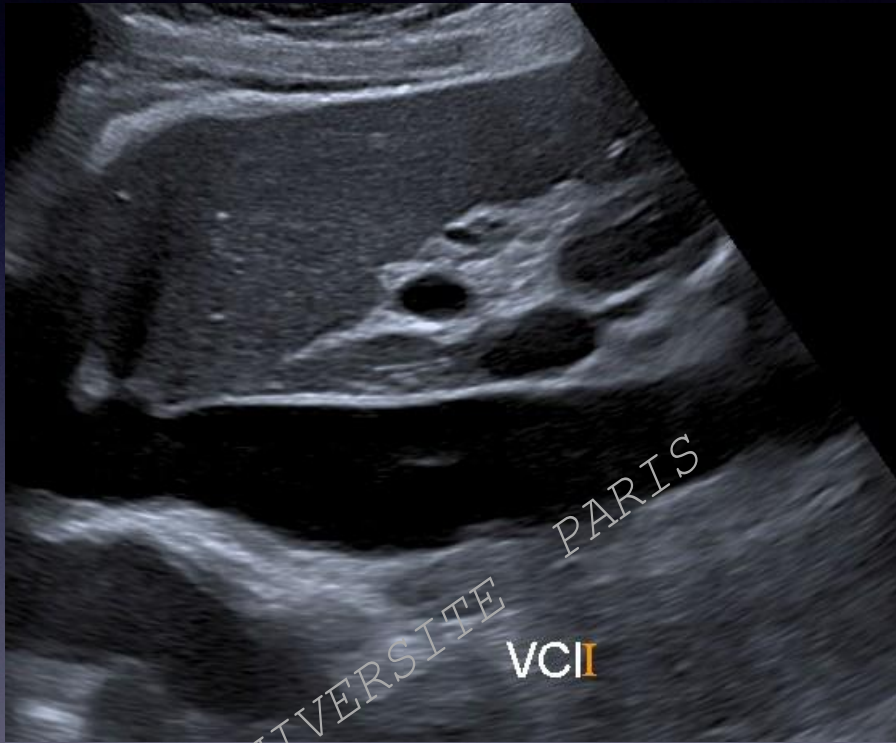
Dissection aortique



VEINE CAVE INFÉRIEURE

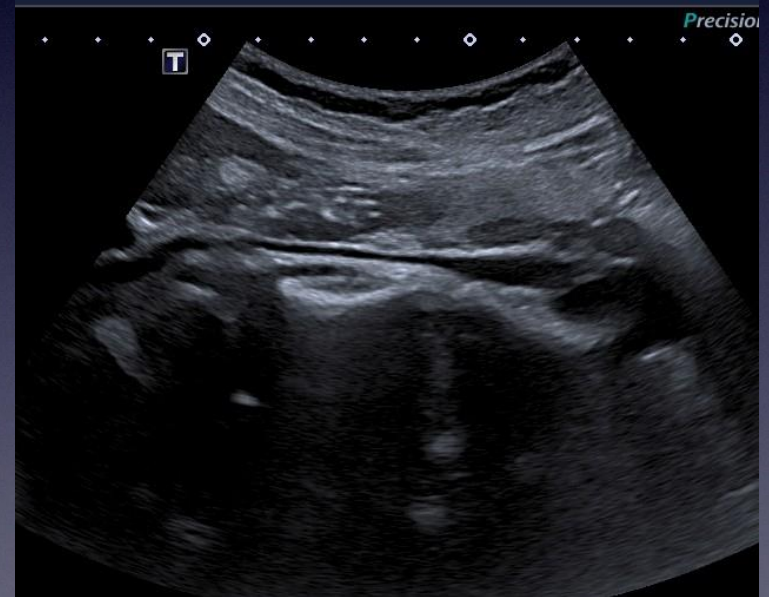
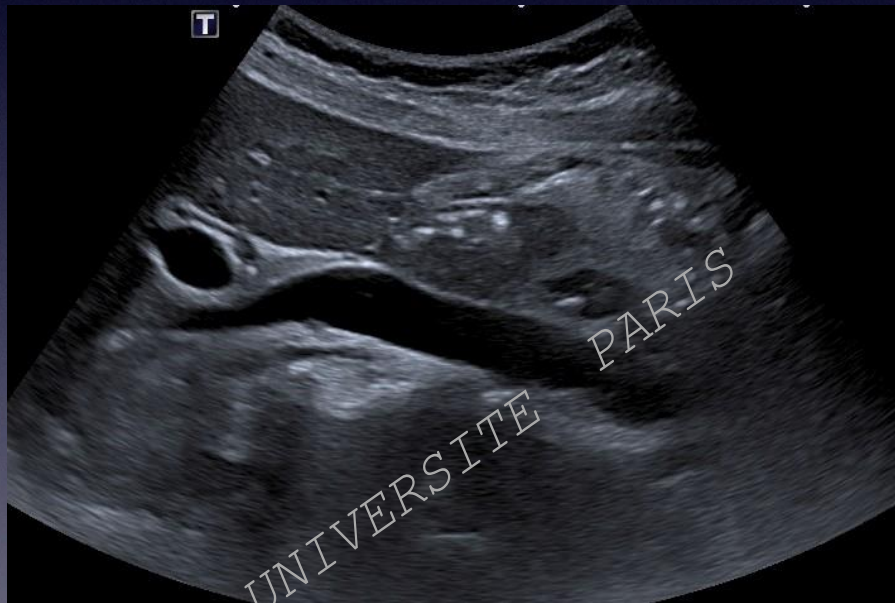
VEINE CAVE INFÉRIEURE

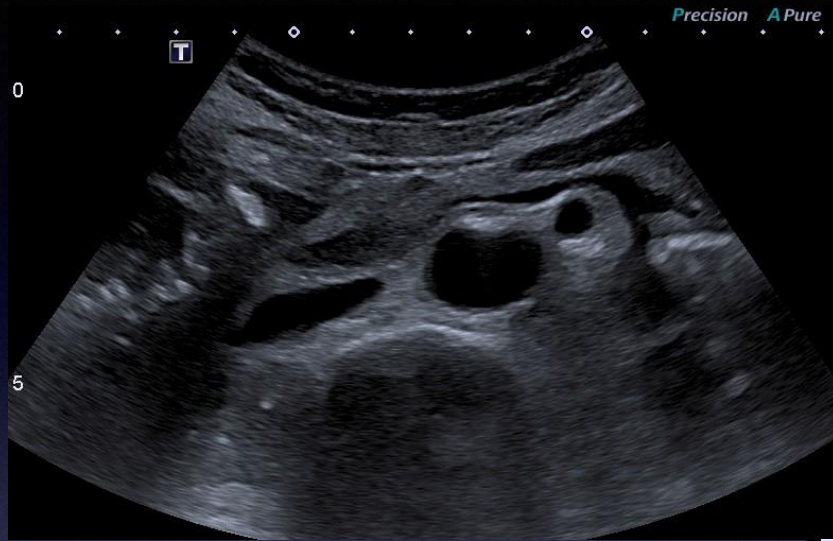

VEINE CAVE INFÉRIEURE

E Danse/P Plaquet

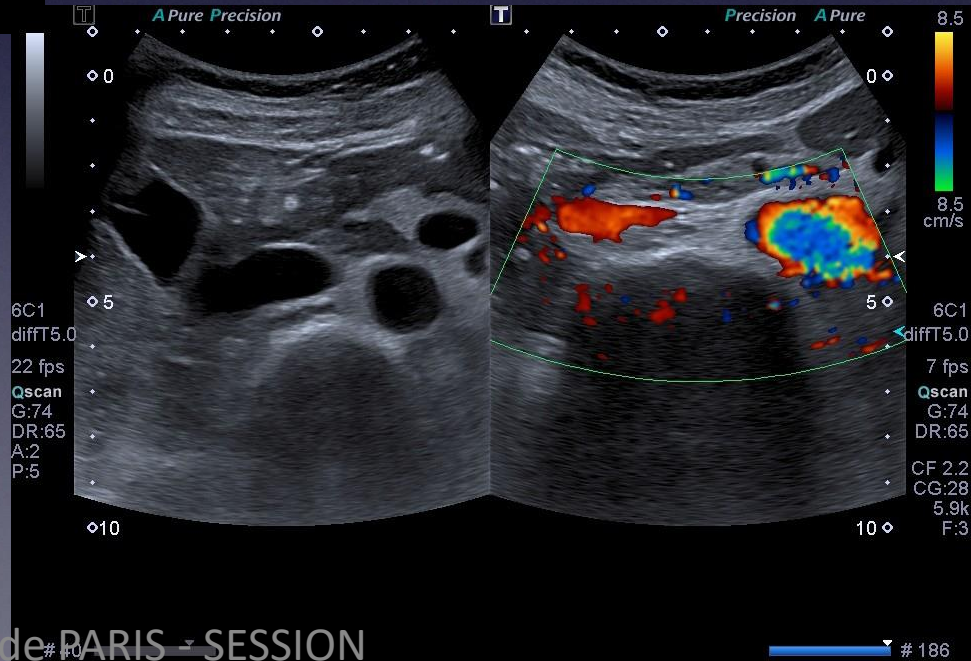


VEINE CAVE INFÉRIEURE



E Danse/P Plaquet

DIU UNIVERSITE PARIS



Normal Inferior Vena Cava: Caliber Changes Observed by Dynamic Ultrasound

Edward Grant^{1,2}
Franco Rendano³
Erkan Sevinc⁴
Jens Gammelgaard¹
Hans Henrick Holm¹
Sven Grönvall¹

A review of the literature revealed conflicting reports on the physiologic variations of the caliber of the normal inferior vena cava as seen by sonography. In this study, 25 normal volunteers were examined using dynamic scanning, and the upper parts of their inferior vena cava were observed for changes during various phases of respiration as well as Valsalva maneuver. Optimum distension and, therefore, optimum visualization of the inferior vena cava were achieved after simple breath holding or at end expiration. Inspiration and Valsalva maneuver decreased the size of this vessel in most subjects, making it difficult to see.

TABLE 2: Normal Inferior Vena Cava: Caliber Changes Observed by Ultrasound

Phase of Respiration	Caliber of Inferior Vena Cava No. Patients (n = 25)		
	Increased	Decreased	No Change
Inspiration	0	25	0
End expiration	25	0	0
Breath held after full inspiration	25	0	0
Valsalva maneuver			
After full inspiration:			
Men (n = 15)	0	15	0
Women (n = 10)	0	5	5
Subtotal	0	20	5
After half inspiration	0	25	0

AJR 135:335-338, August 1980
0361-803X/80/1352-0335 \$00.00
© American Roentgen Ray Society



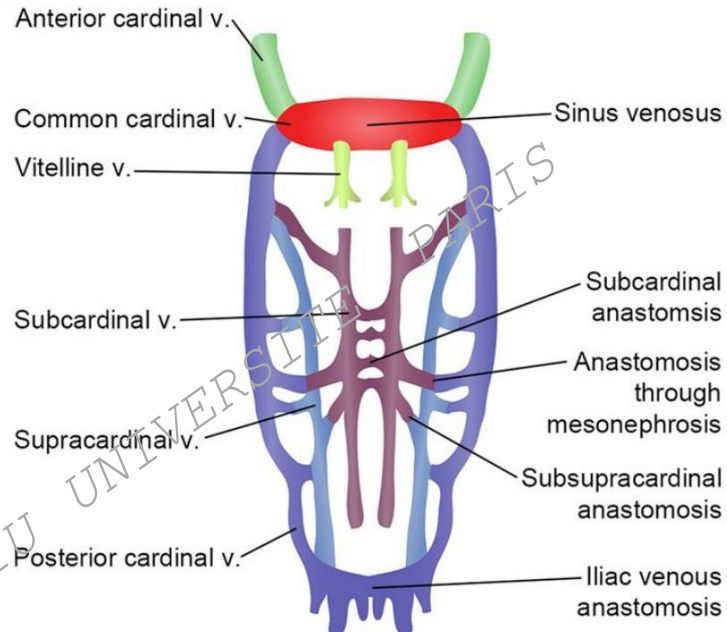
The inferior vena cava: a pictorial review of embryology, anatomy, pathology, and interventions

David S. Shin¹ · Claire K. Sandstrom¹ · Christopher R. Ingraham¹ · Eric J. Monroe^{1,2} · Guy E. Johnson¹

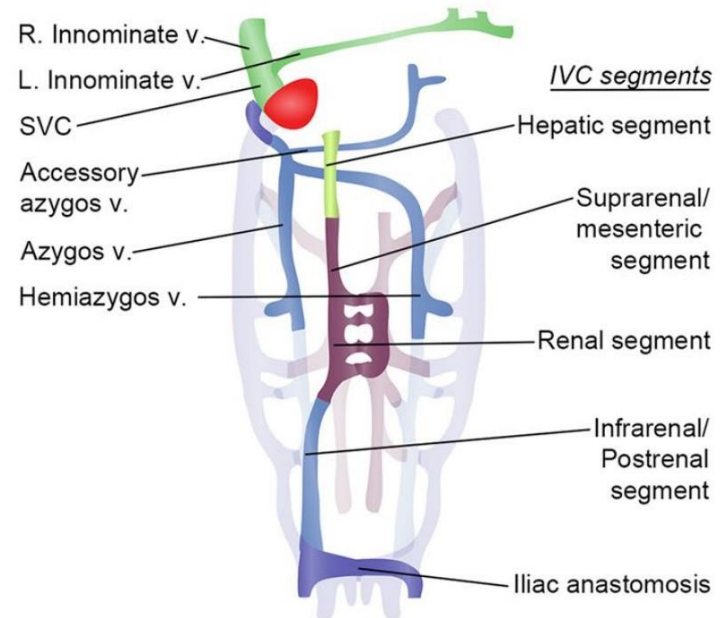
Published online: 1 April 2019
© Springer Science+Business Media, LLC, part of Springer Nature 2019

E. Danse/P. Plaquet

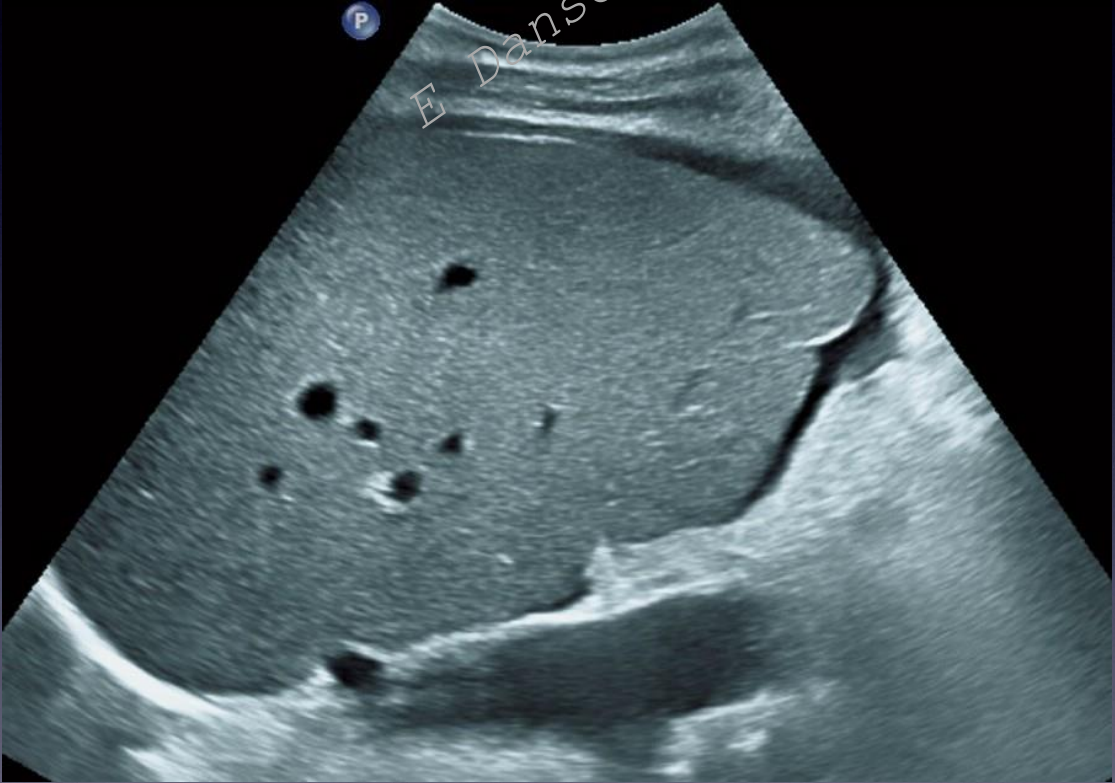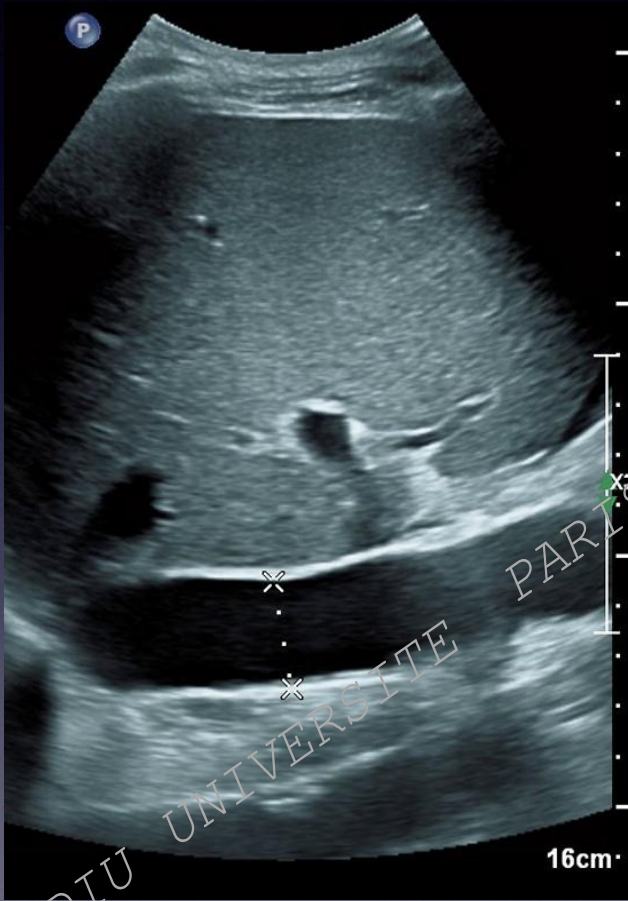
A



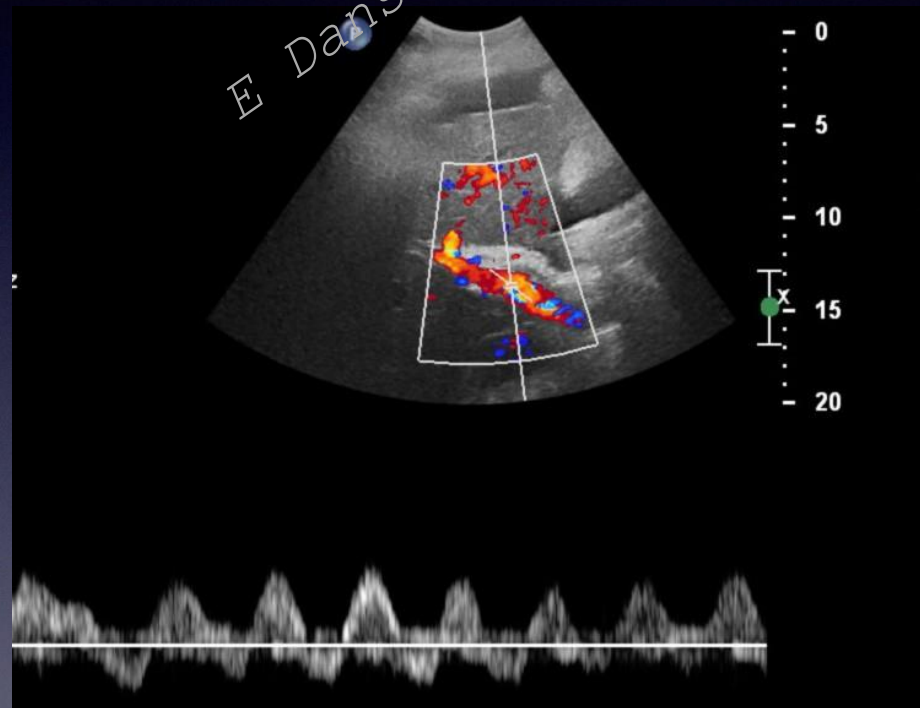
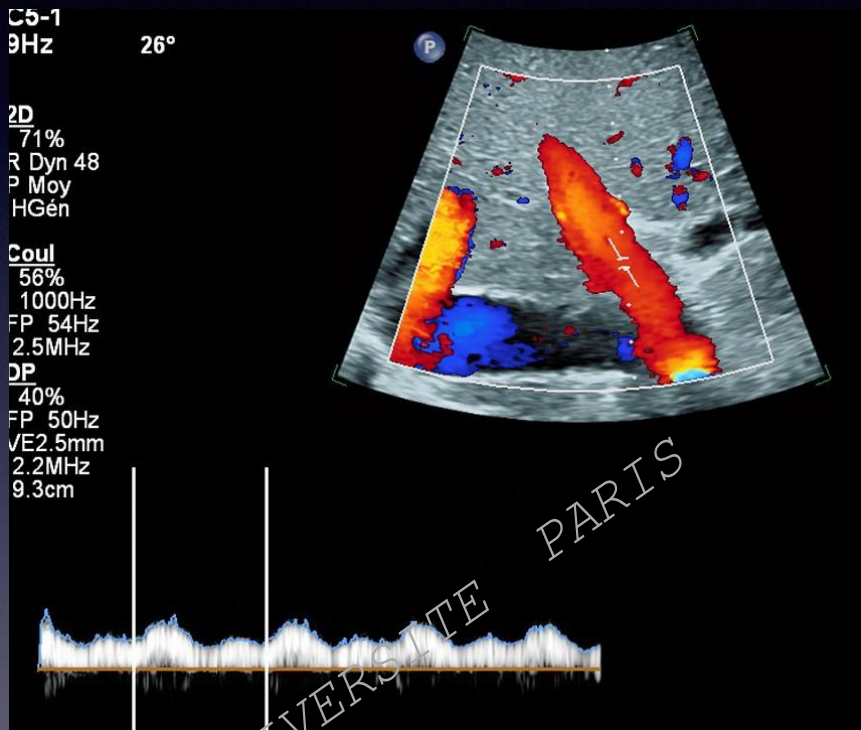
B



Foie cardiaque



Foie cardiaque

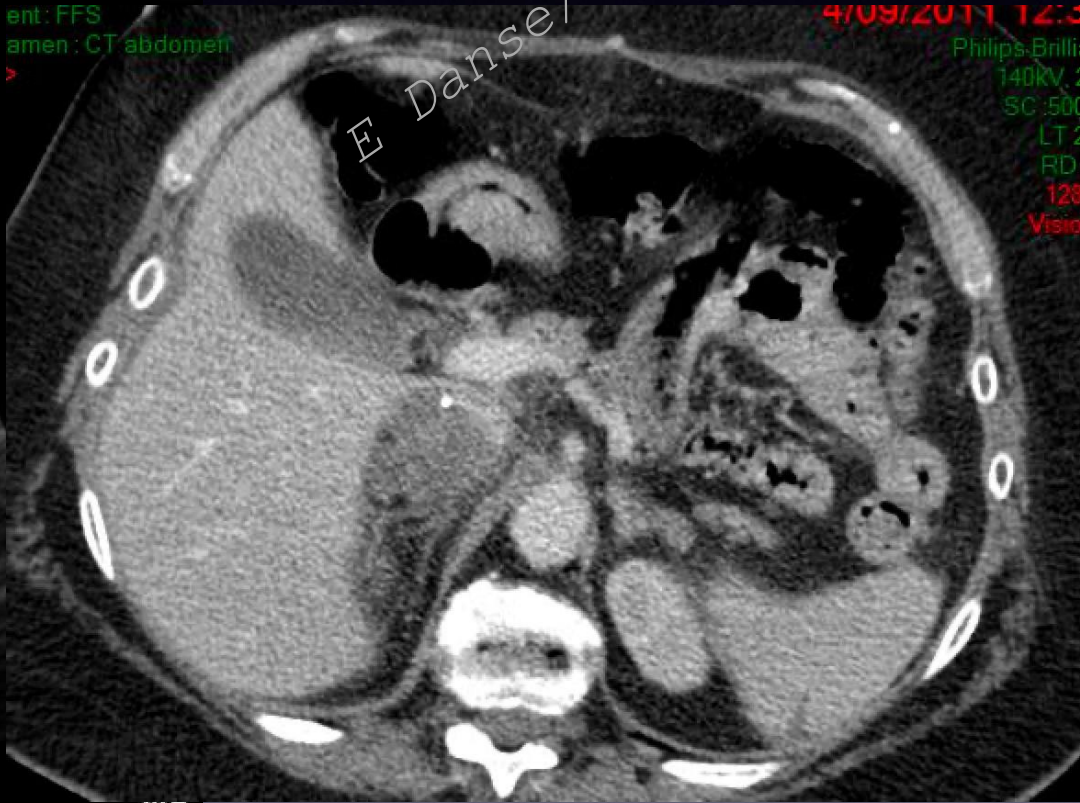
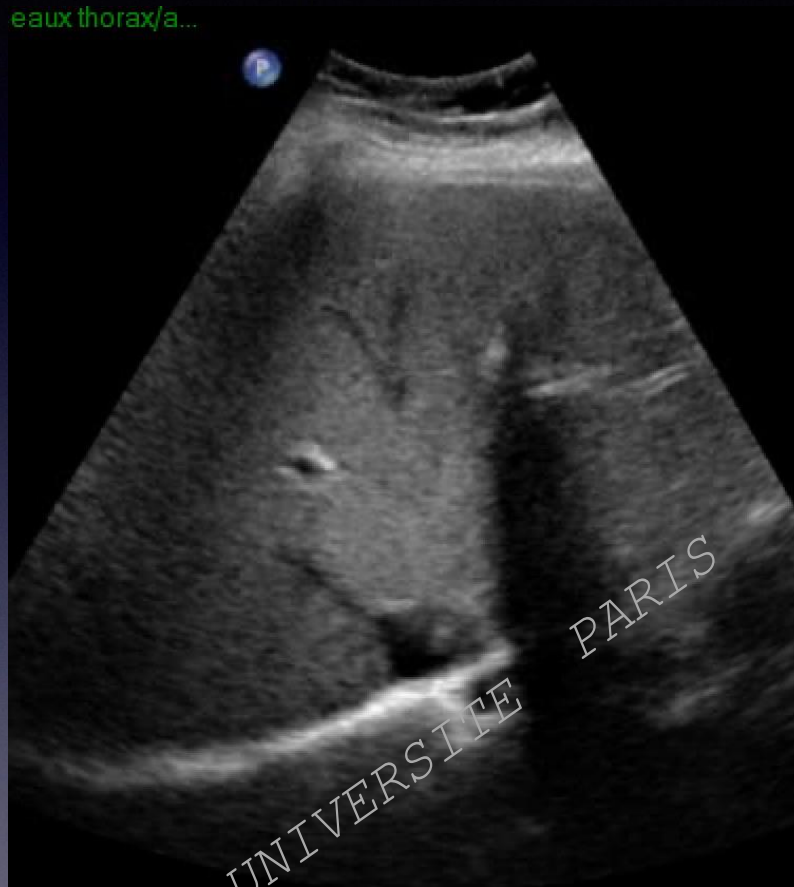

eaux thorax/a...

8

ent: FFS
amen: CT abdomen

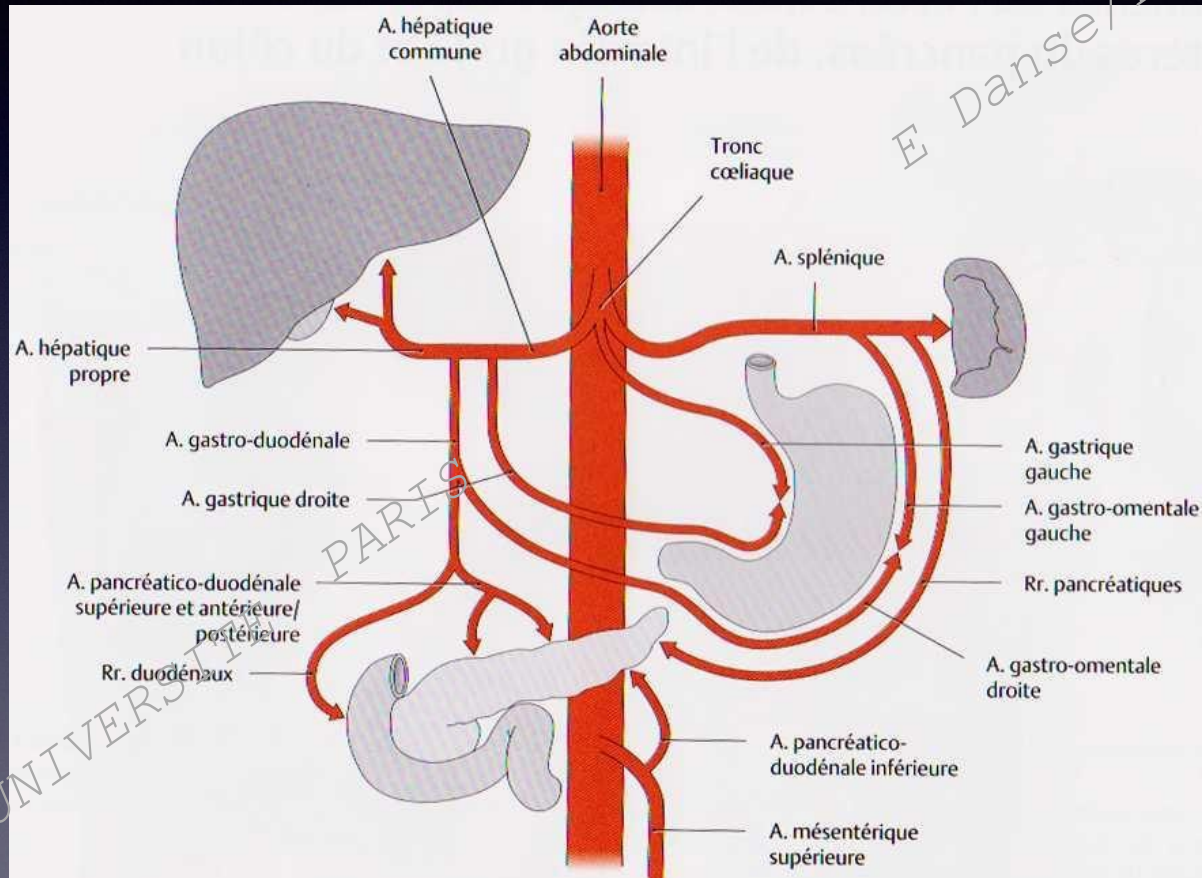
4/09/2011 12:3
Philips-Brilli
140kV, 2
SC: 500
LT 2
RD
128
Visio



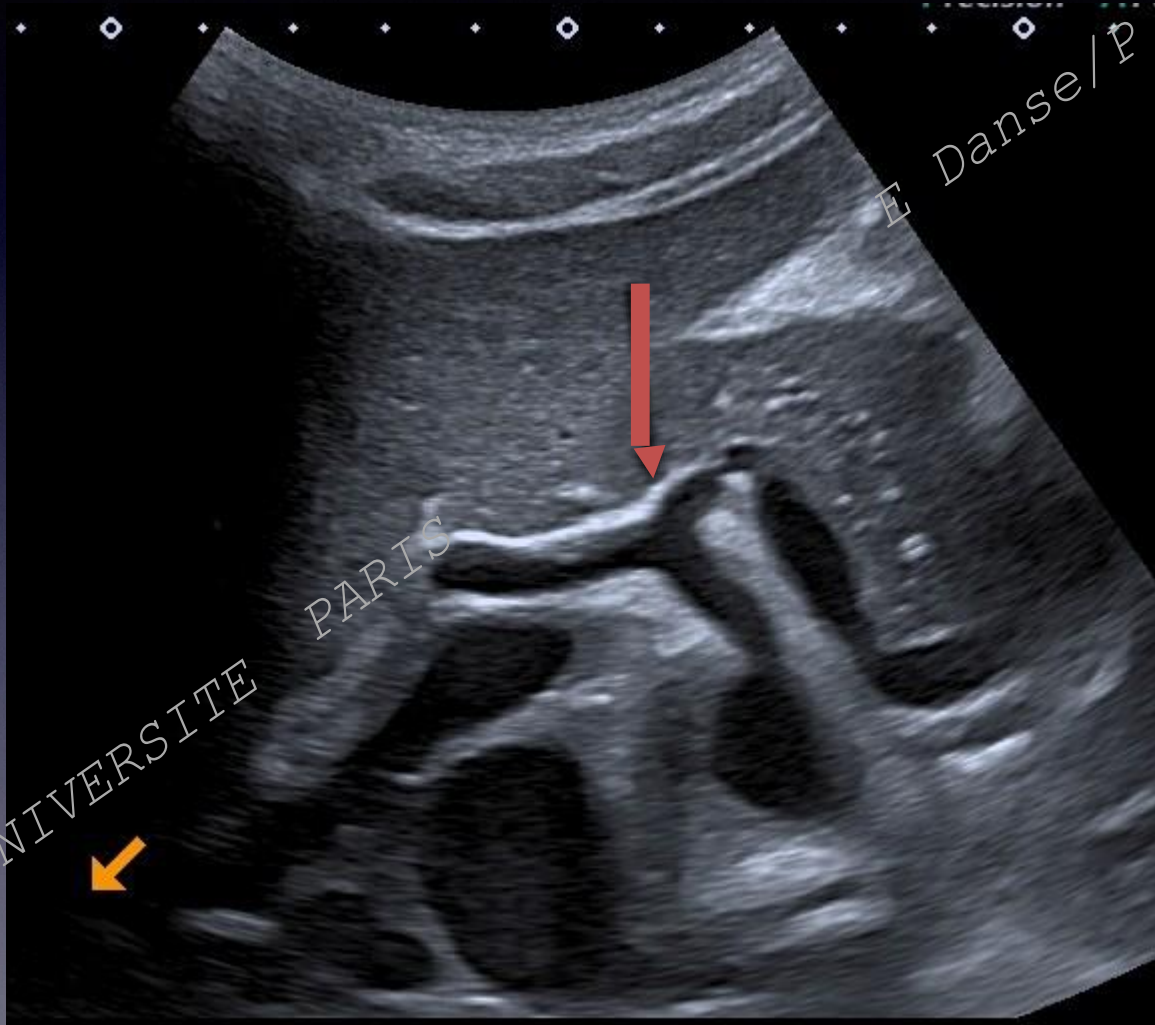DIU UNIVERSITE PARIS

E Danse/P Plaquet

Echo-anatomie des gros vaisseaux abdominaux



Tronc coeliaque

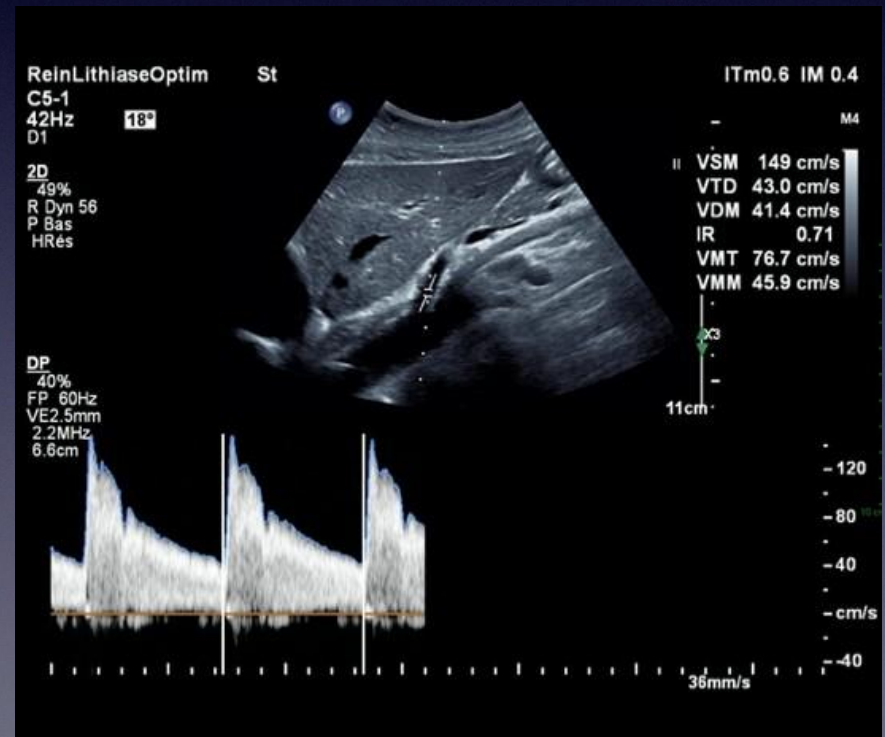

DIU UNIVERSITE PARIS

Tronc coeliaque

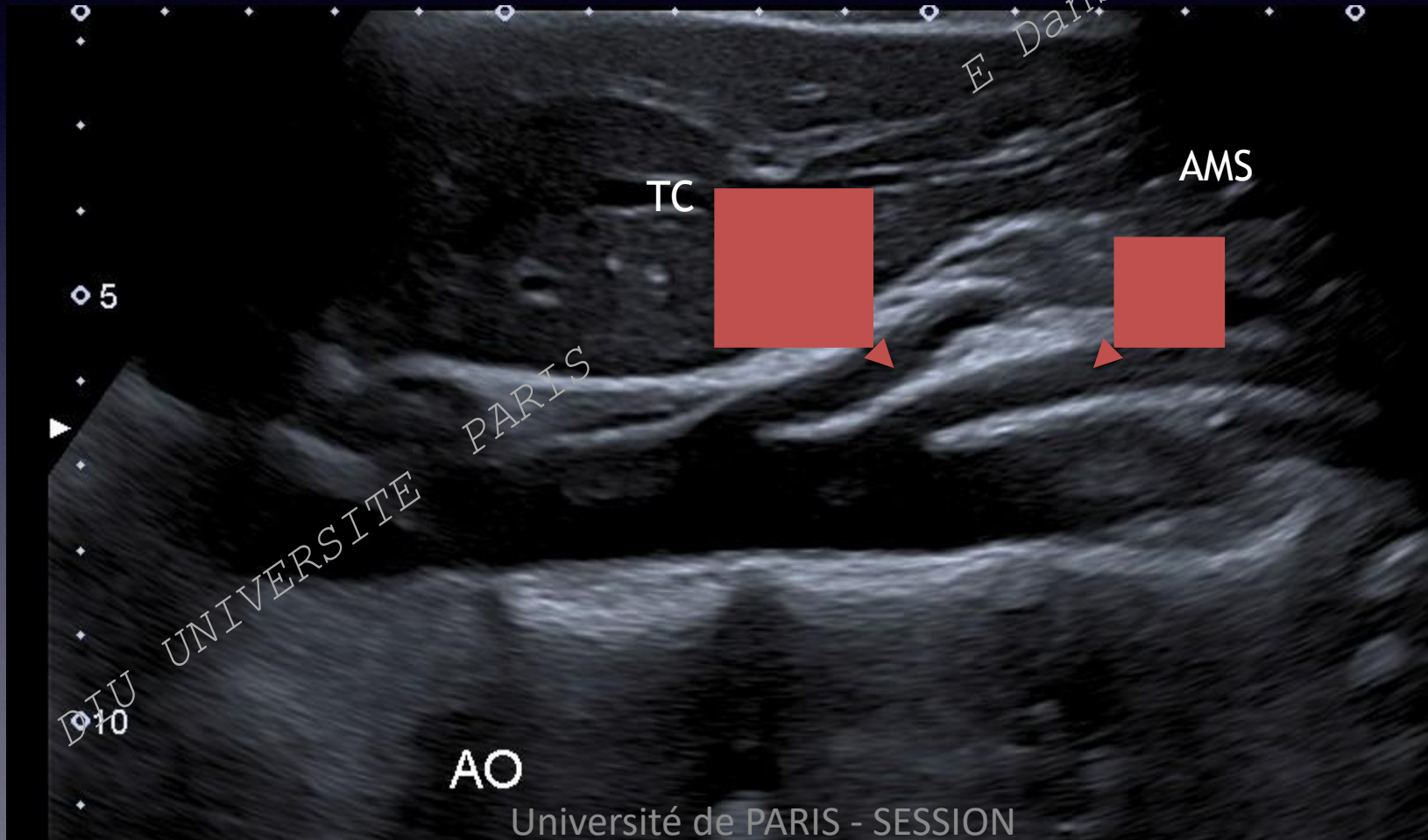
E Danse/P Plaquet

Diamètre normal : < 6 mm
Pic systolique 100 - 200 cm/s
IR 0,56 - 0,80

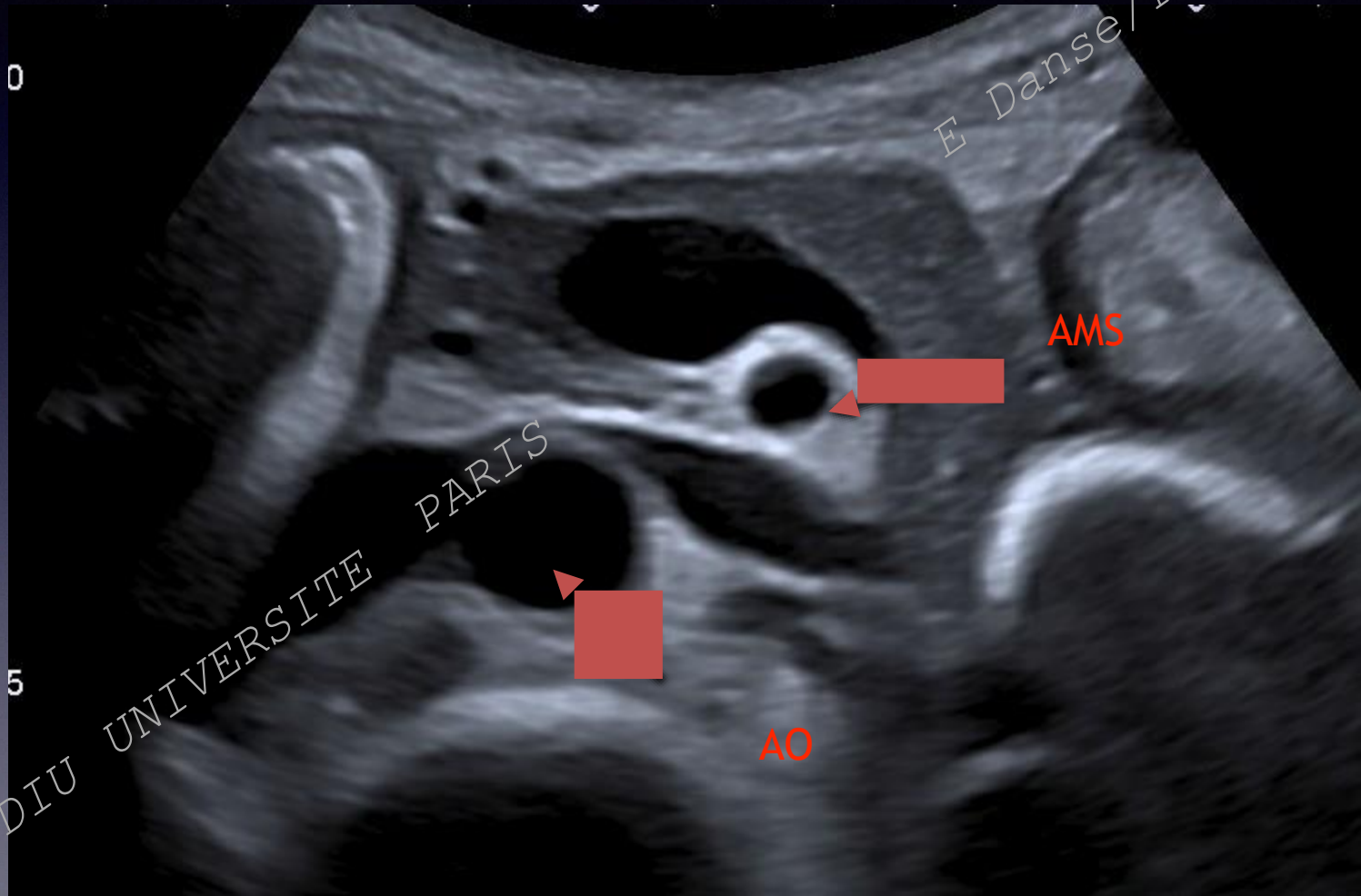


Tronc coeliaque

Artère mésentérique supérieure

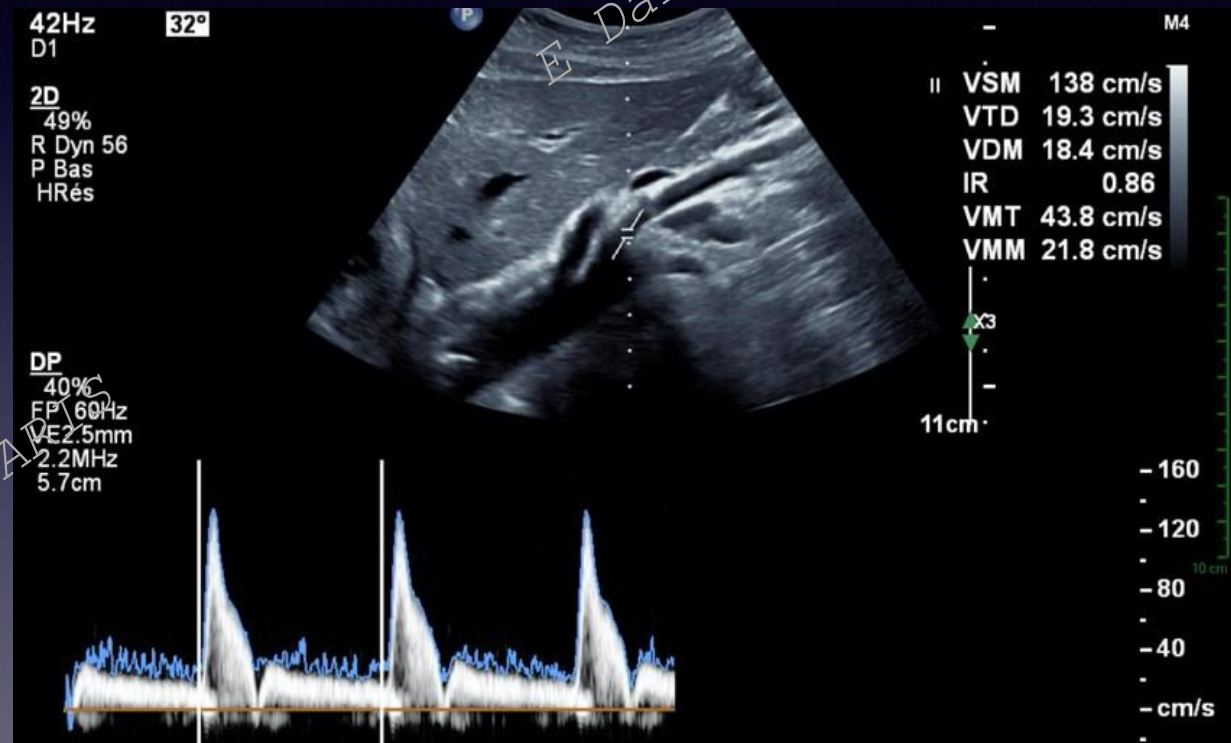


Artère mésentérique supérieure

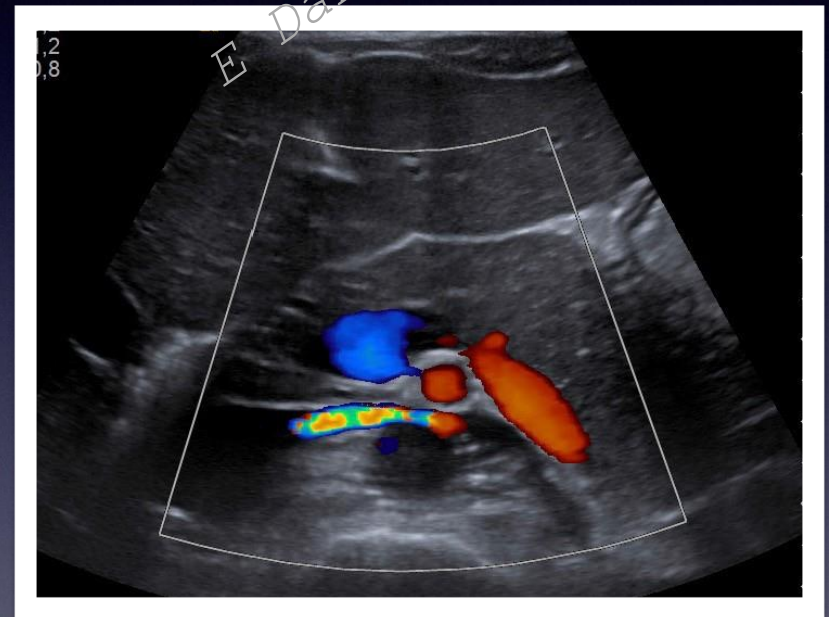
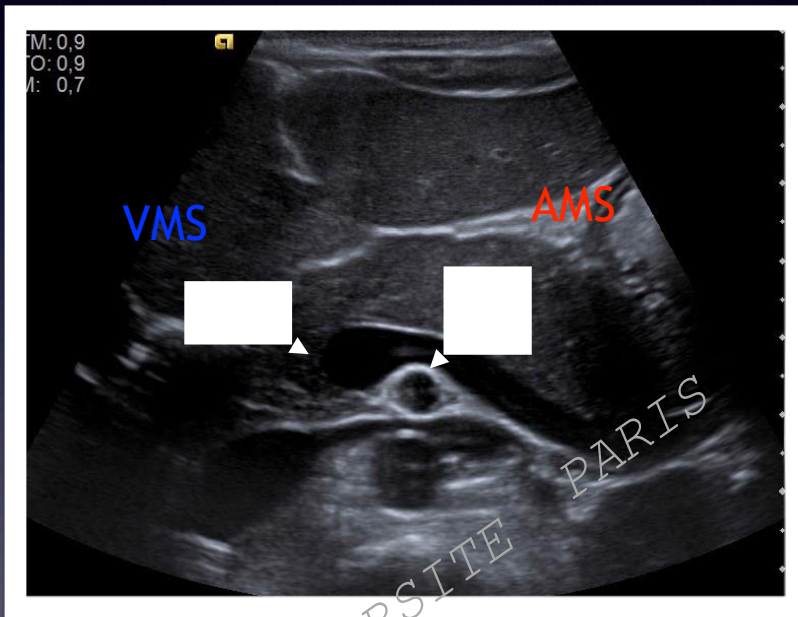


Artère mésentérique supérieure

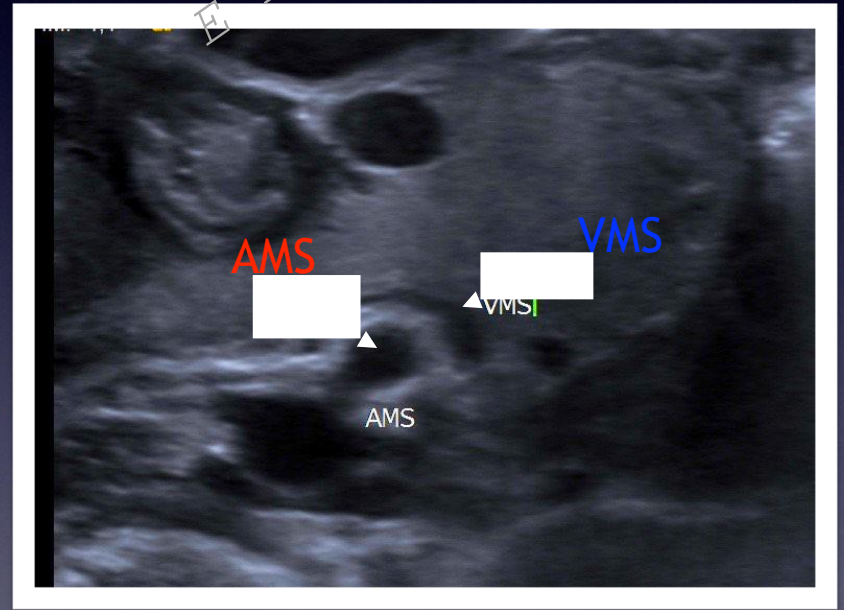
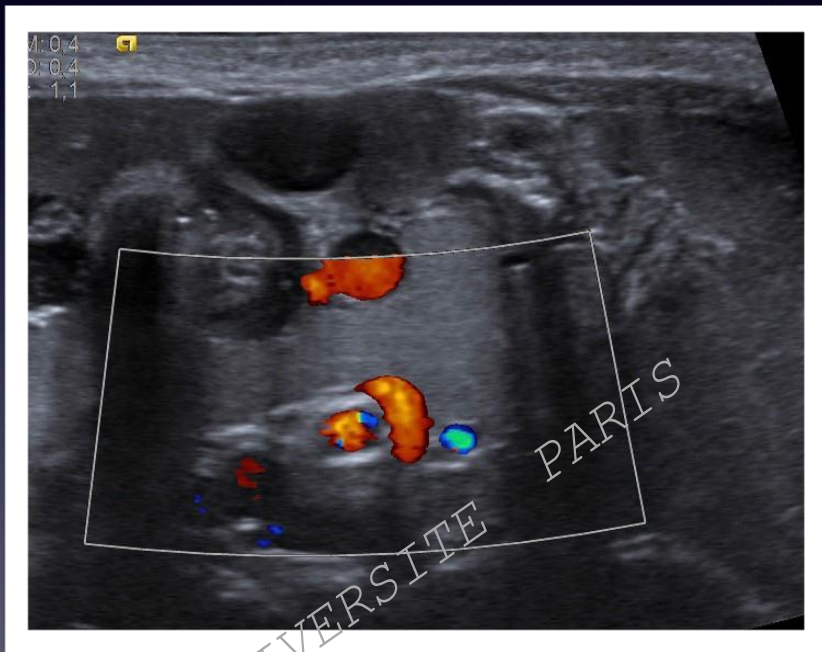
10 - 25 mm sous
le TC
Diamètre < 6mm
Pic syst 125-180
cm/s



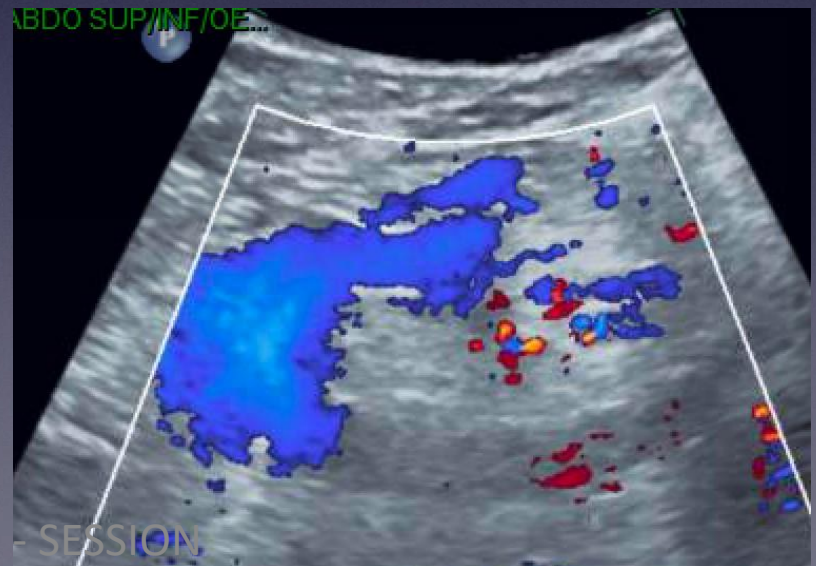
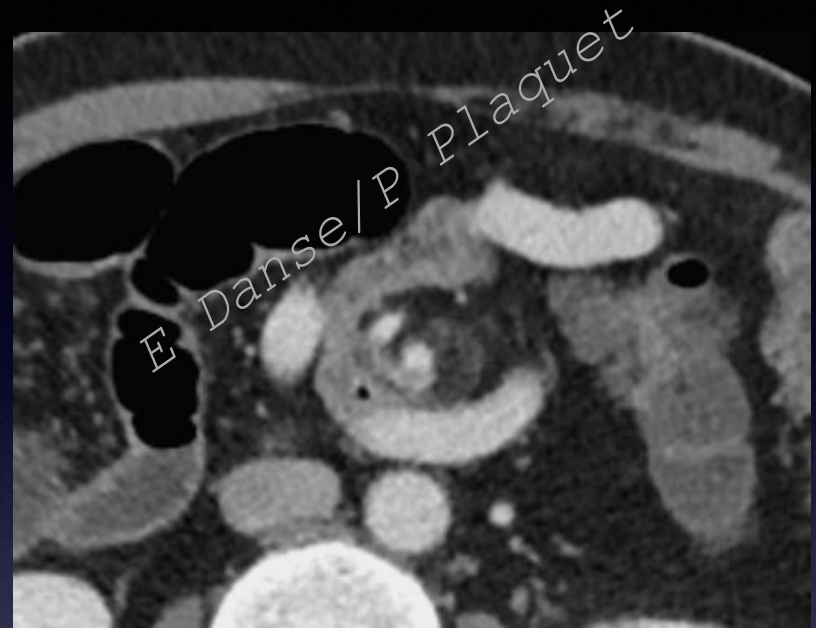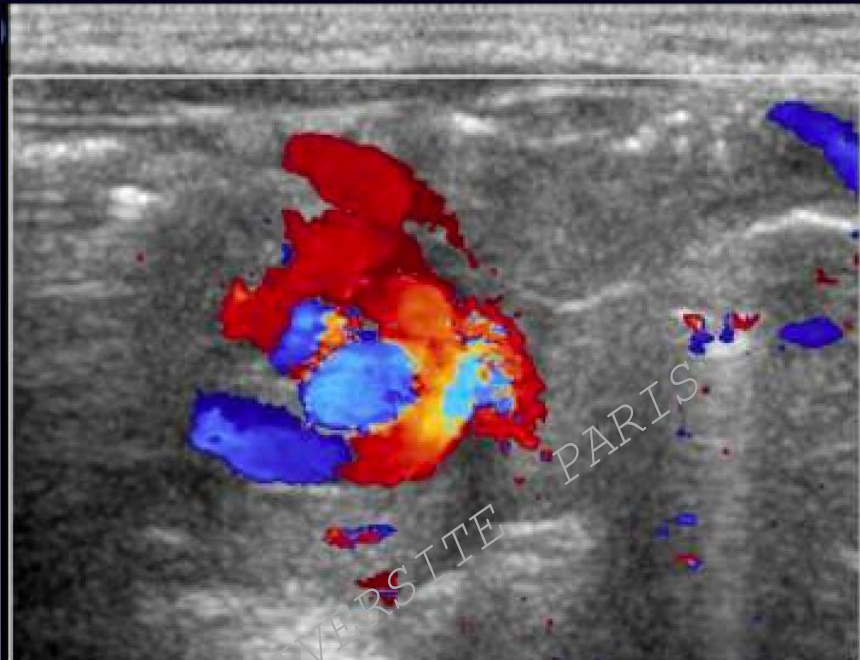
Artère et veine mésentériques supérieures



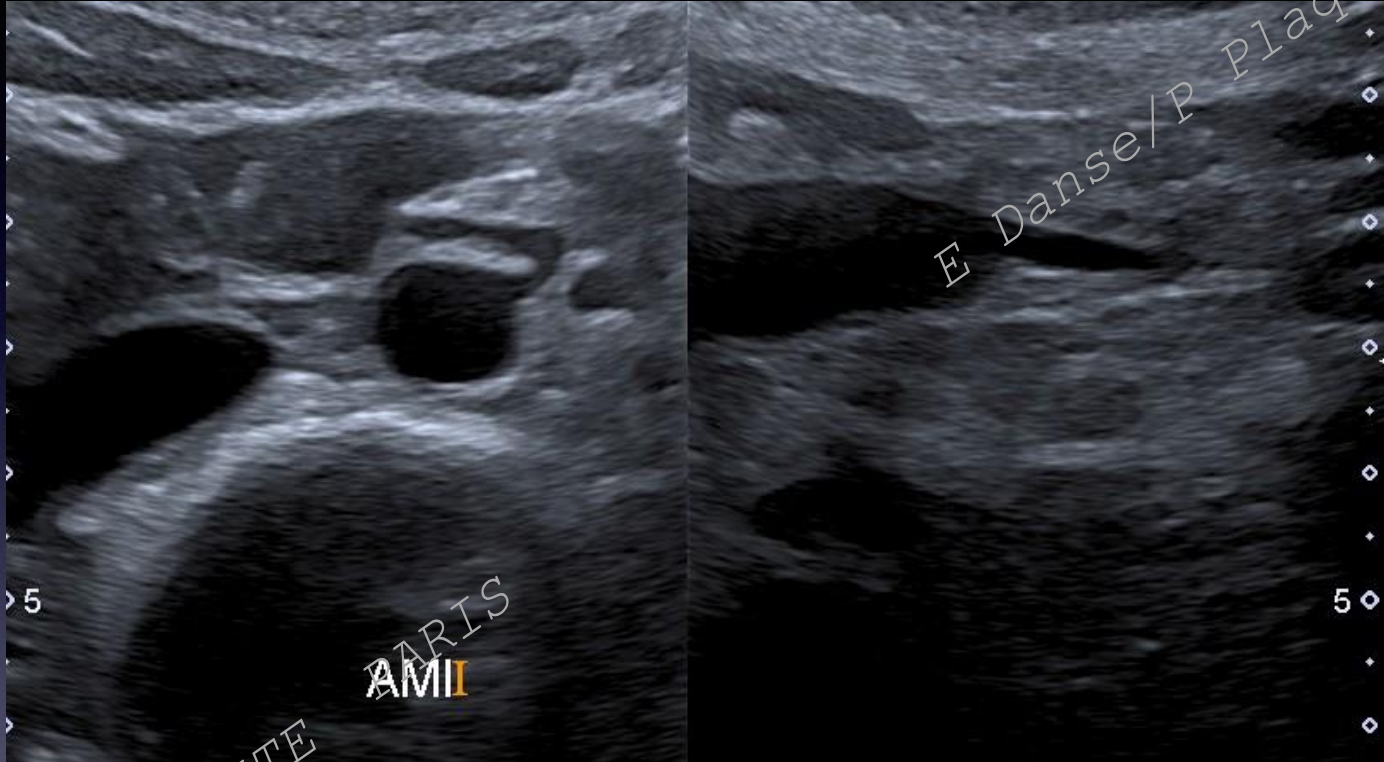
Artère et veine mésentériques supérieures



Volvulus sur malrotation => enfant ...=> adulte



Artère mésentérique inférieure

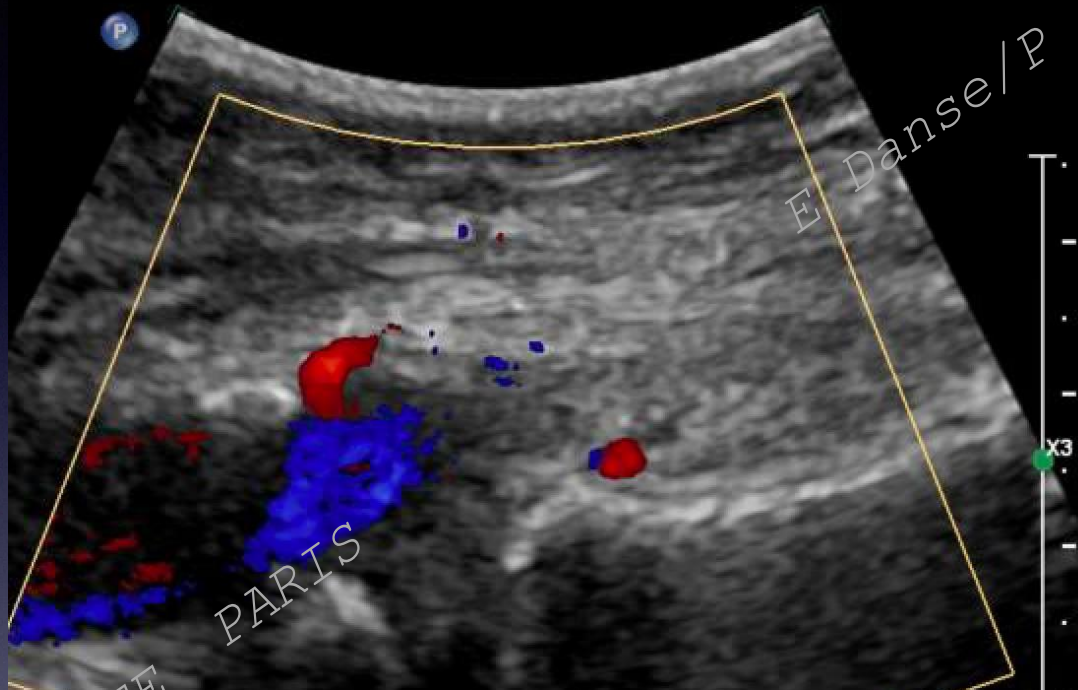


3 à 6 cm de la bifurcation

Diamètre 3 à 6 mm

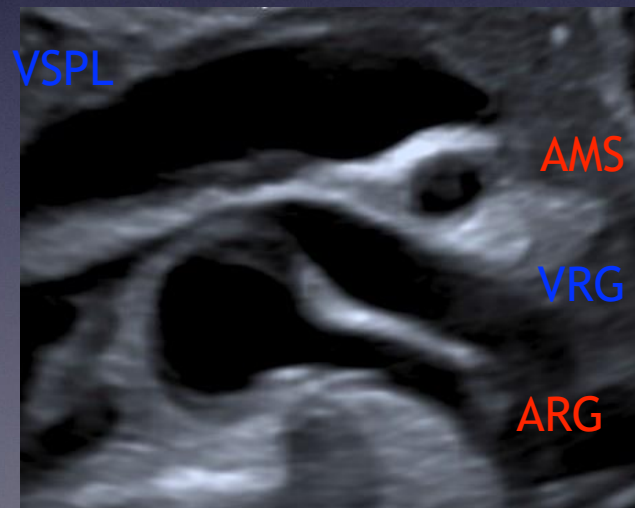
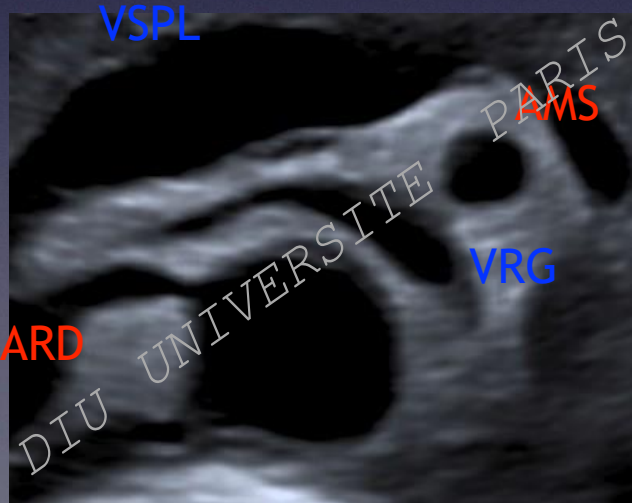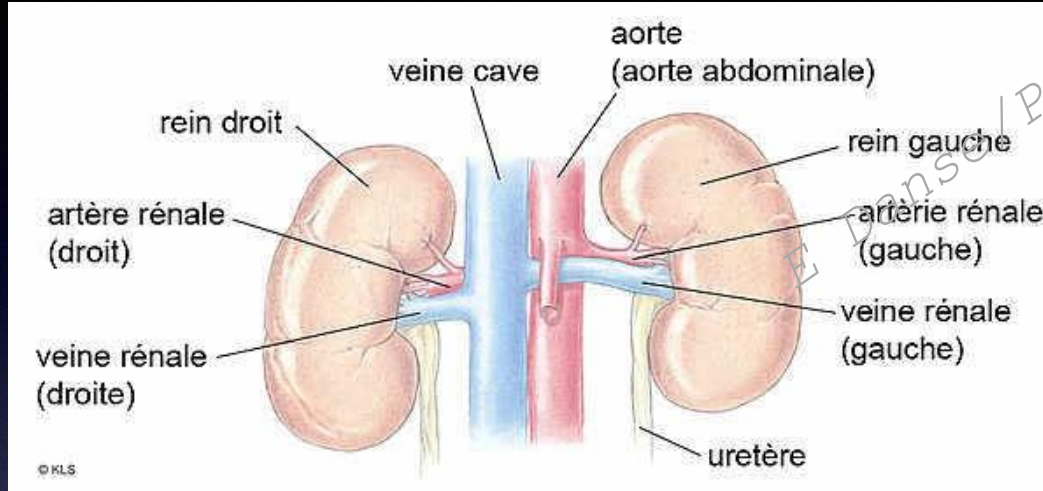
Flux triphasique pic syst < 120 cm/s

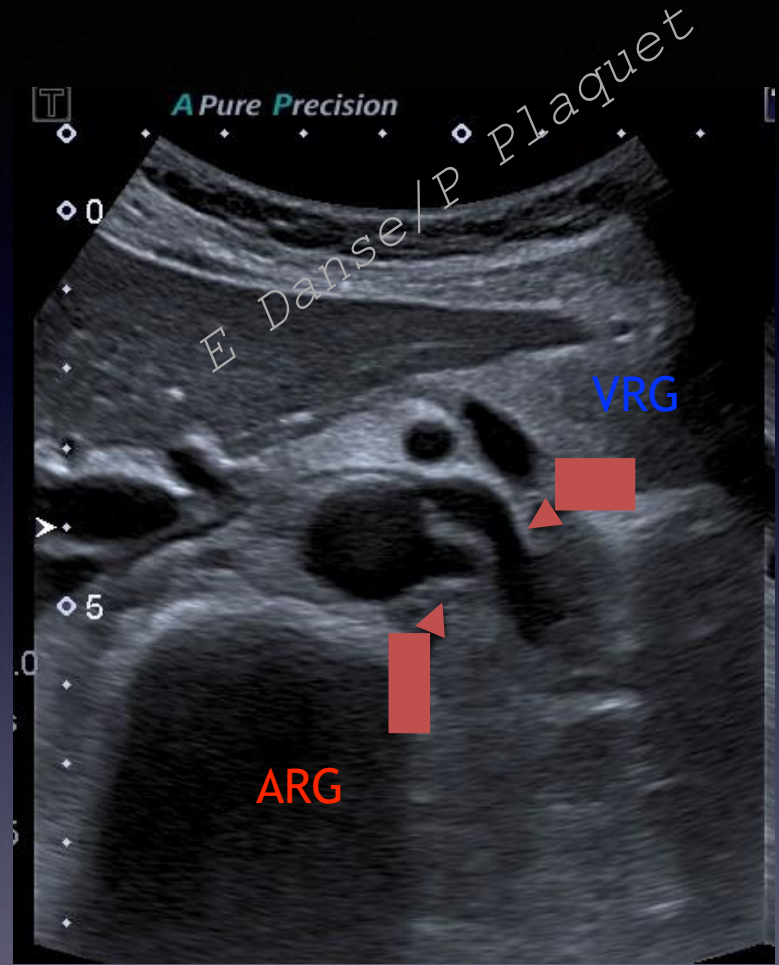
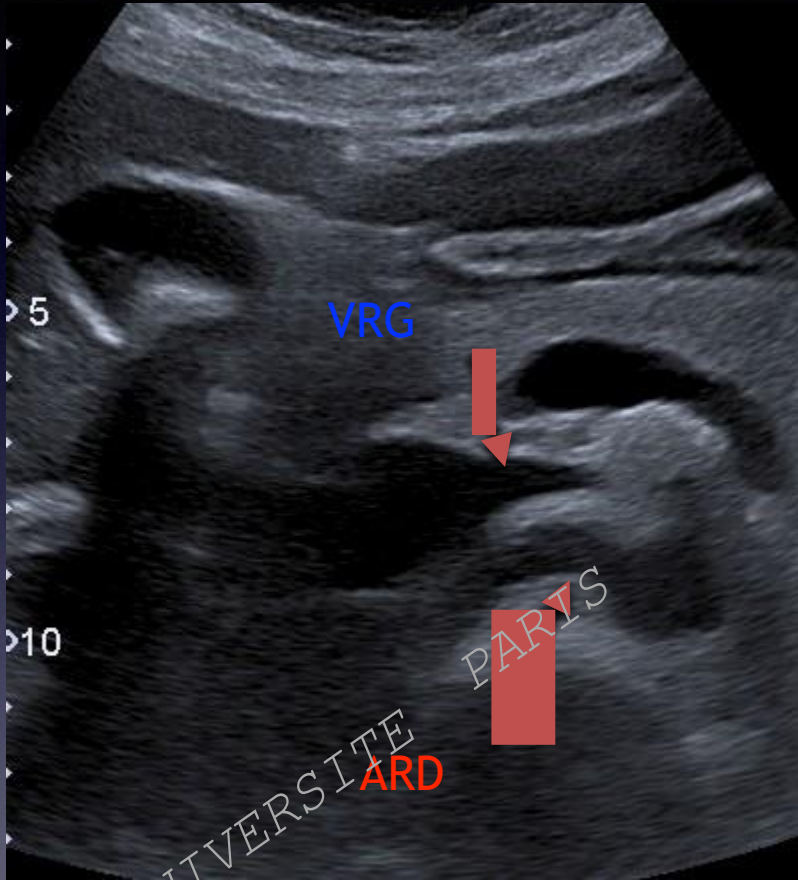
Artère mésentérique inférieure



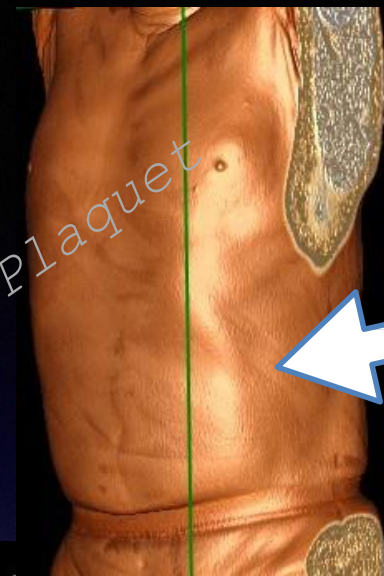
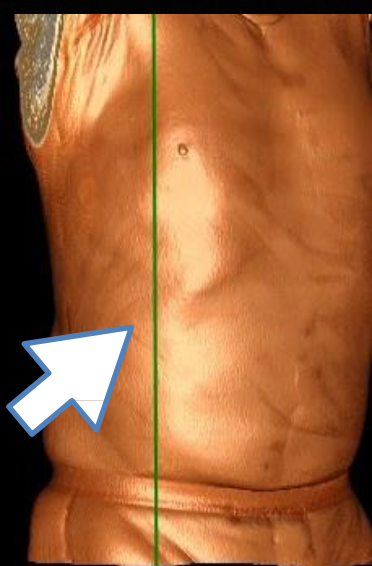3 à 6 cm de la bifurcation
Diamètre 3 à 6 mm
Flux triphasique pic syst < 120 cm/s

Vaisseaux rénaux

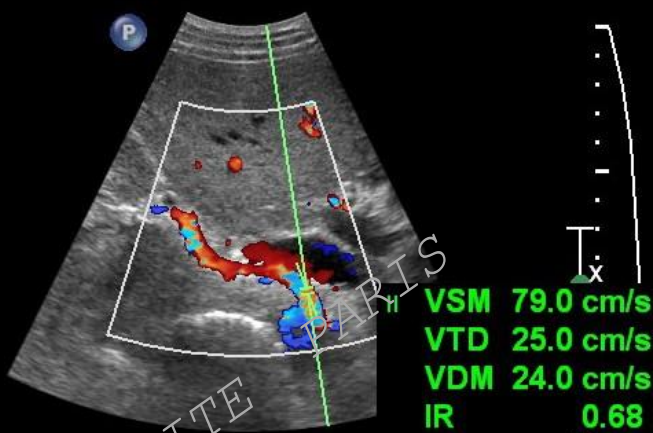




Artères rénales

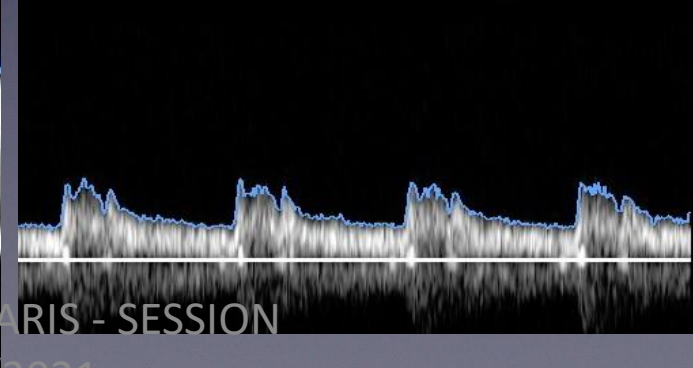
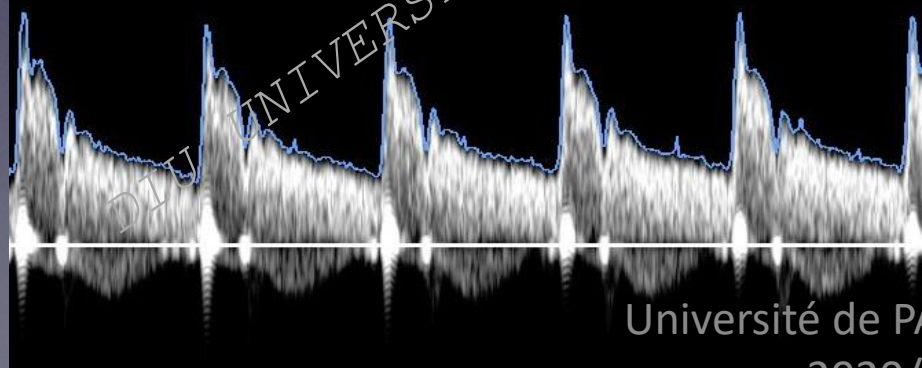
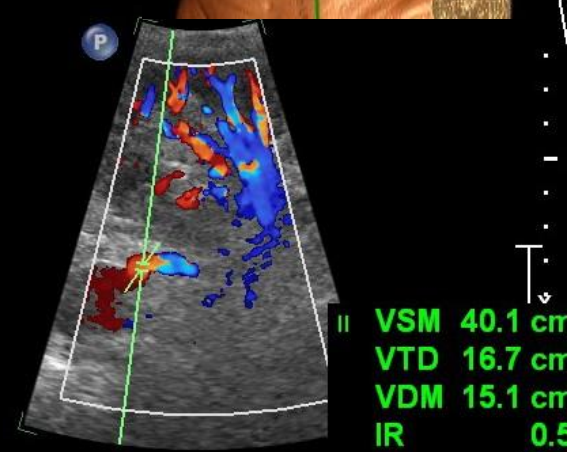

E Danse/P Plaquet

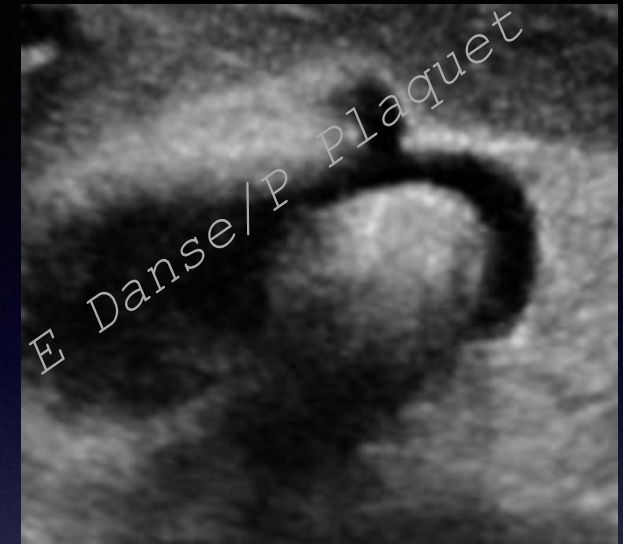

1474 20°

%
5
oy
||
%
0Hz
62Hz

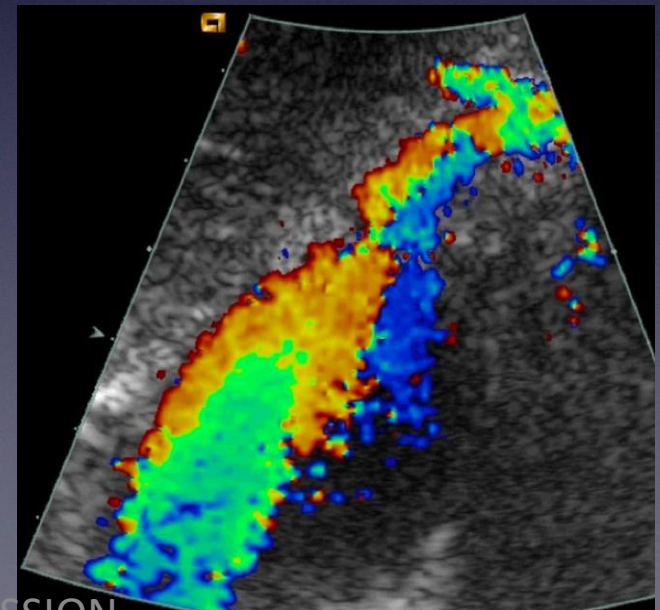


Tronc coeliaque



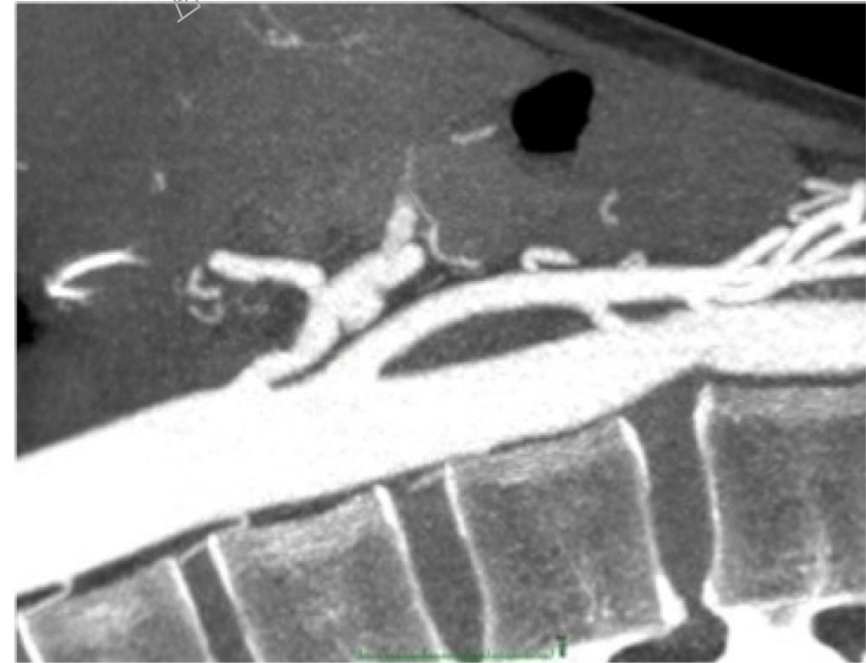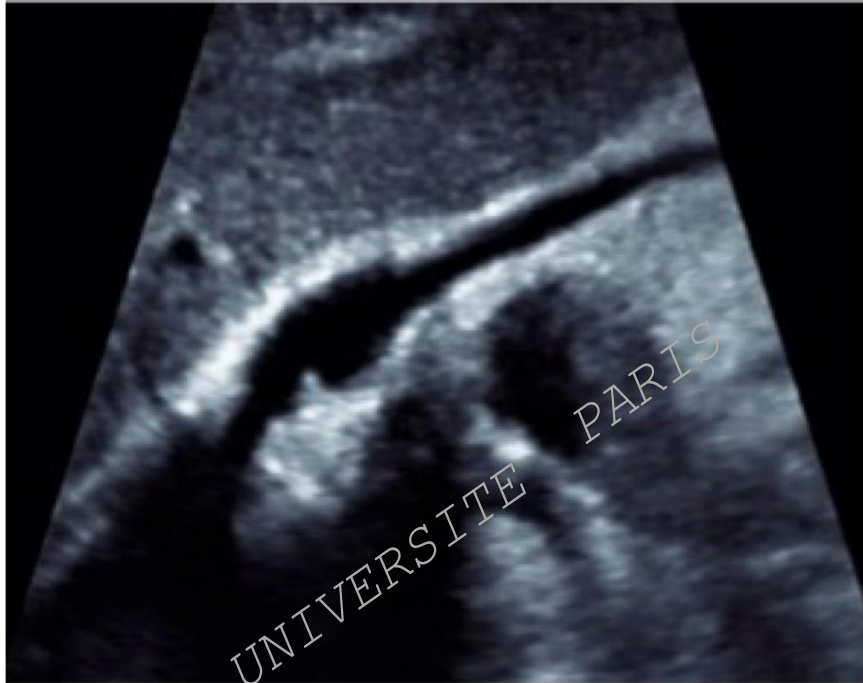Réseau interconnecté ,
collatéralité
Calibre inhabituel perméabilité
, anévrisme , thrombose

Tronc coeliaque :
dissection

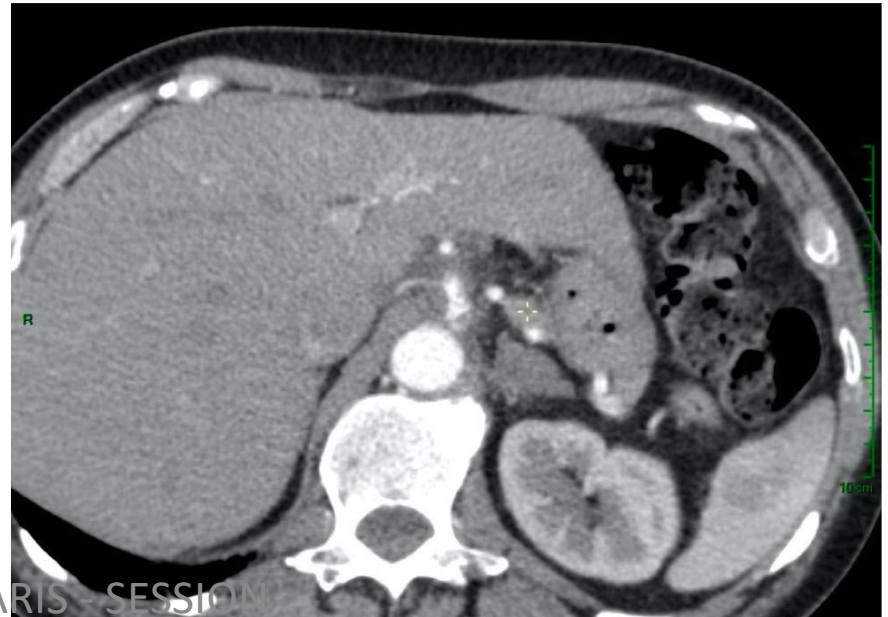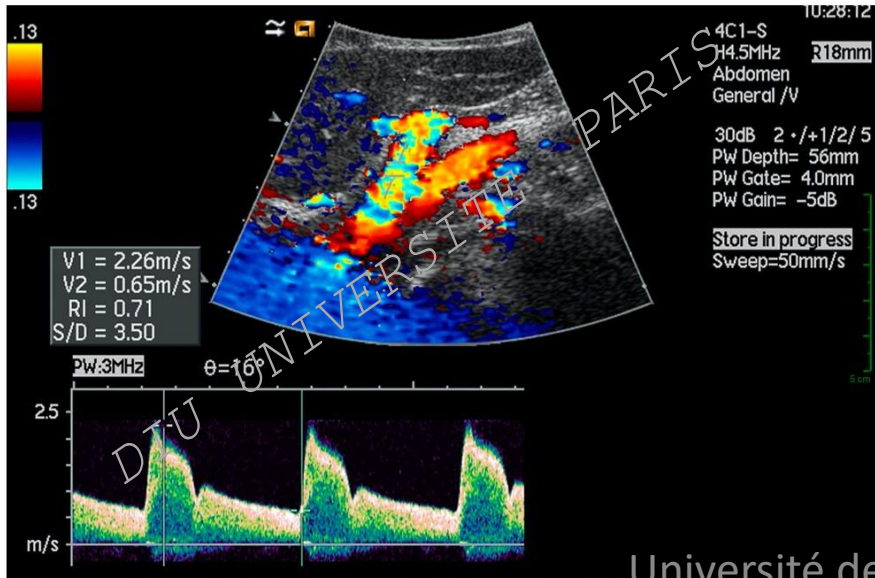
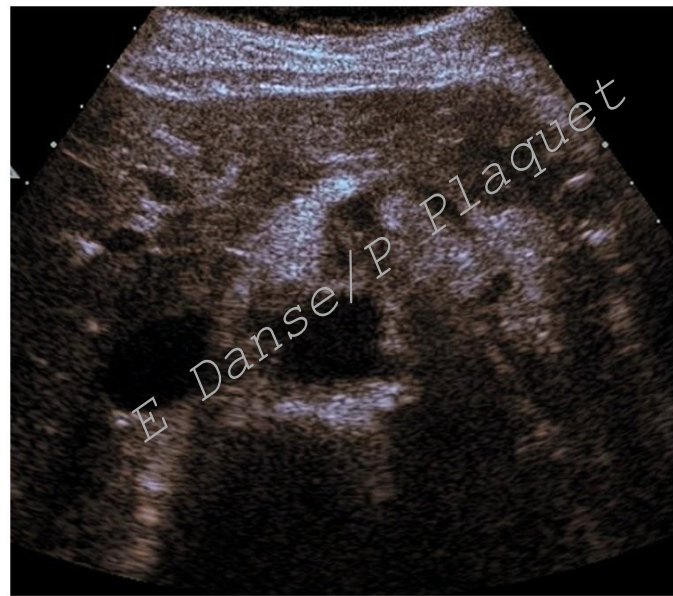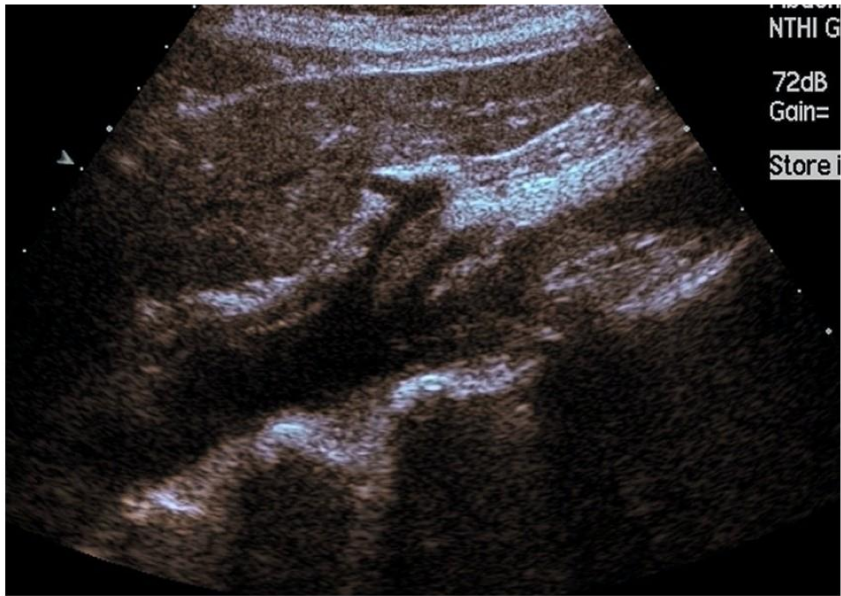


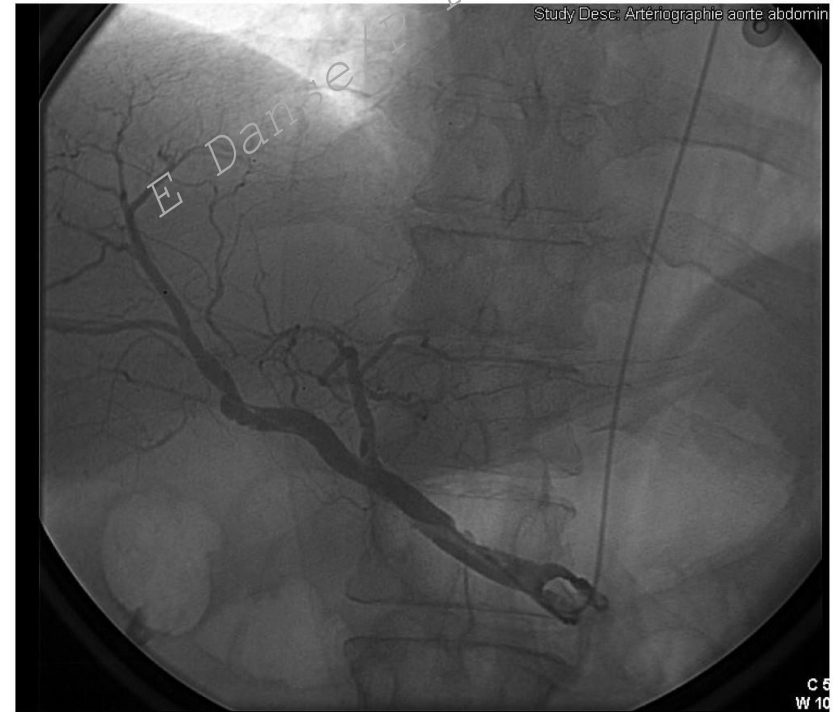
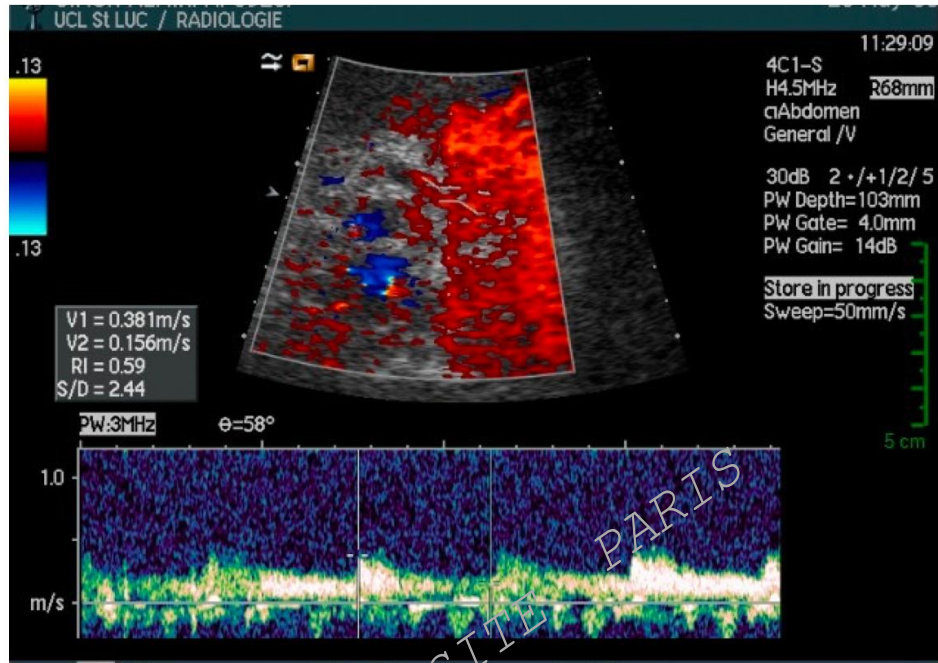
Tronc coeliaque : dissection

E. Danse/P. Plaquet



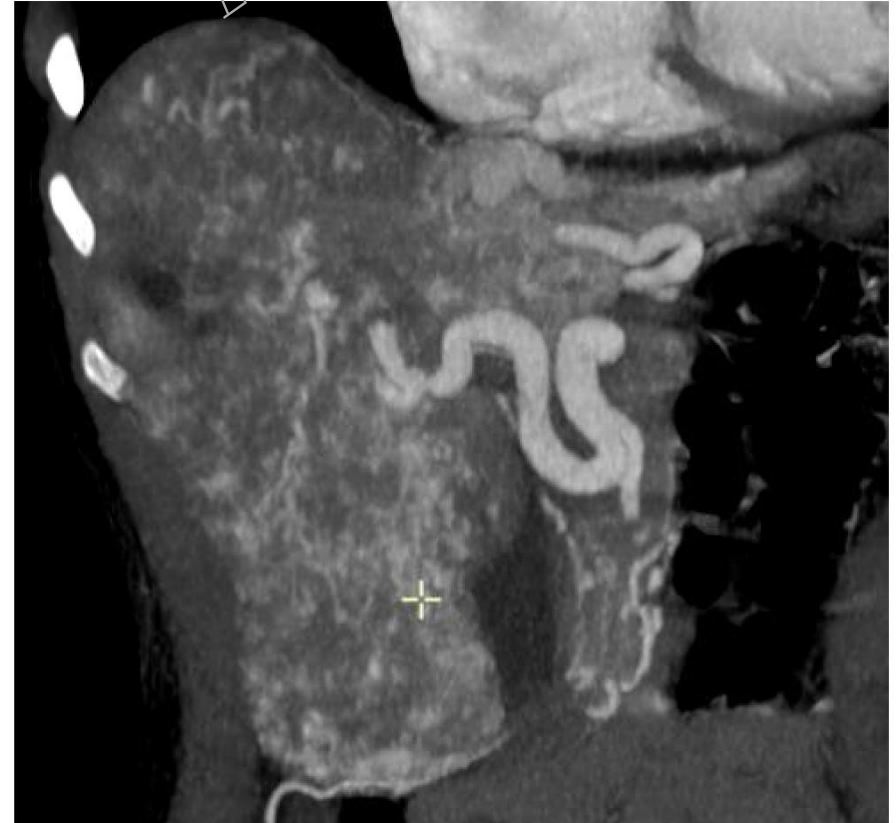
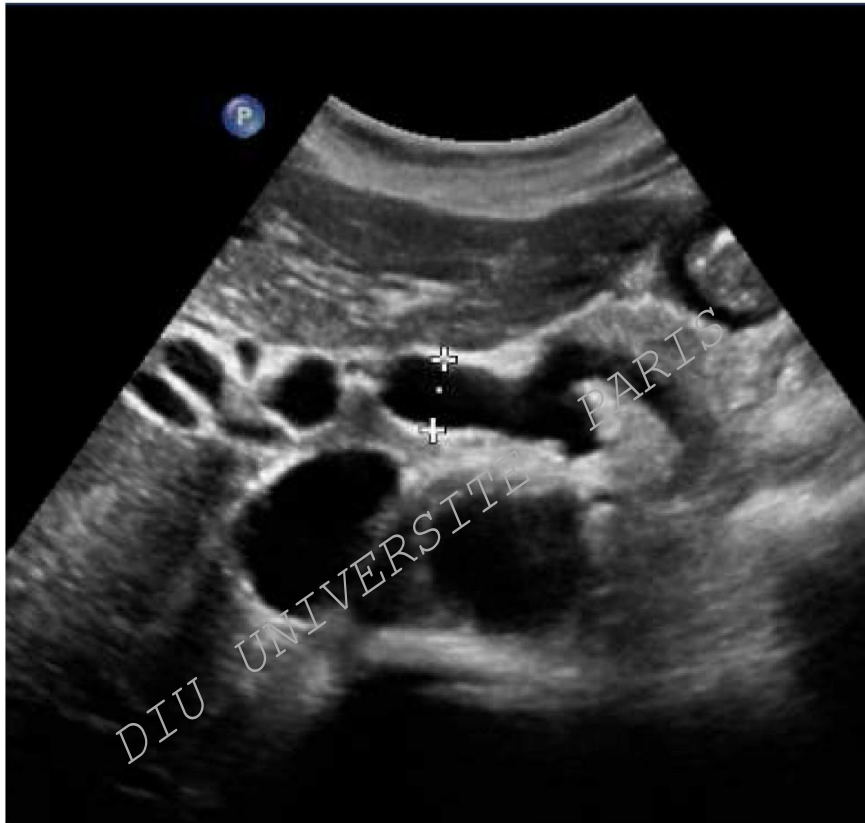DIU UNIVERSITE PARIS





Osler Rendu

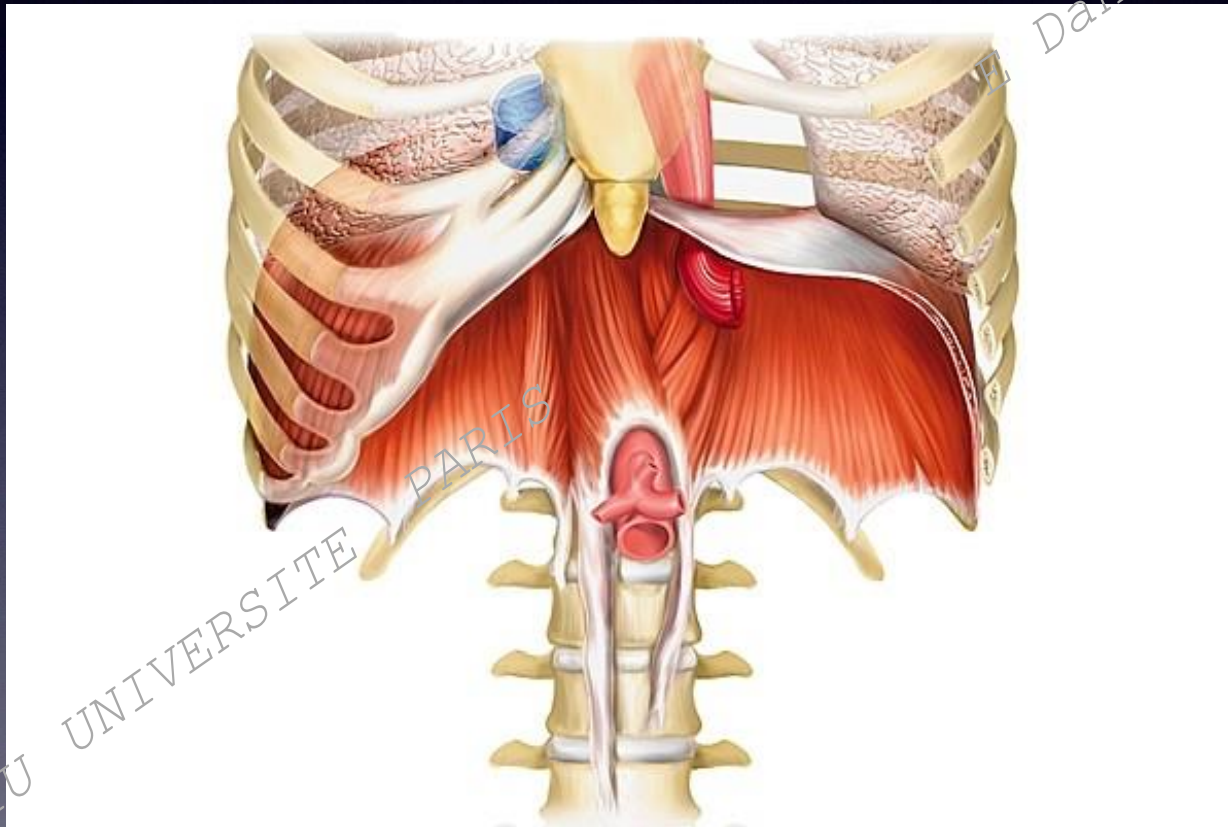
E. Danse/P. Plaquet



Ligament arqué

Hiatus fibreux diaphragmatique
inextensible

tronc coeliaque trop haut



Ligament arqué

E Danse/P Plaquet

Compression stenose
hémodynamiquement
significative

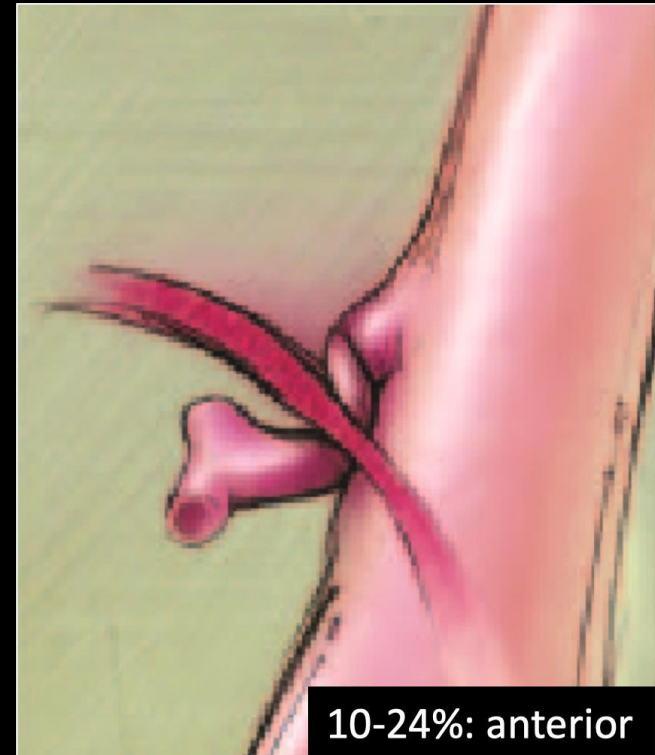
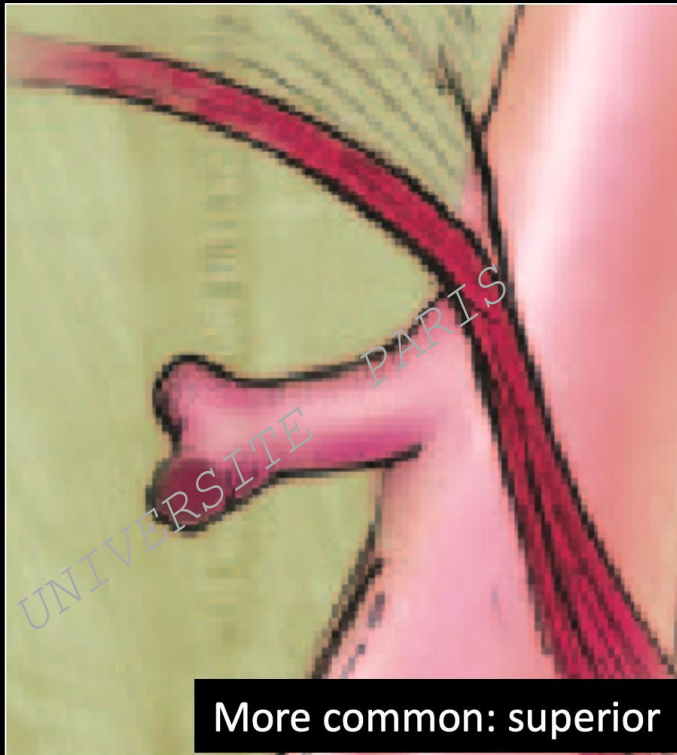
Image en crochet
Disparité de calibre
Aliasing

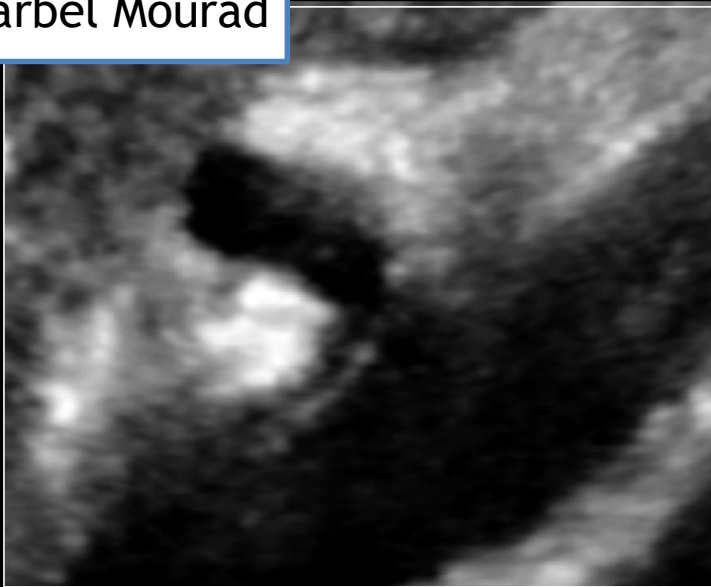
$v > 200 \text{ cm/s}$

Signes digestifs post prandiaux
Douleurs vomissements
Souffle

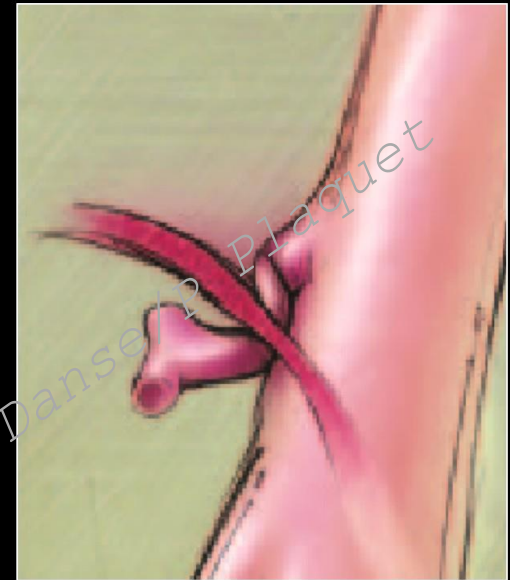
Median arcuate Ligament

- Fibrous band that unites the diaphragmatic crura
- At the level of aortic hiatus T12-L1

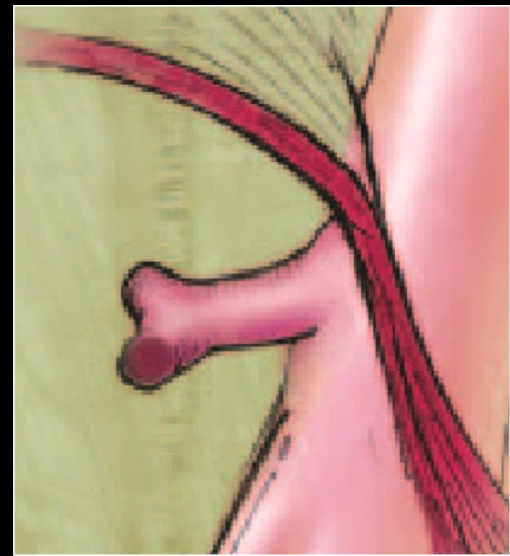
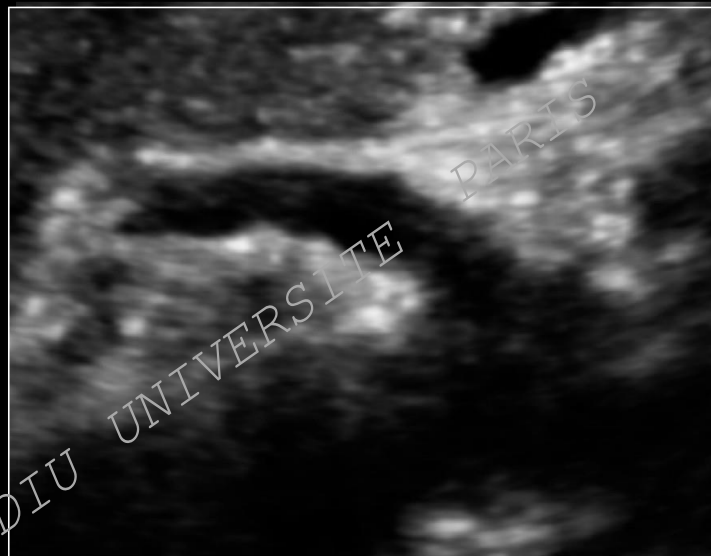

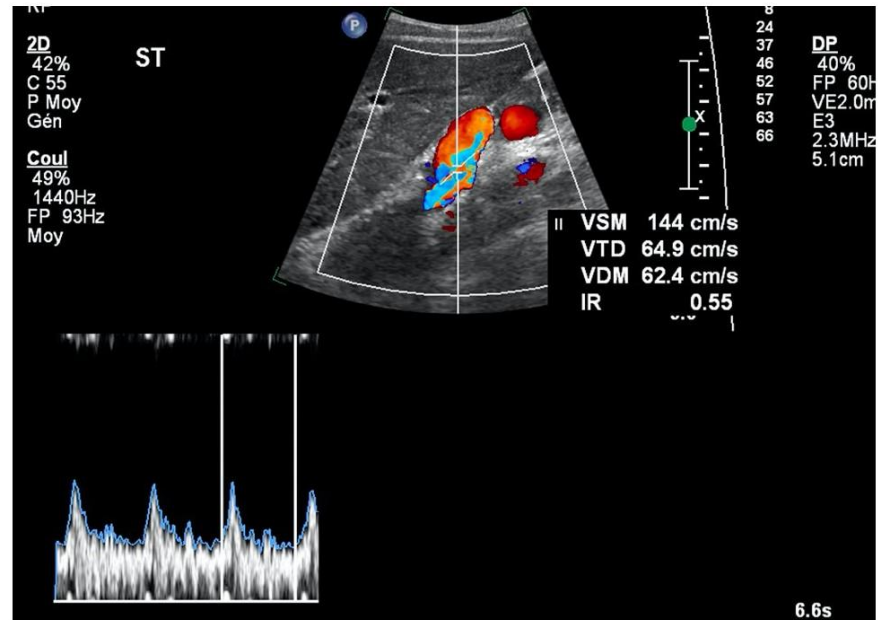
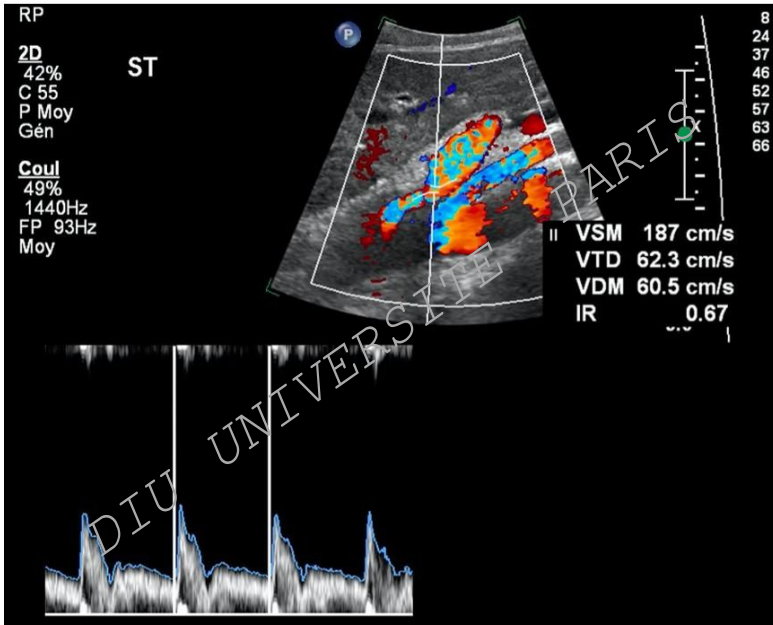
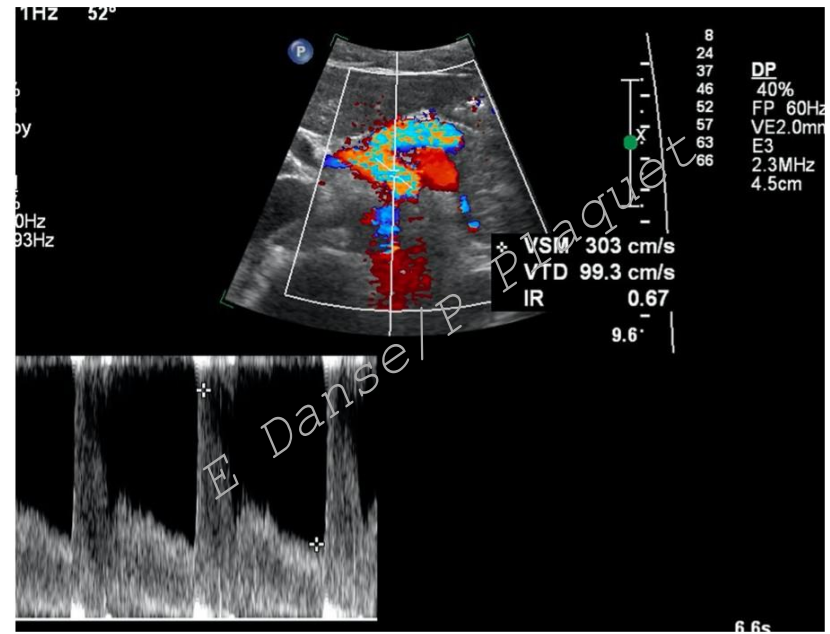

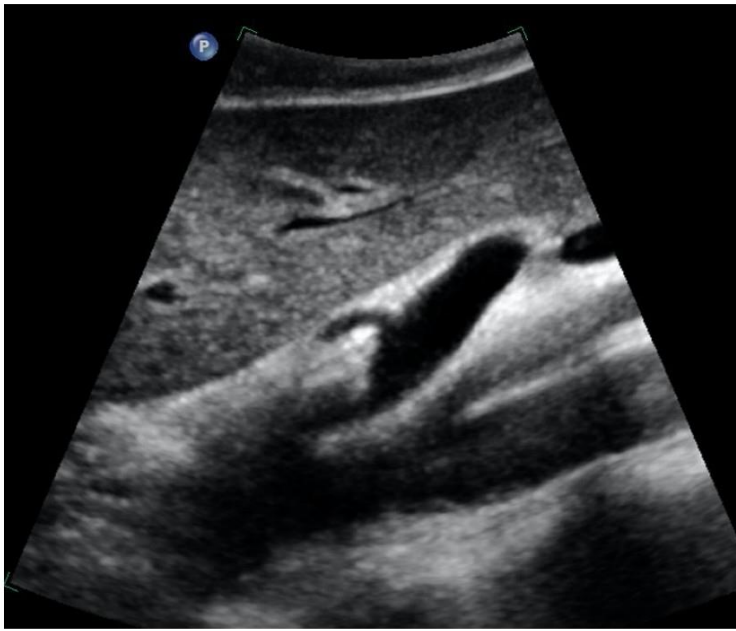
Expiration



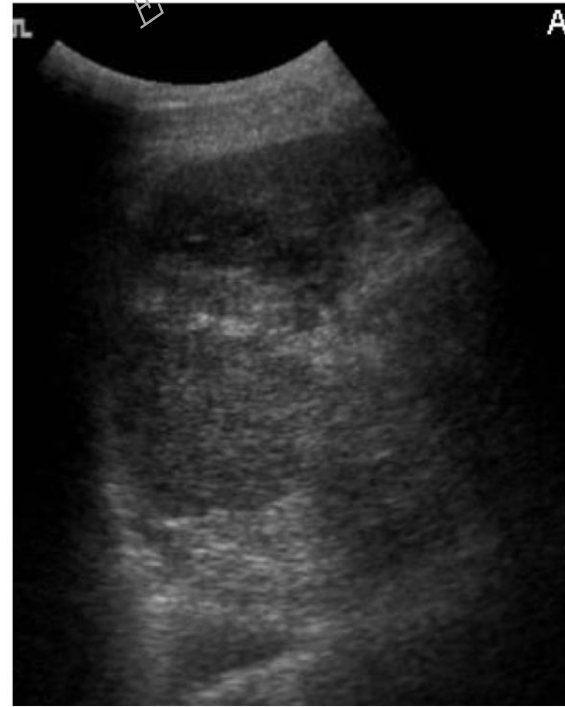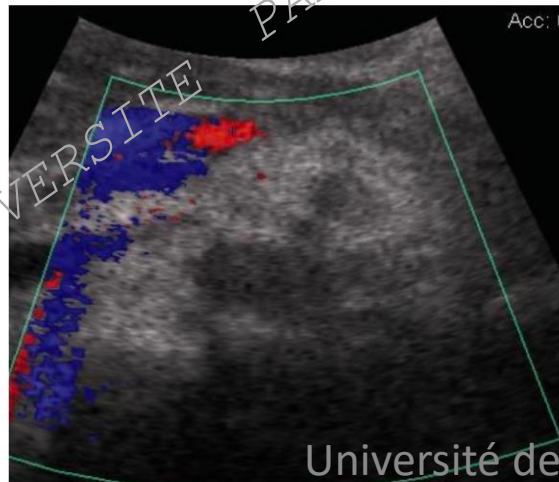
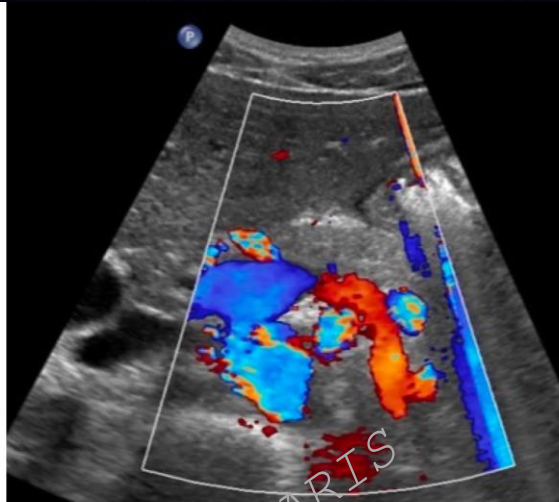
E. Danse, P. Plaquet



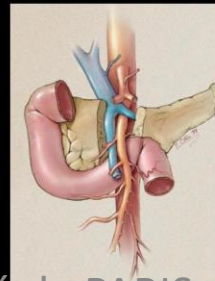
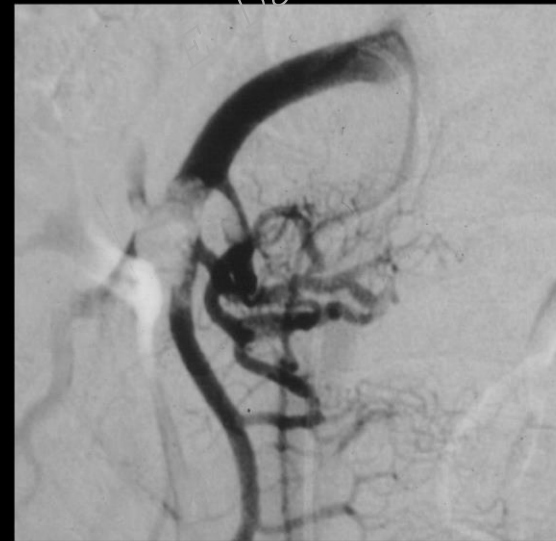
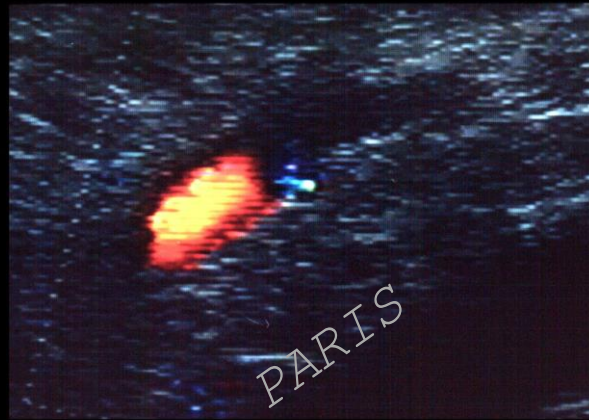
Artère mésentérique supérieure

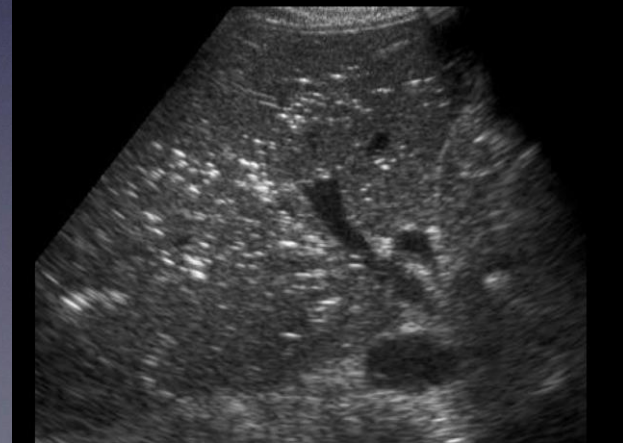
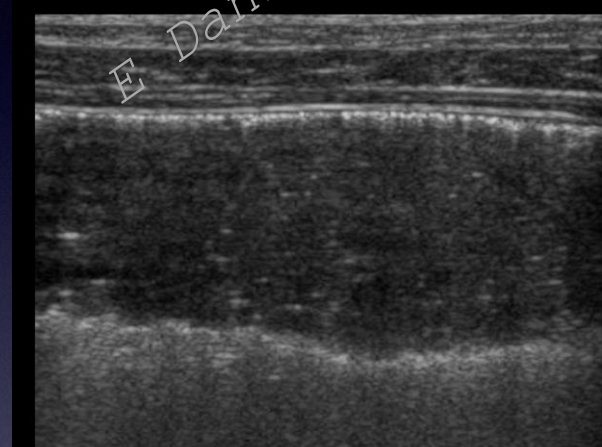
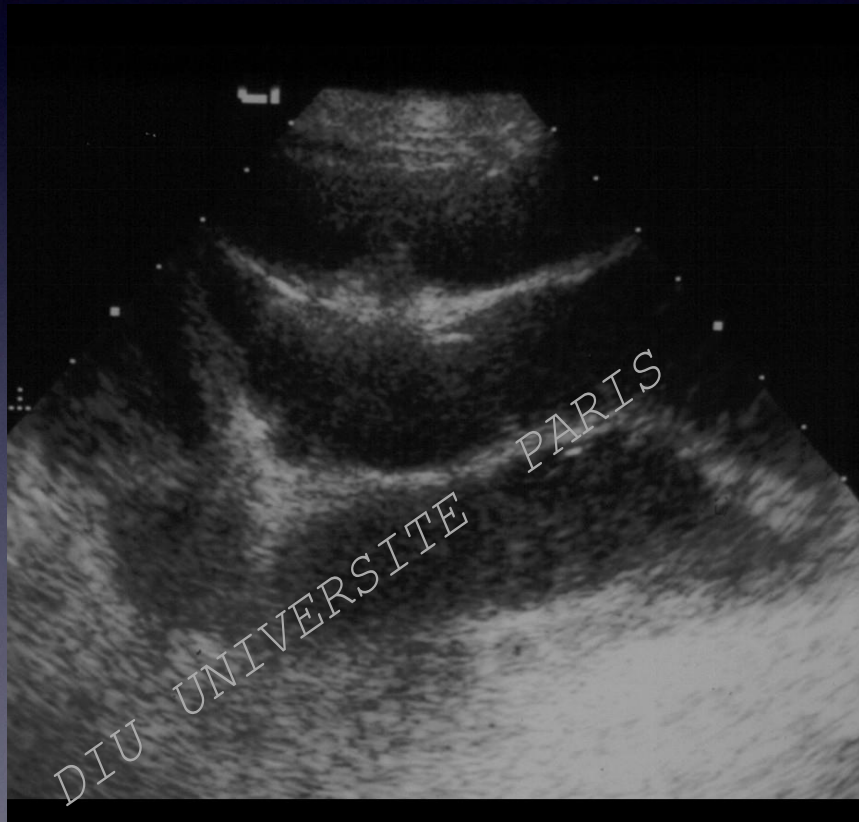
Infarctus mésentérique



Infarctus mésentérique

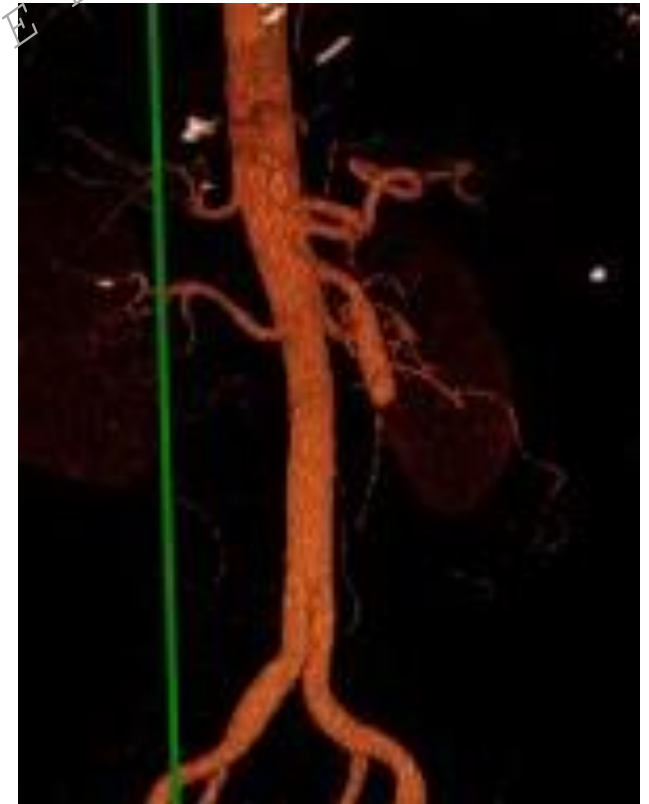
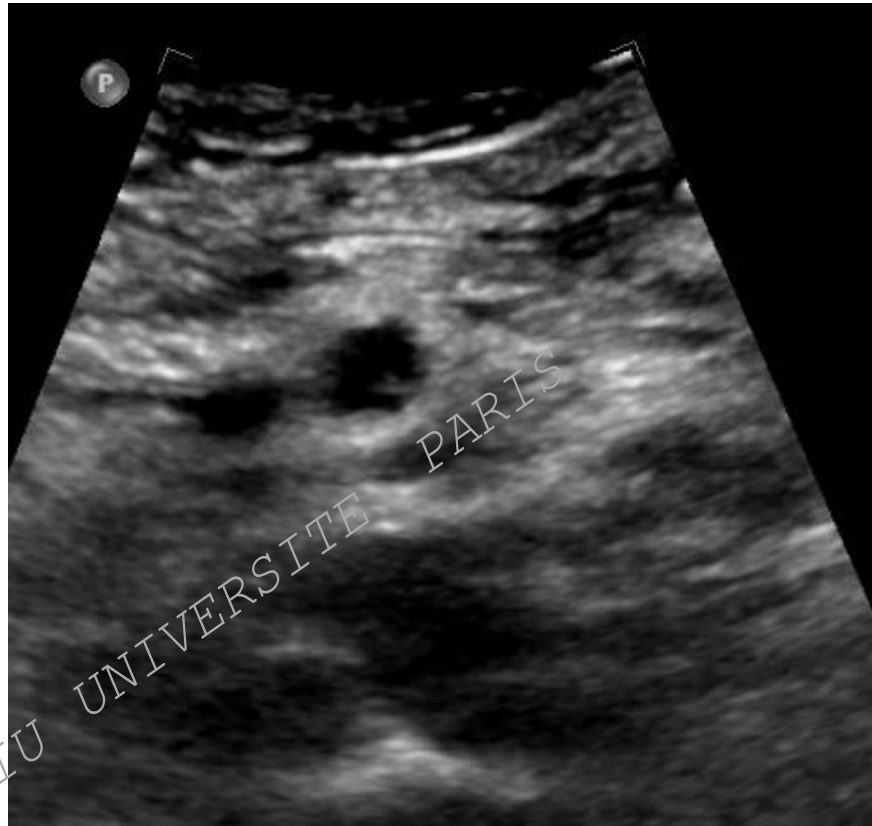
Infarctus mésentérique



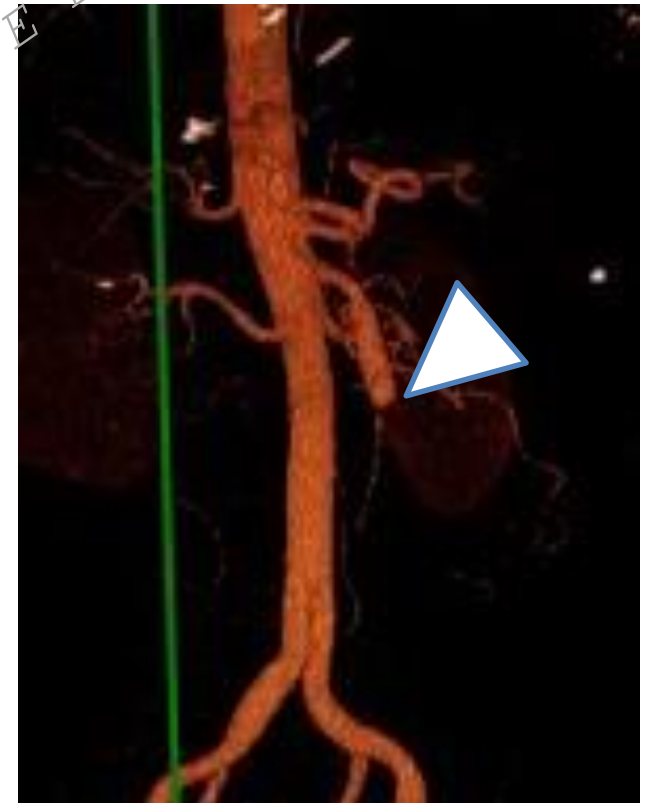
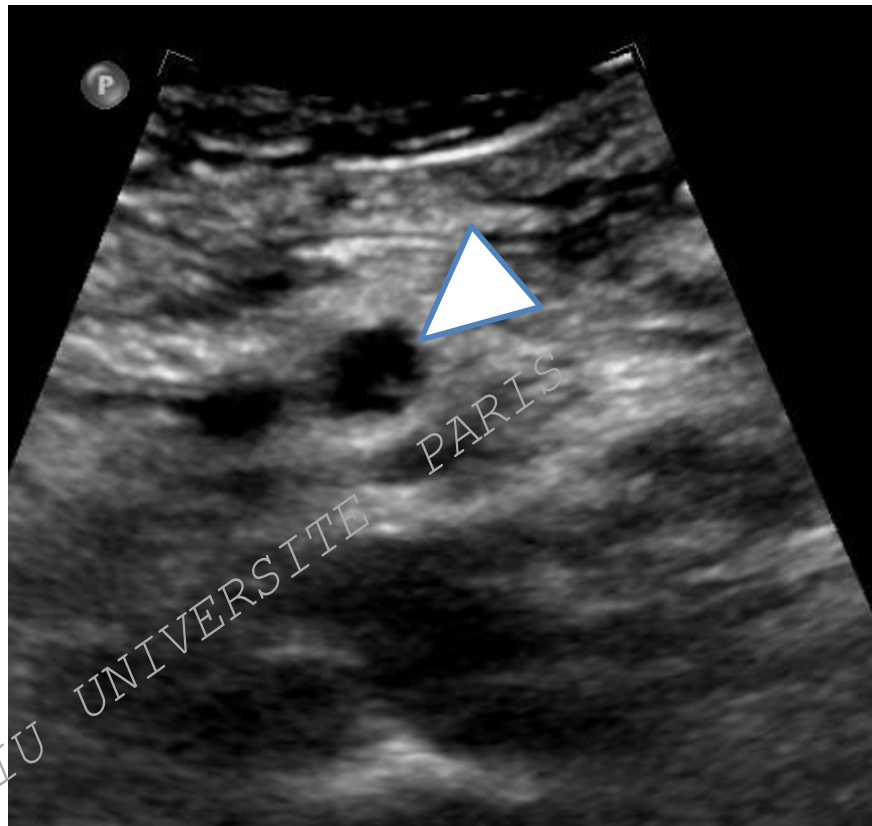
Infarctus mésentérique et dissection AMS

E. Danse/P. Plaquet

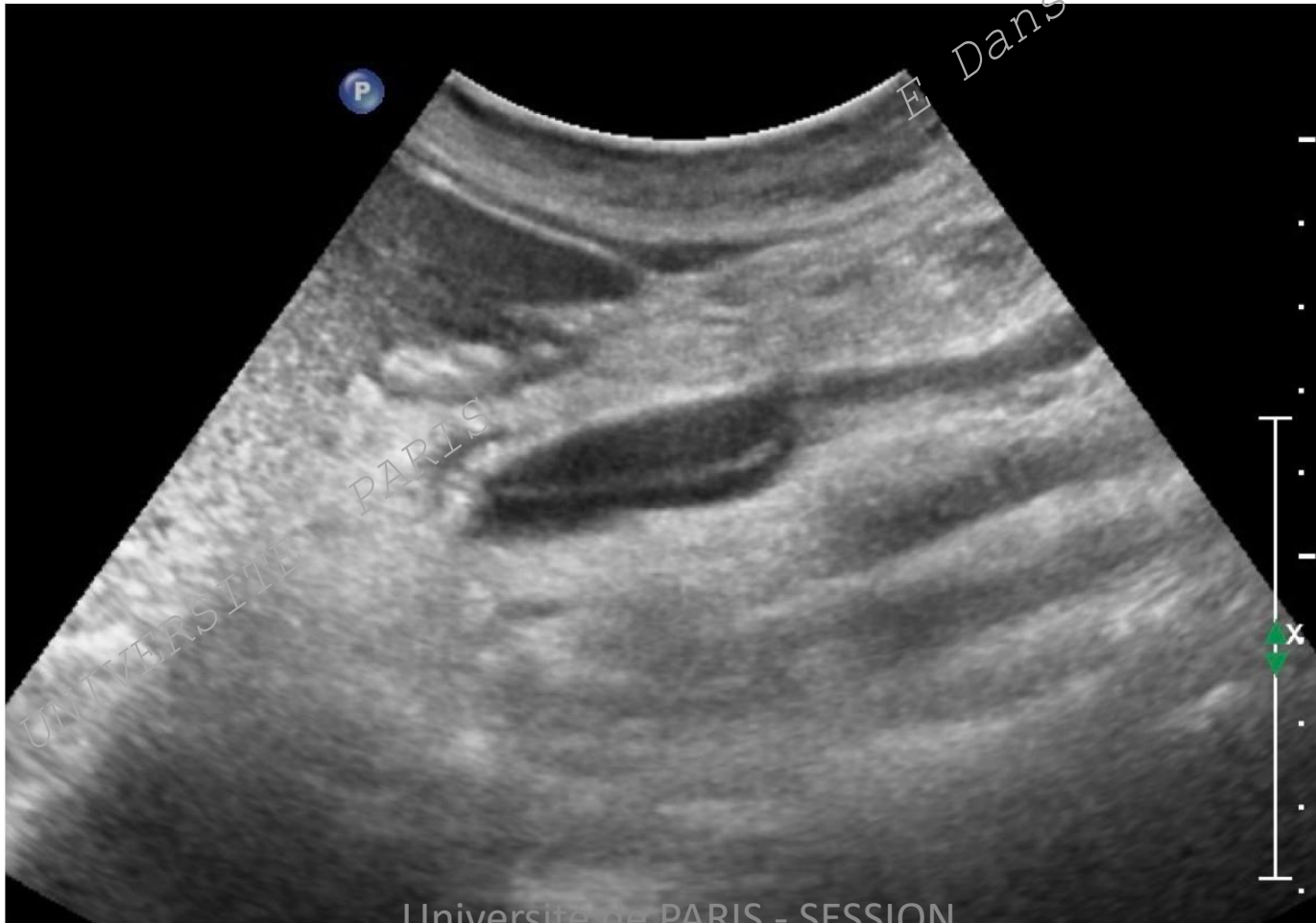

Infarctus mésentérique et dissection AMS

E. Danse/P. Plaquet



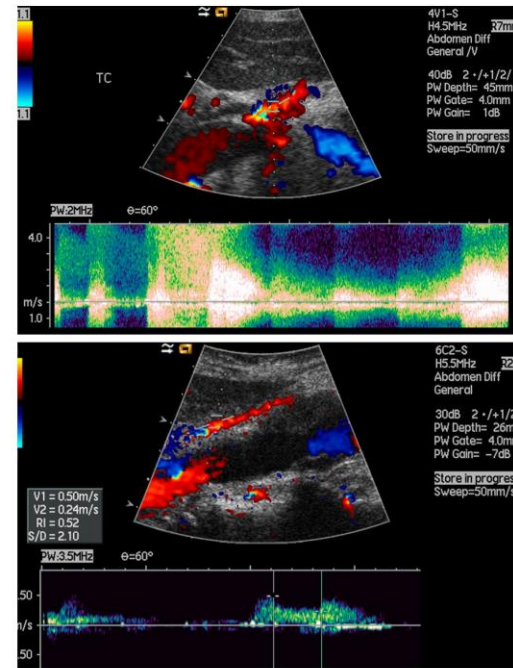
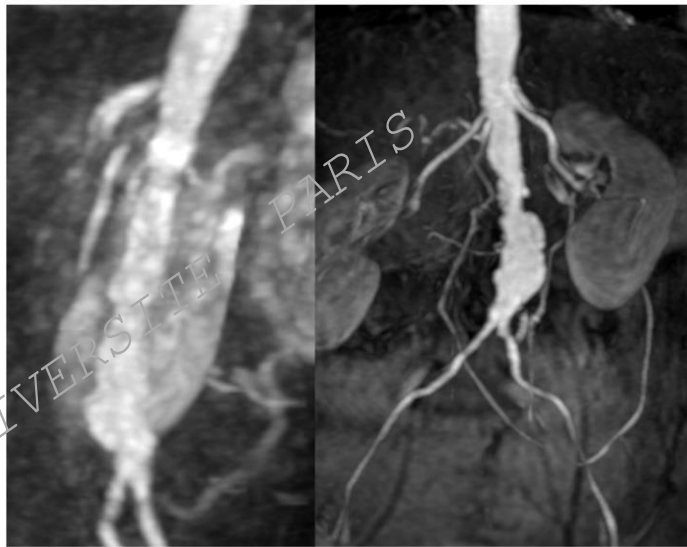
Infarctus mésentérique et dissection AMS

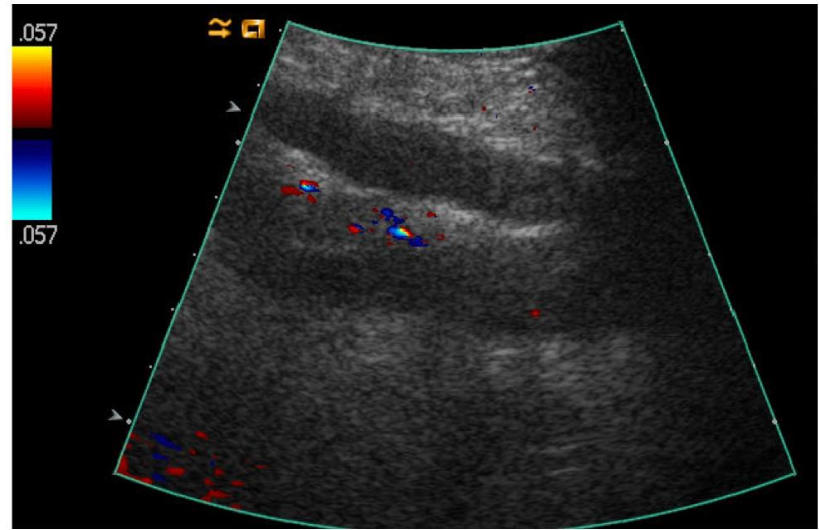
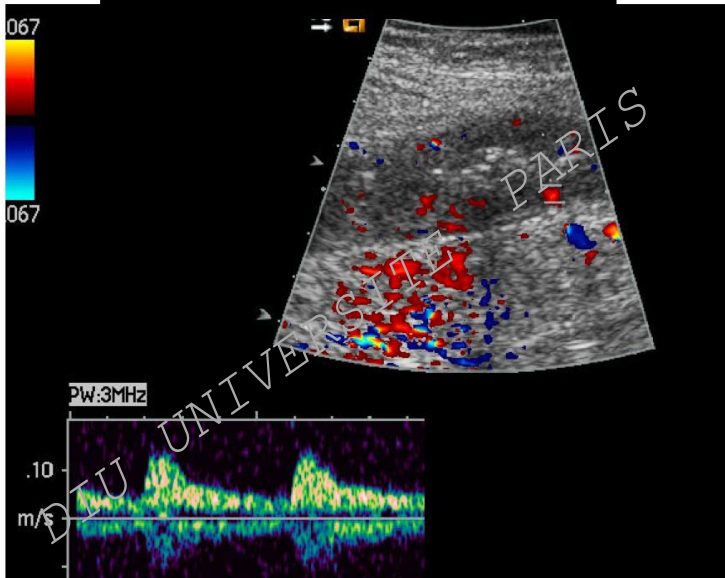
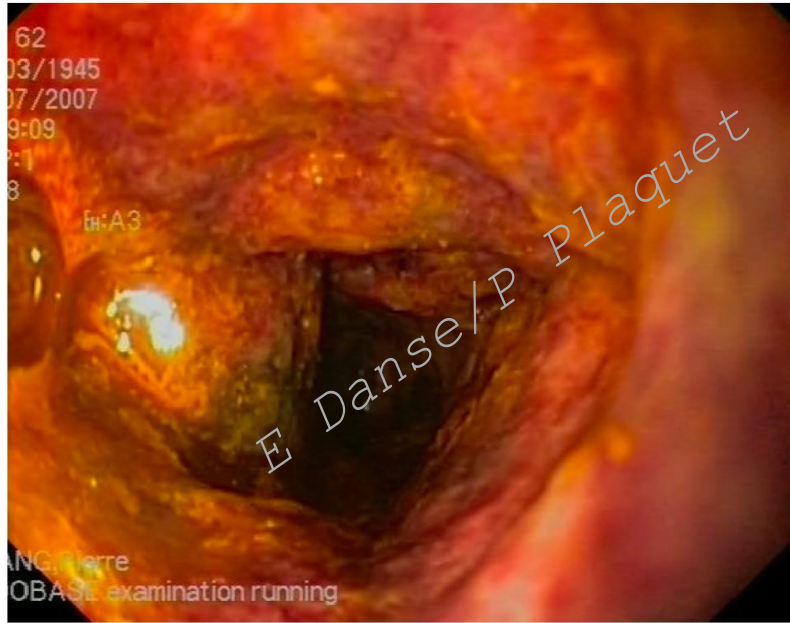
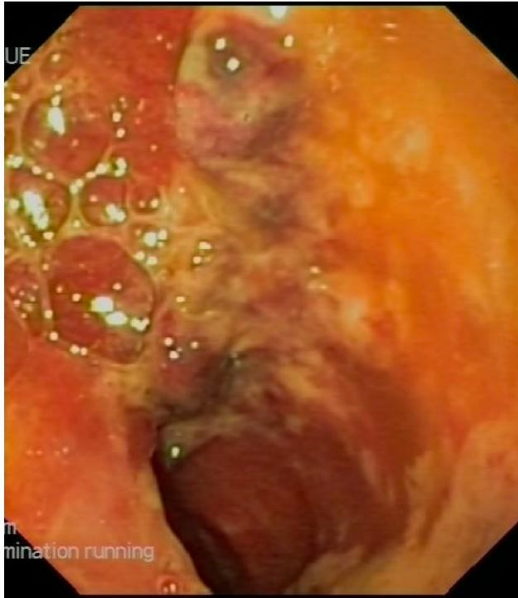
Colite ischémique

« Chronique »

US Doppler et colite ischémique

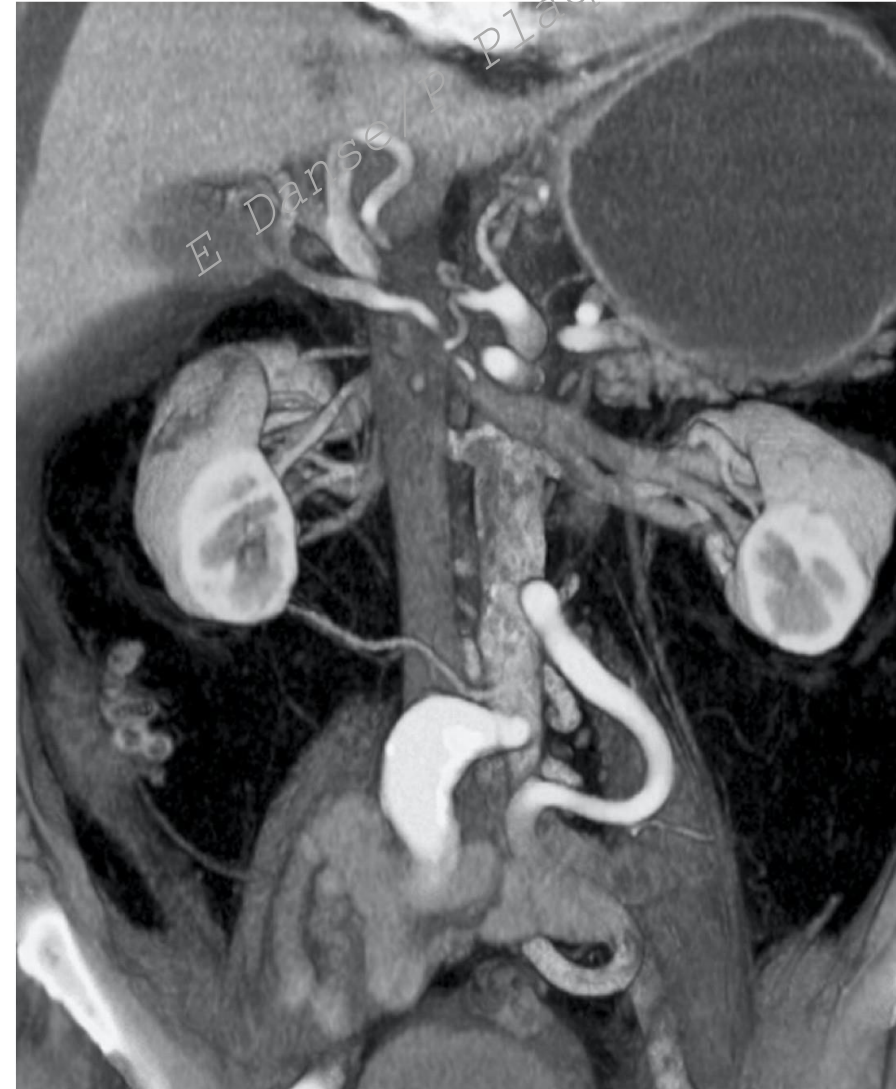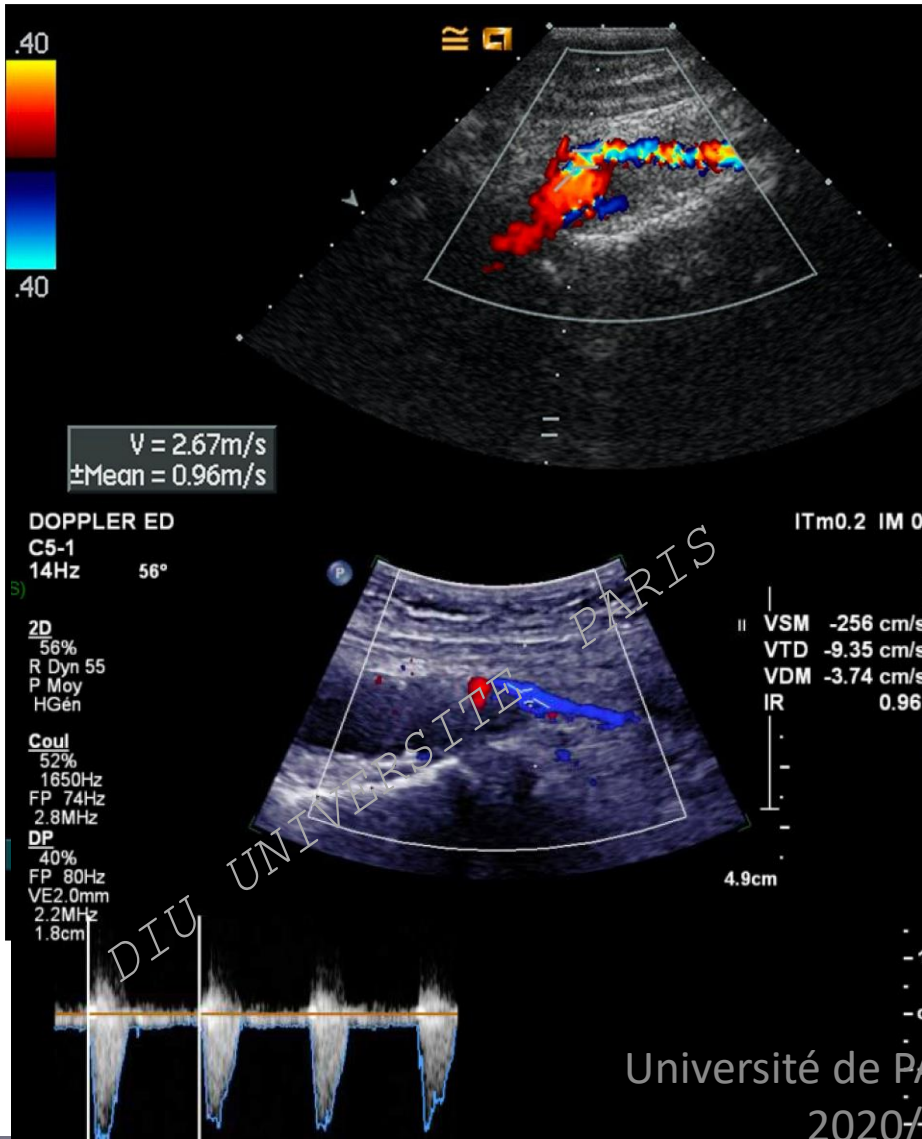




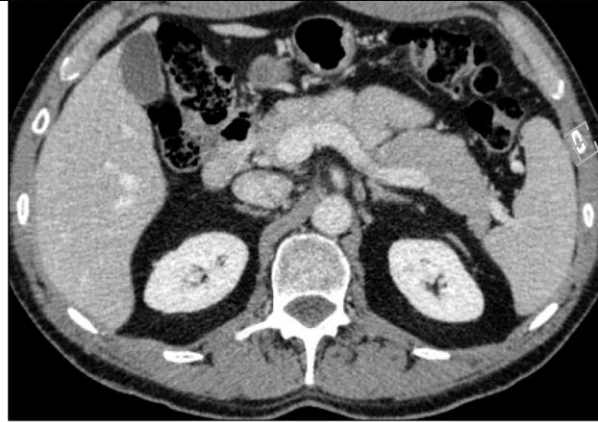
Résolution spontanée

Chirurgie pour nécrose

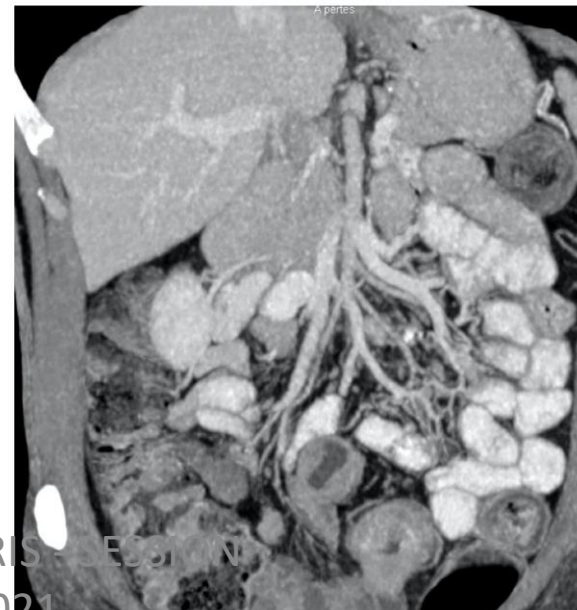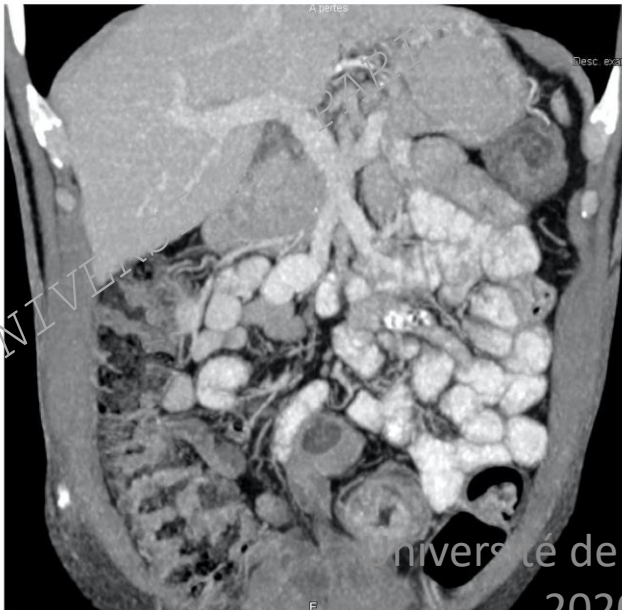ANGOR INTESTINAL : sténose &/ou occlusions de 2 des 3 vx digestifs : TC, AMS-aml

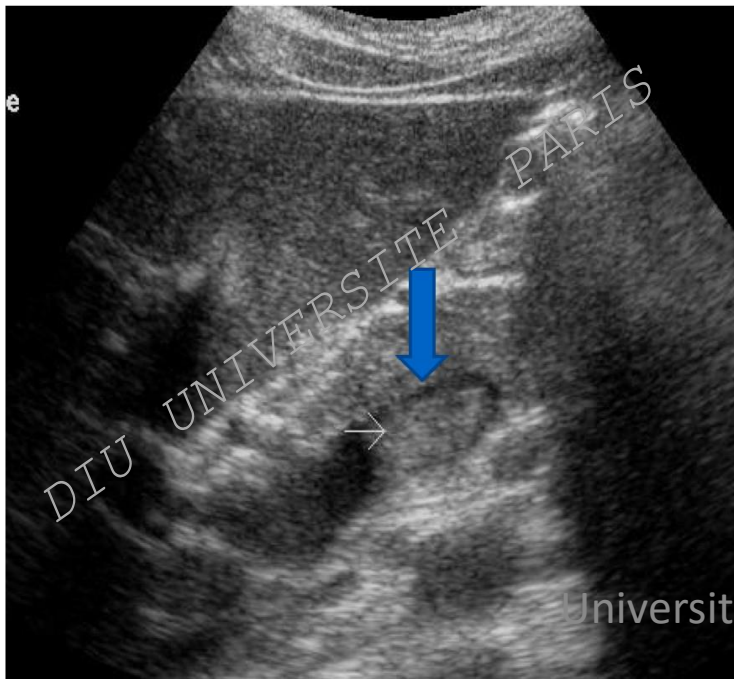
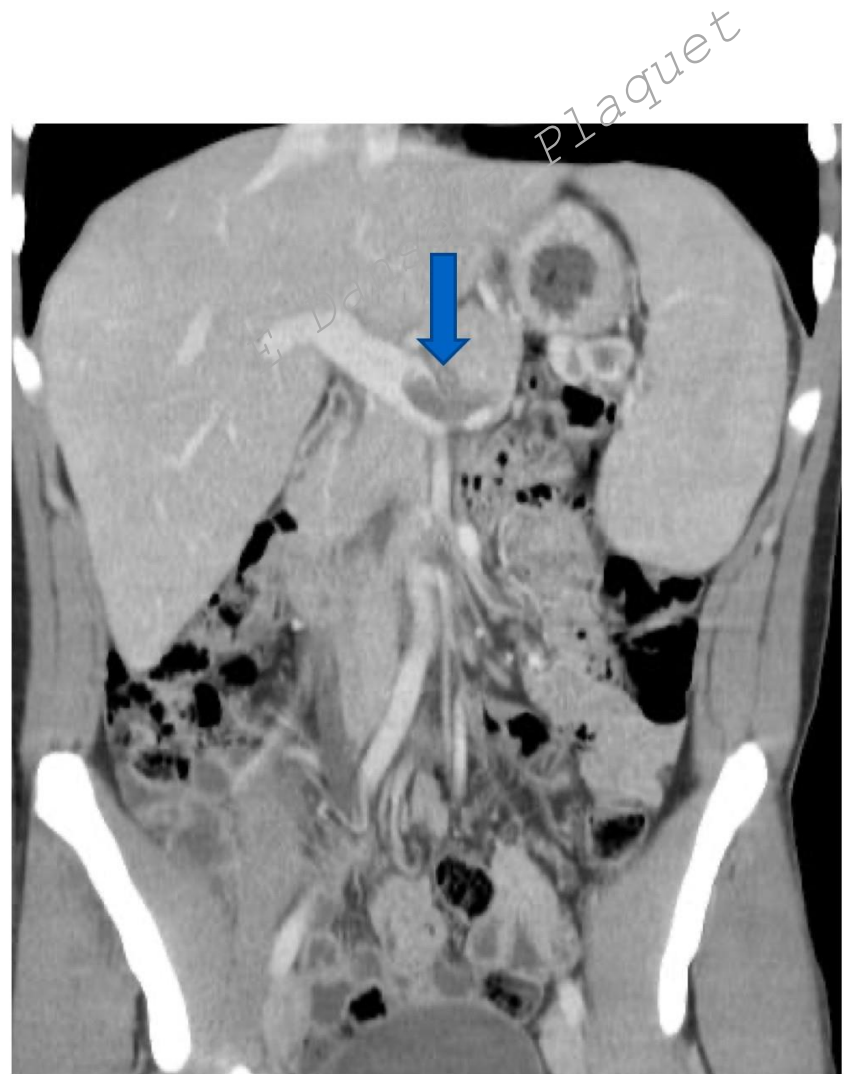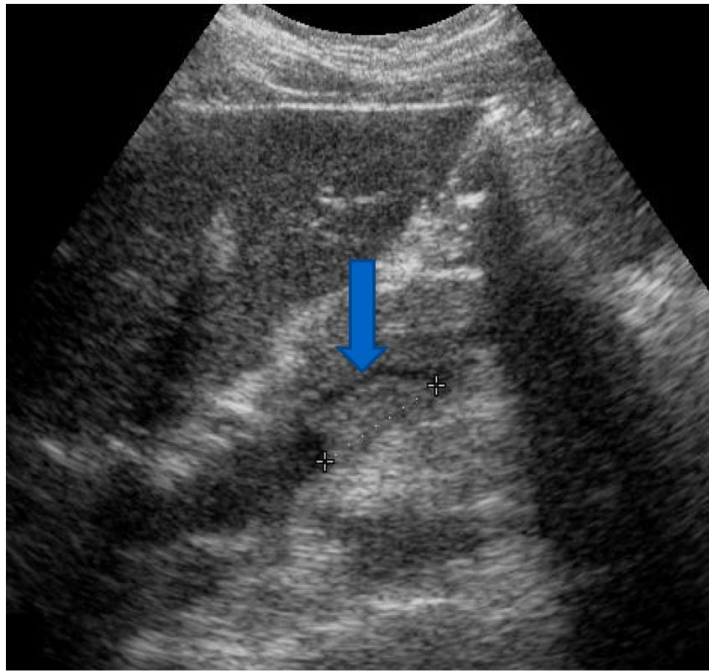


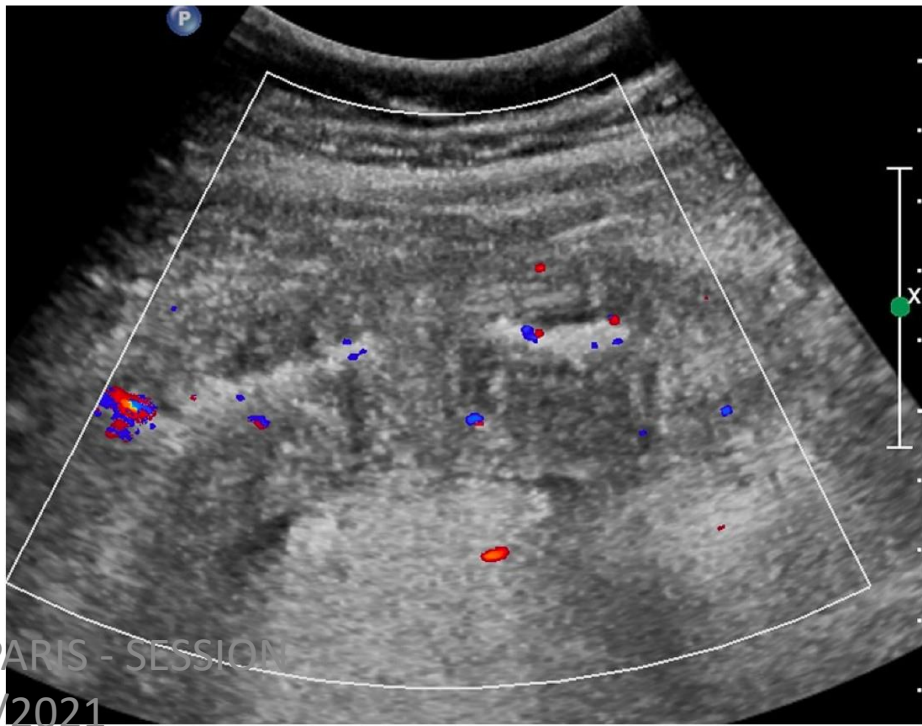
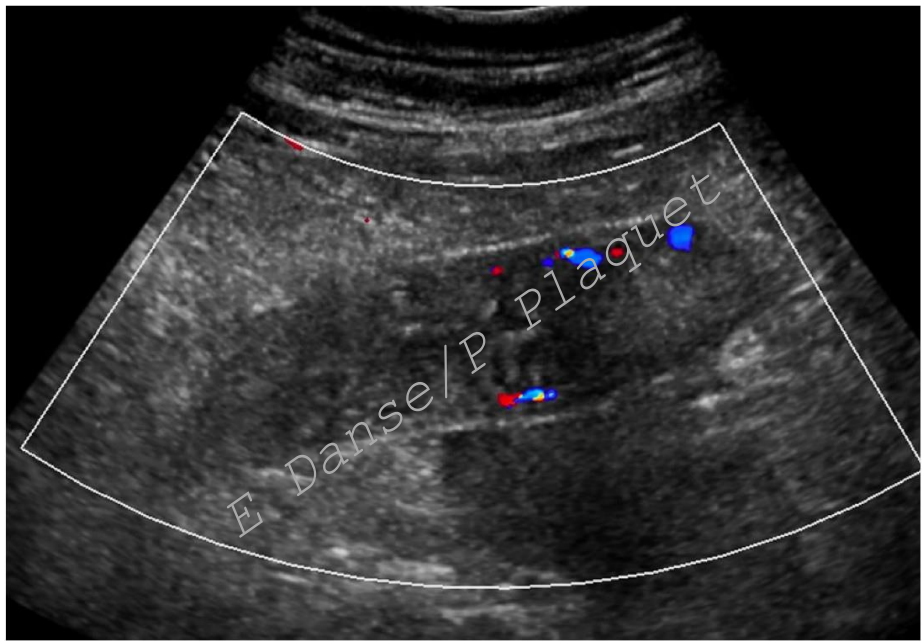
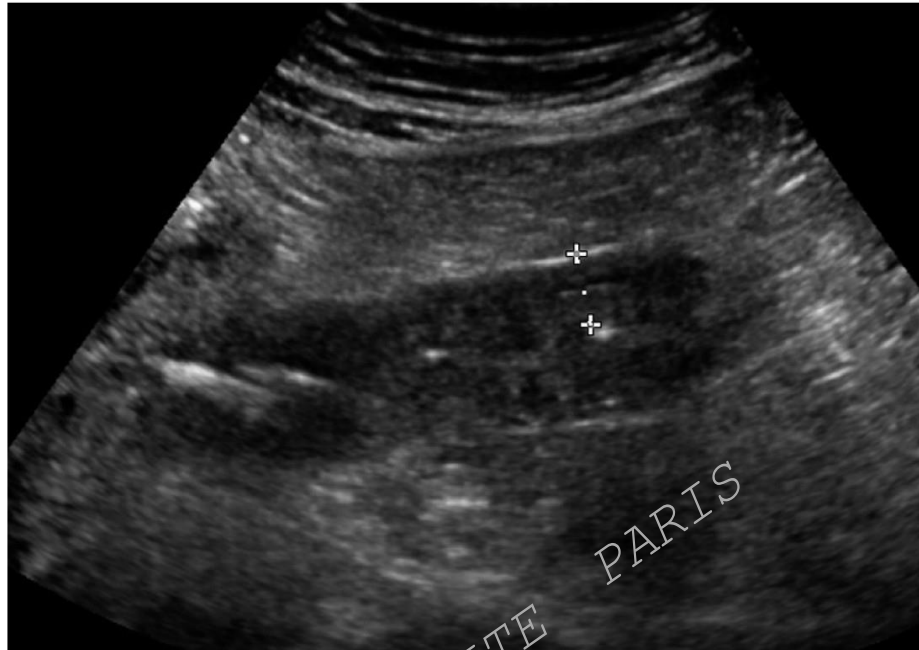Infarcissement mésentérique



Danse/P. Plaquet







DIU UNIVERSITE PARIS

réglages +++, changement de sondes
et de fréquences
Connaissance topographique
balayage méthodique

on ne trouve que ce que l'on cherche et
que ce que l'on connaît

Merci de votre attention

