

# DIU D'ECHOGRAPHIE ET TECHNIQUES ULTRA SONORES

MODULE DIGESTIF

2019/2020



## Notion d'écho-anatomie et de pathologie des gros vaisseaux abdominaux

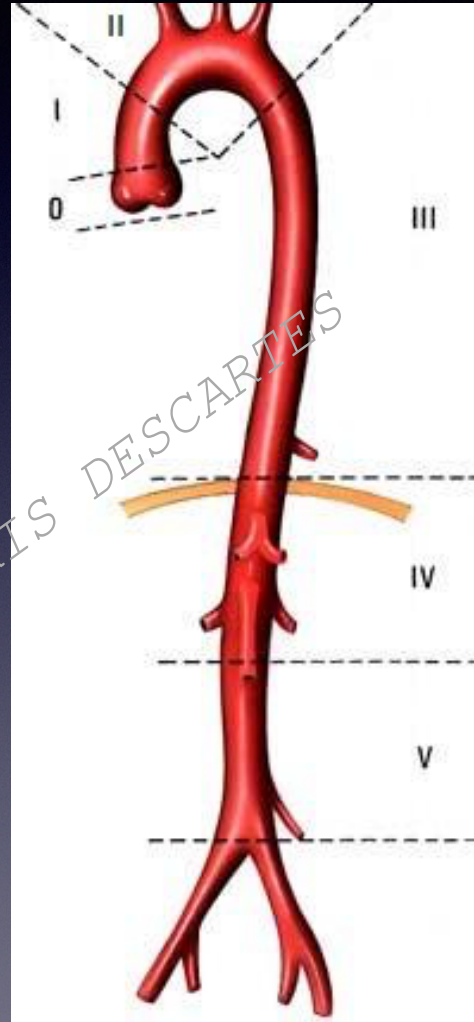
Professeur Etienne DANSE

Université Catholique de Louvain Cliniques Universitaires St Luc , 1200 Bruxelles

Docteur Pascale PLAQUET CAMUS

CHU Amiens - Péronne

# Echo-anatomie des gros vaisseaux abdominaux

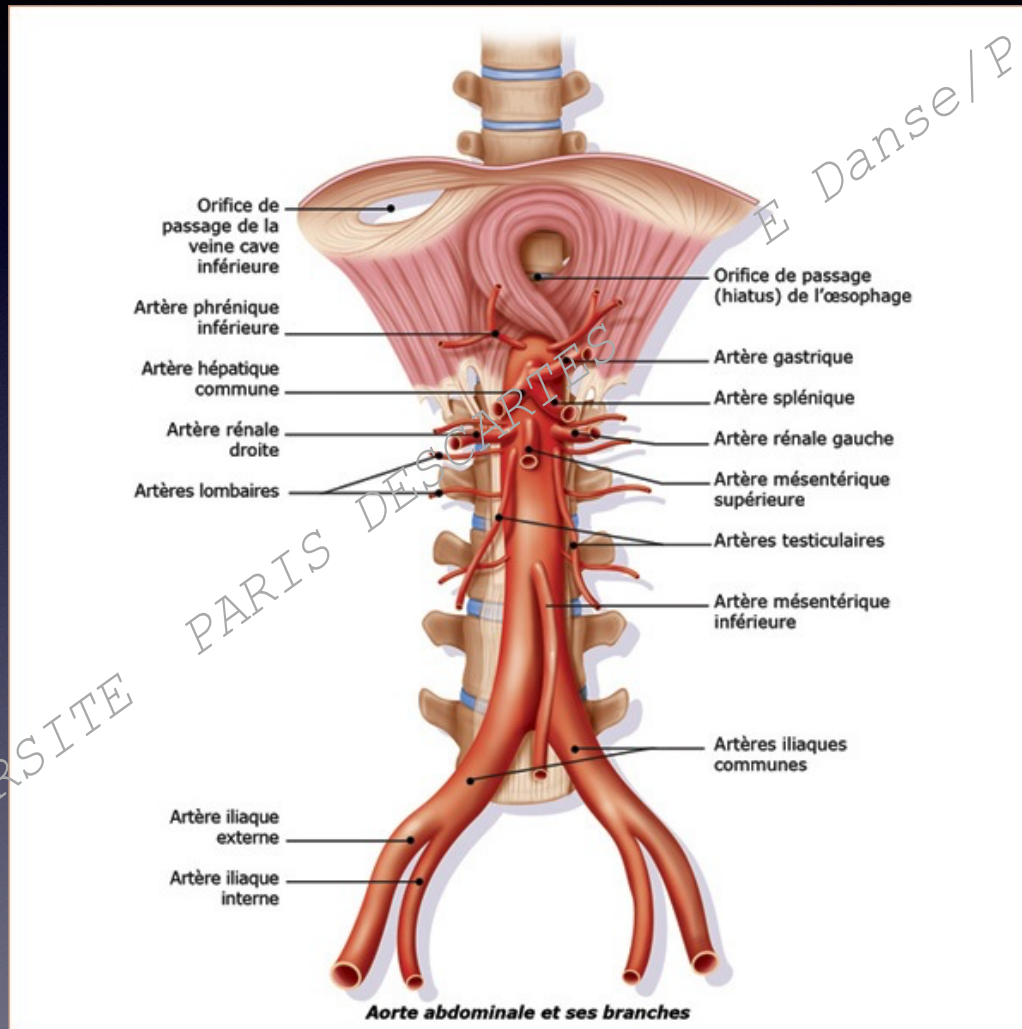


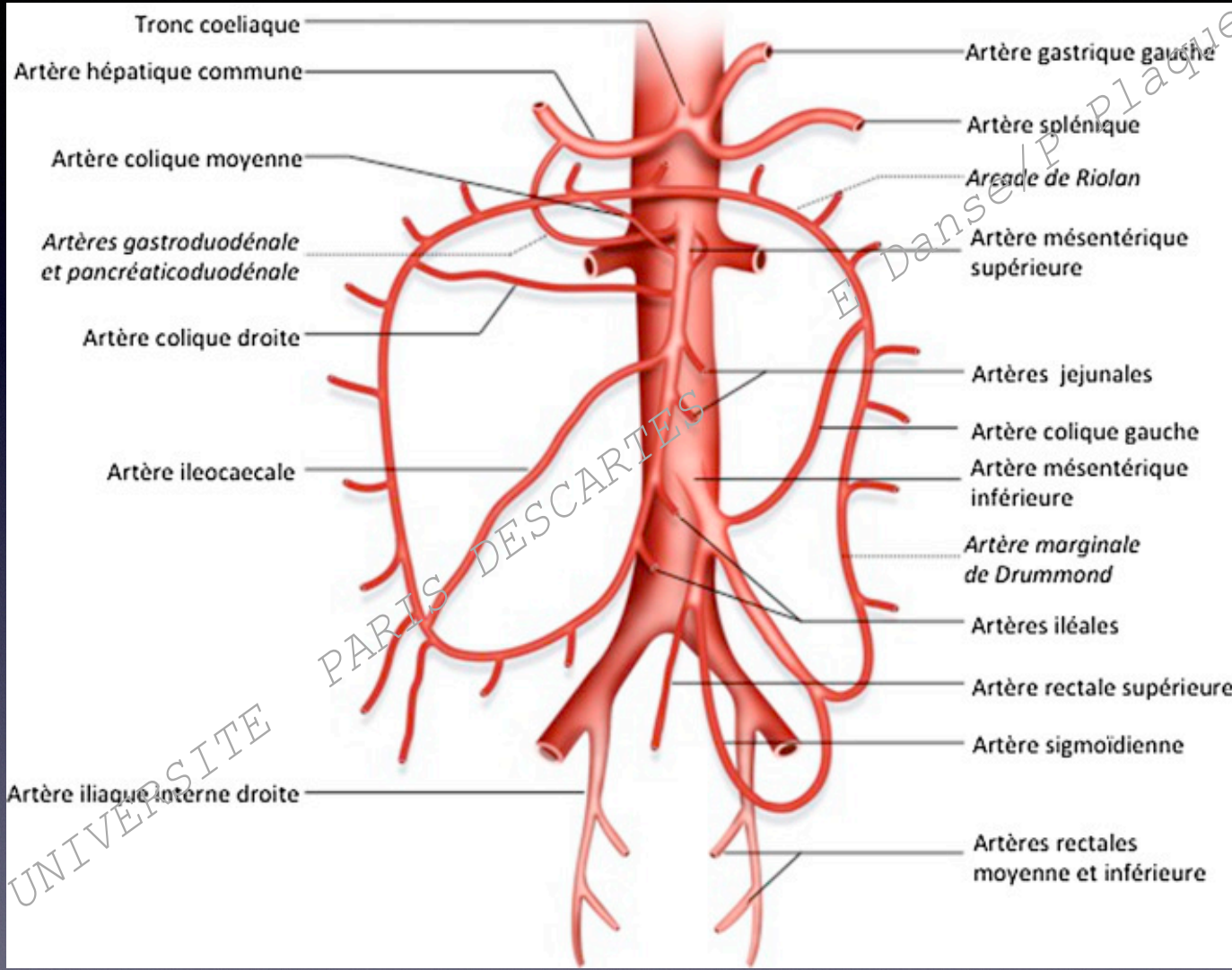
DIU UNIVERSITE

PARIS DESCARTES

E Danse/P Plaquet

# Echo-anatomie des gros vaisseaux abdominaux





DIU UNIVERSITE

PARIS DESCARTES

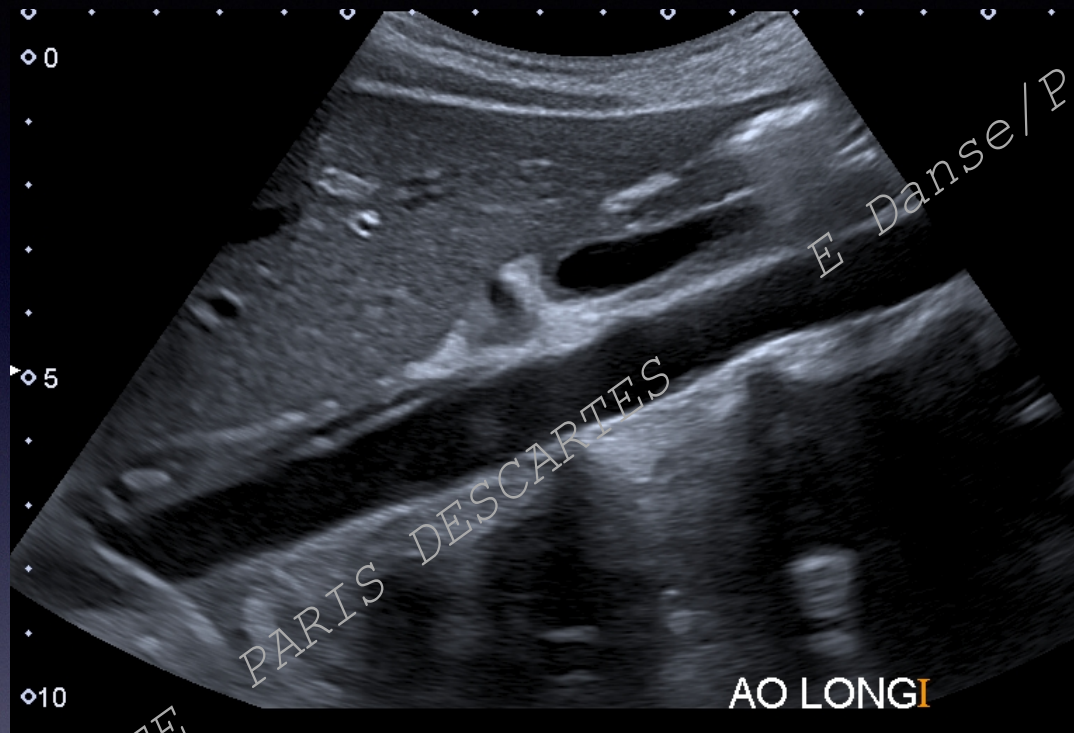
Et dans le Plaque

# Echo-anatomie des gros vaisseaux abdominaux

## Technique d'examen

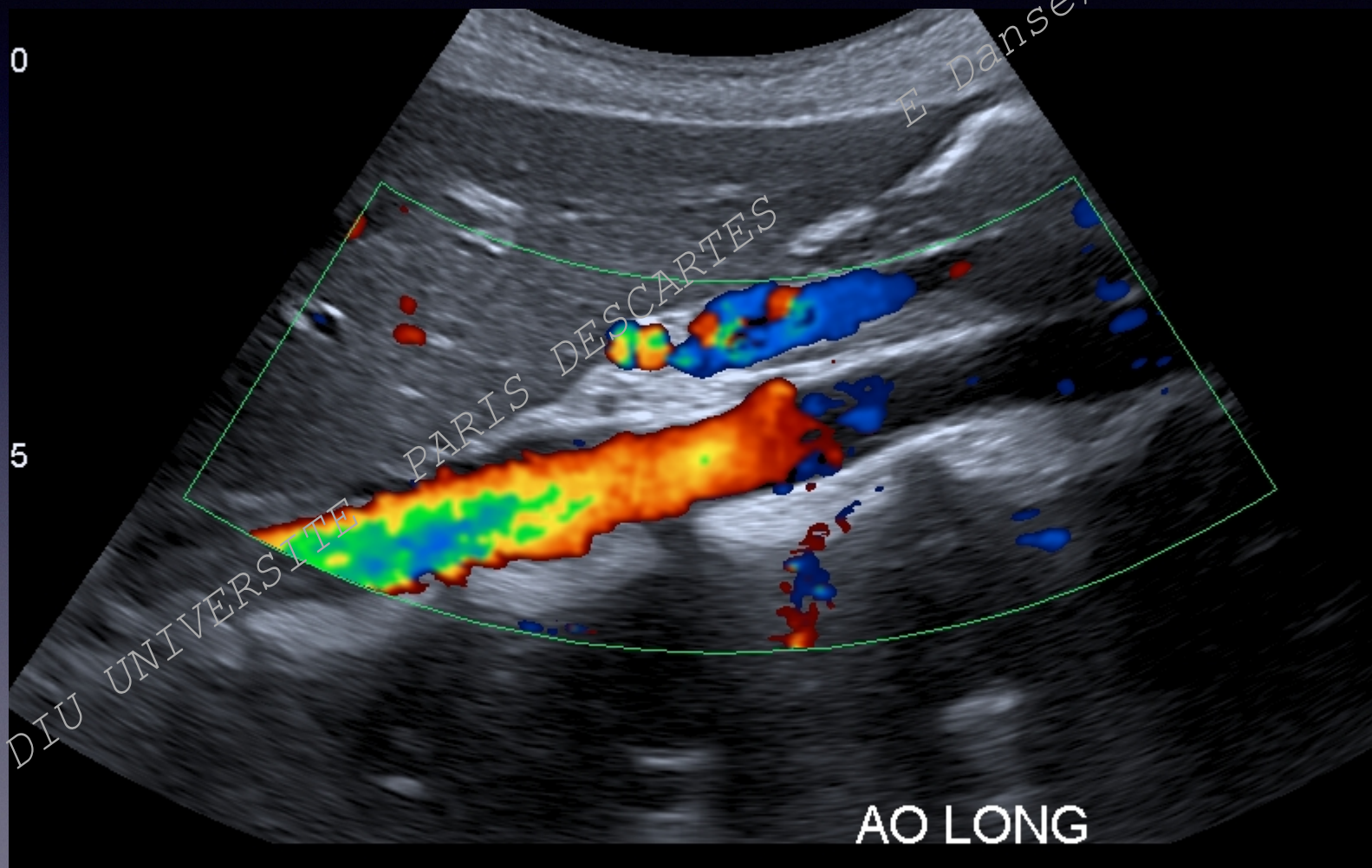
- Décubitus dorsal +/- latéral
- À jeun ,
- pression/ tube digestif
- Coupe transversale et longitudinale
- Sonde sectorielle fréquences adaptées  
3/10 mhz THI

# Aorte abdominale

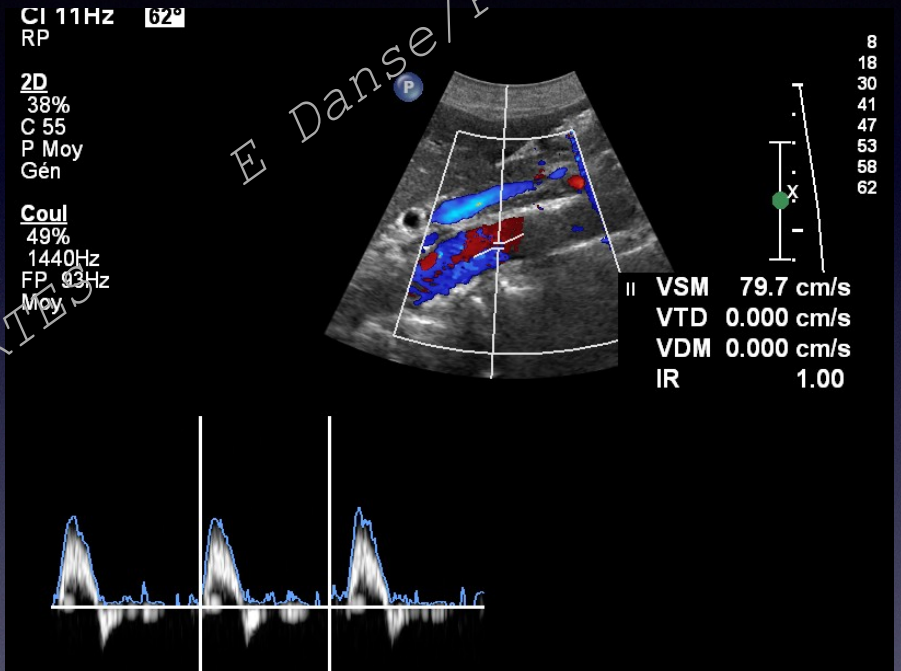
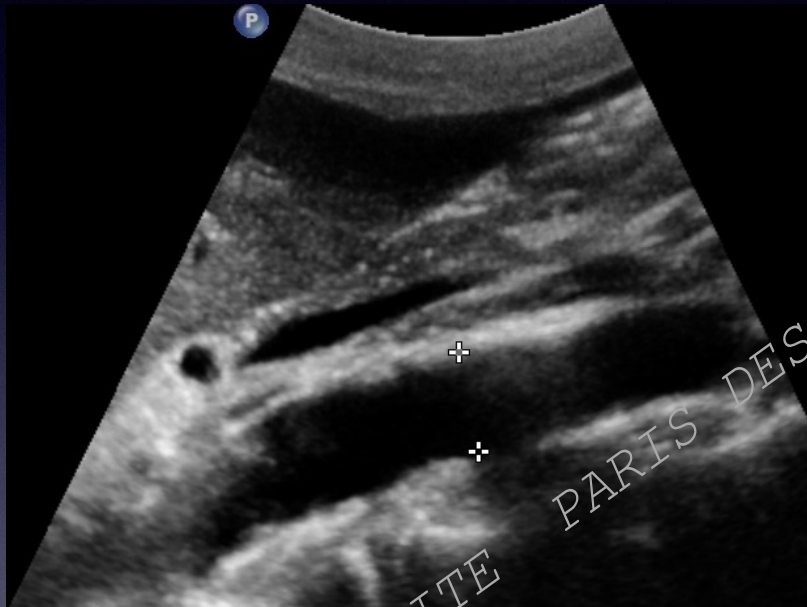

Calibre normal : <28 mm sus rénal  
<18 mm sous rénal  
Lumière hypo/ anéchogène  
Paroi fine et régulière

# Aorte abdominale



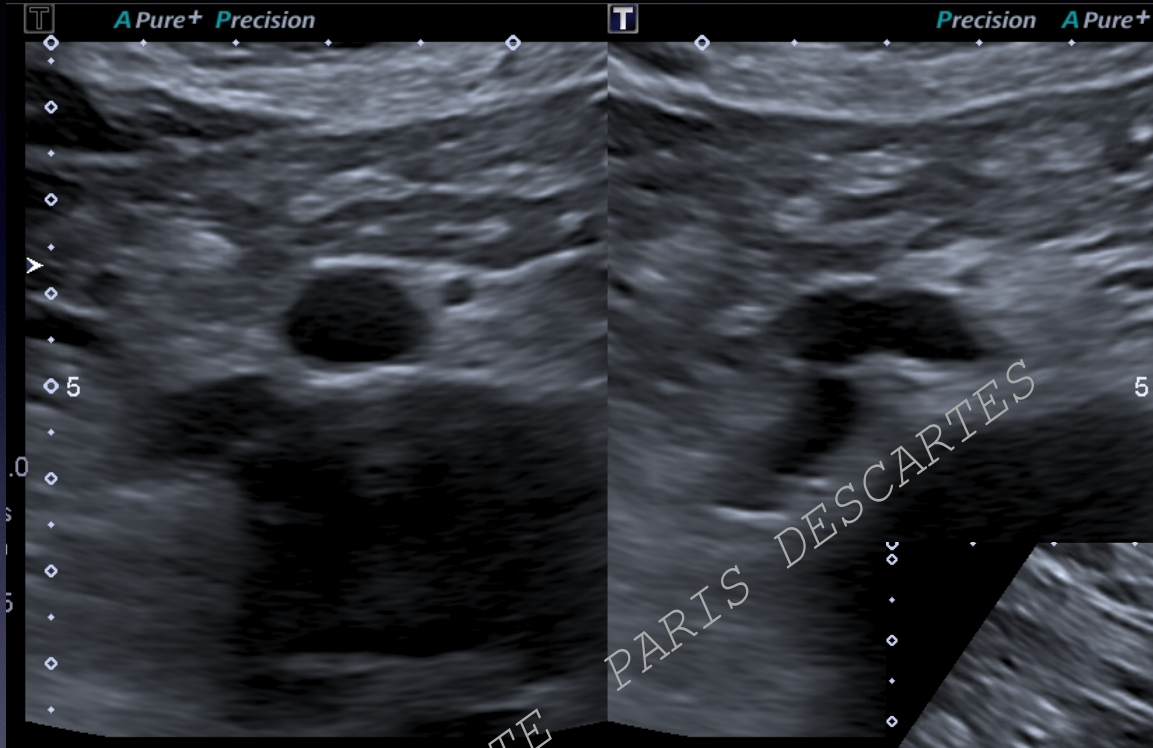
# Aorte abdominale



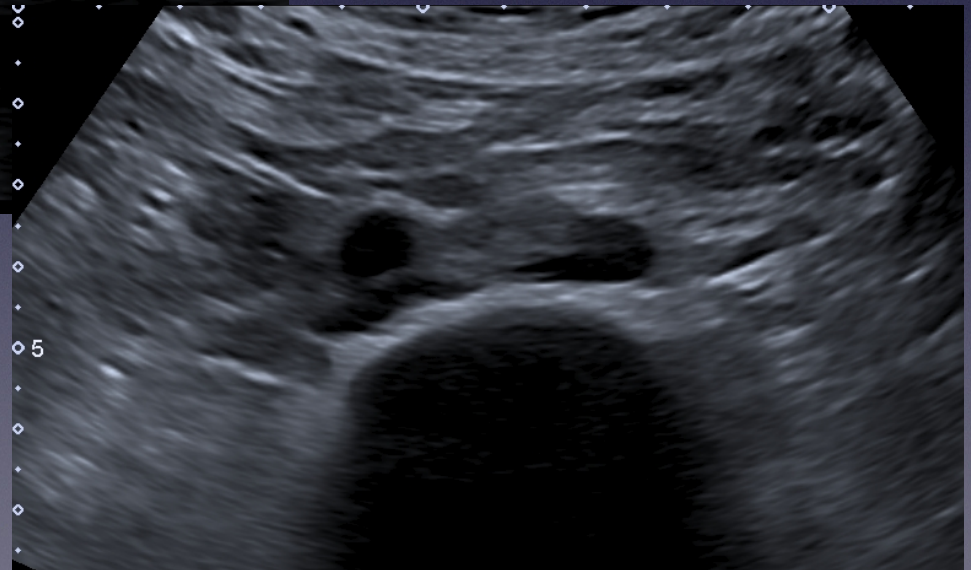Doppler : flux triphasique  
Reflux proto diastolique  
v 50- 180 cm/s. v moyenne 40-80 cm/s



# Aorte abdominale



E Danse/P Plaquet



Bifurcation

# Anévrisme aortique

Diamètre transverse  
> 30 mm  
> 40 mm risque de rupture  
Plan de coupe / surveillance

Sous rénal ++

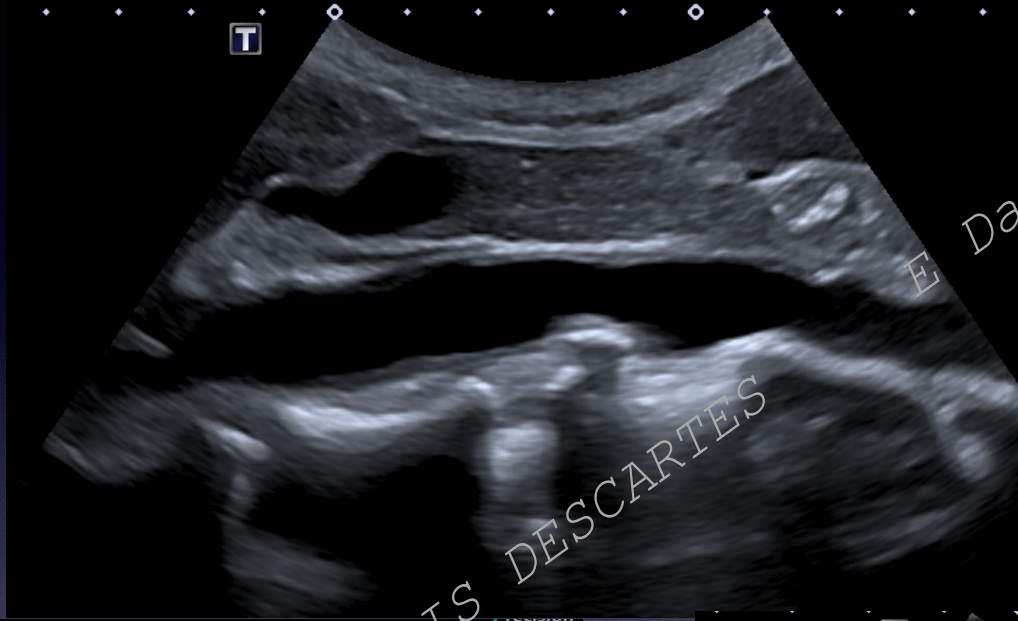
Thrombus  
Hématome

E Danse/P Plaquet

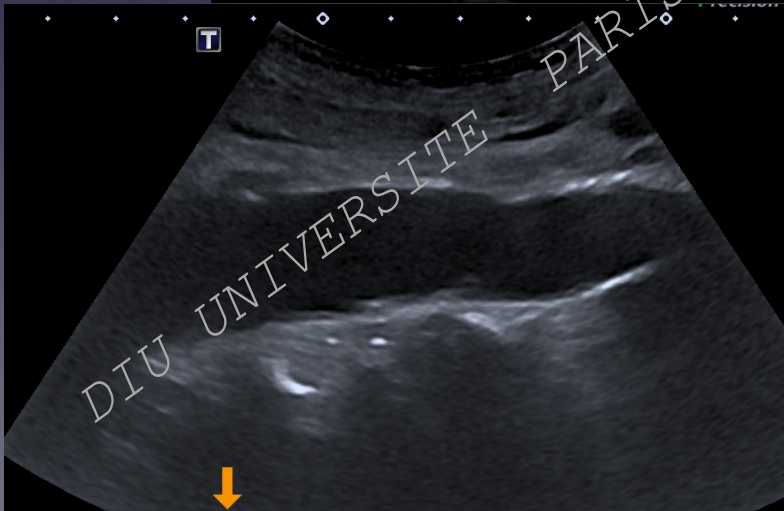
DIU UNIVERSITE PARIS DESCARTES

PARIS DESCARTES

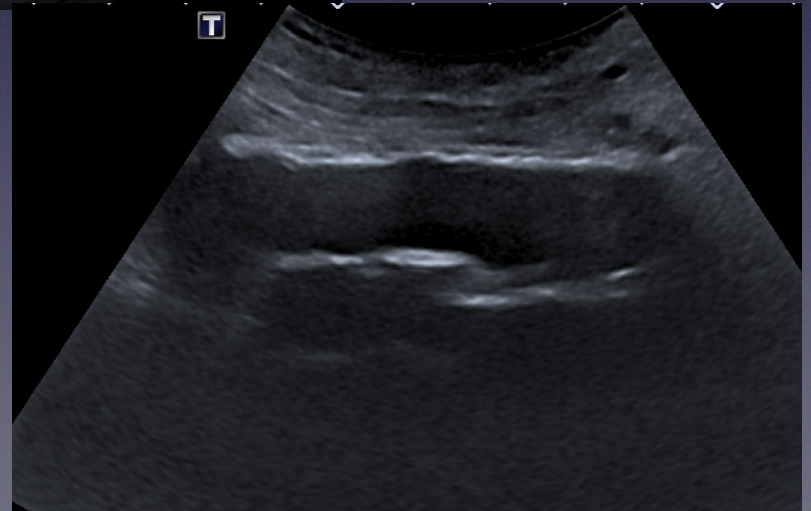
# Aorte abdominale contours , paroi



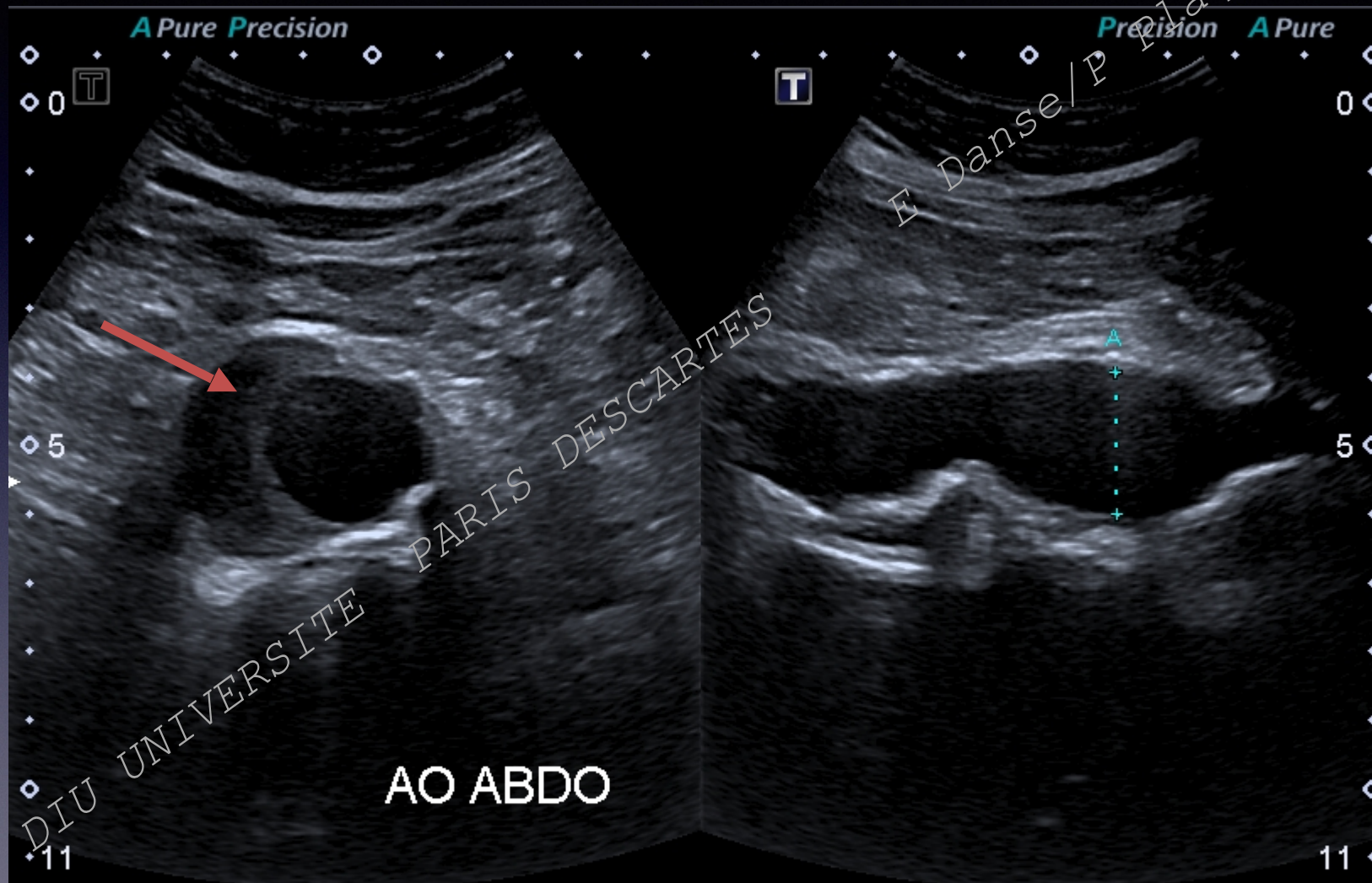
E Danse/P Plaquet



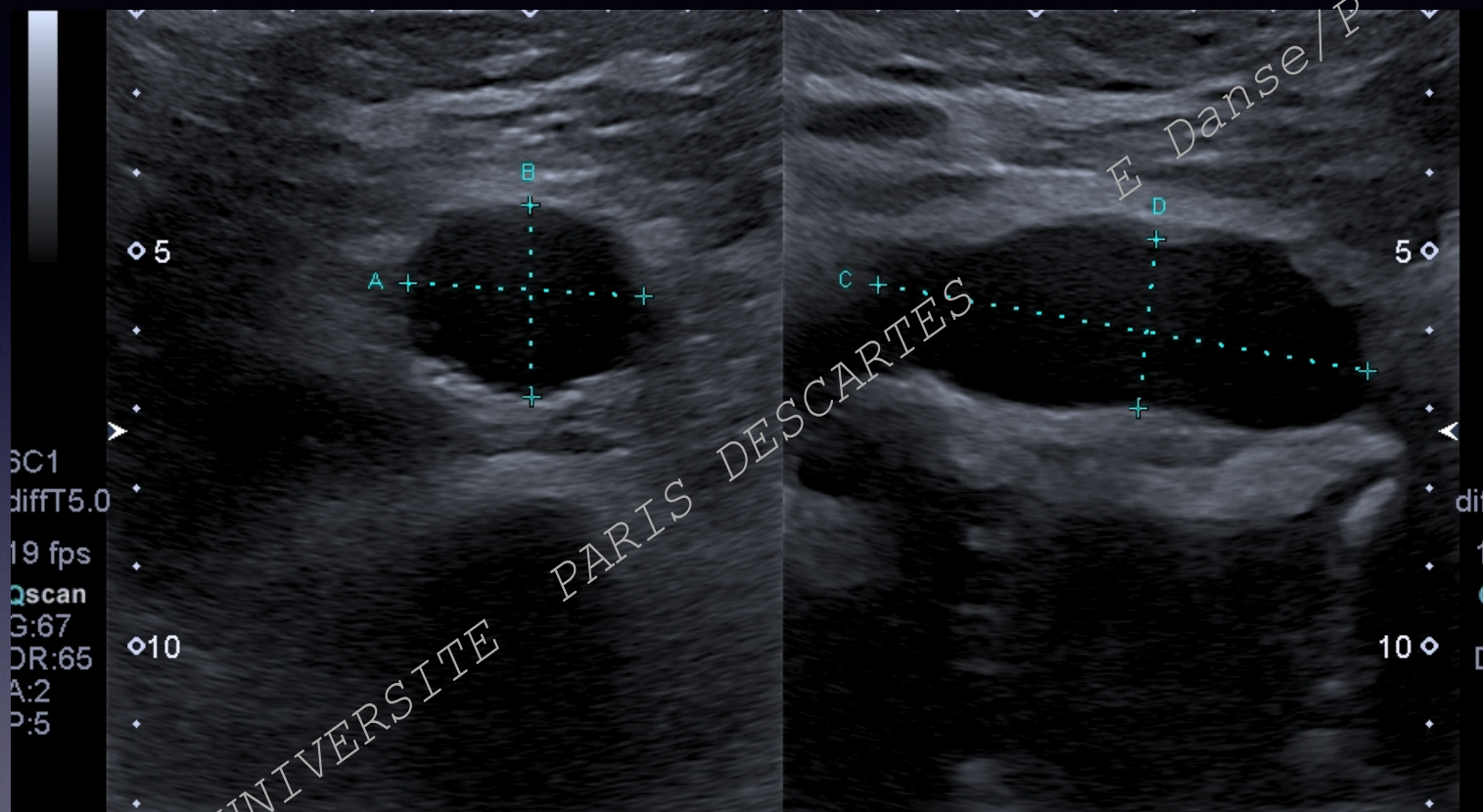
DIU UNIVERSITE PARIS DESCARTES



# Anévrysme aortique

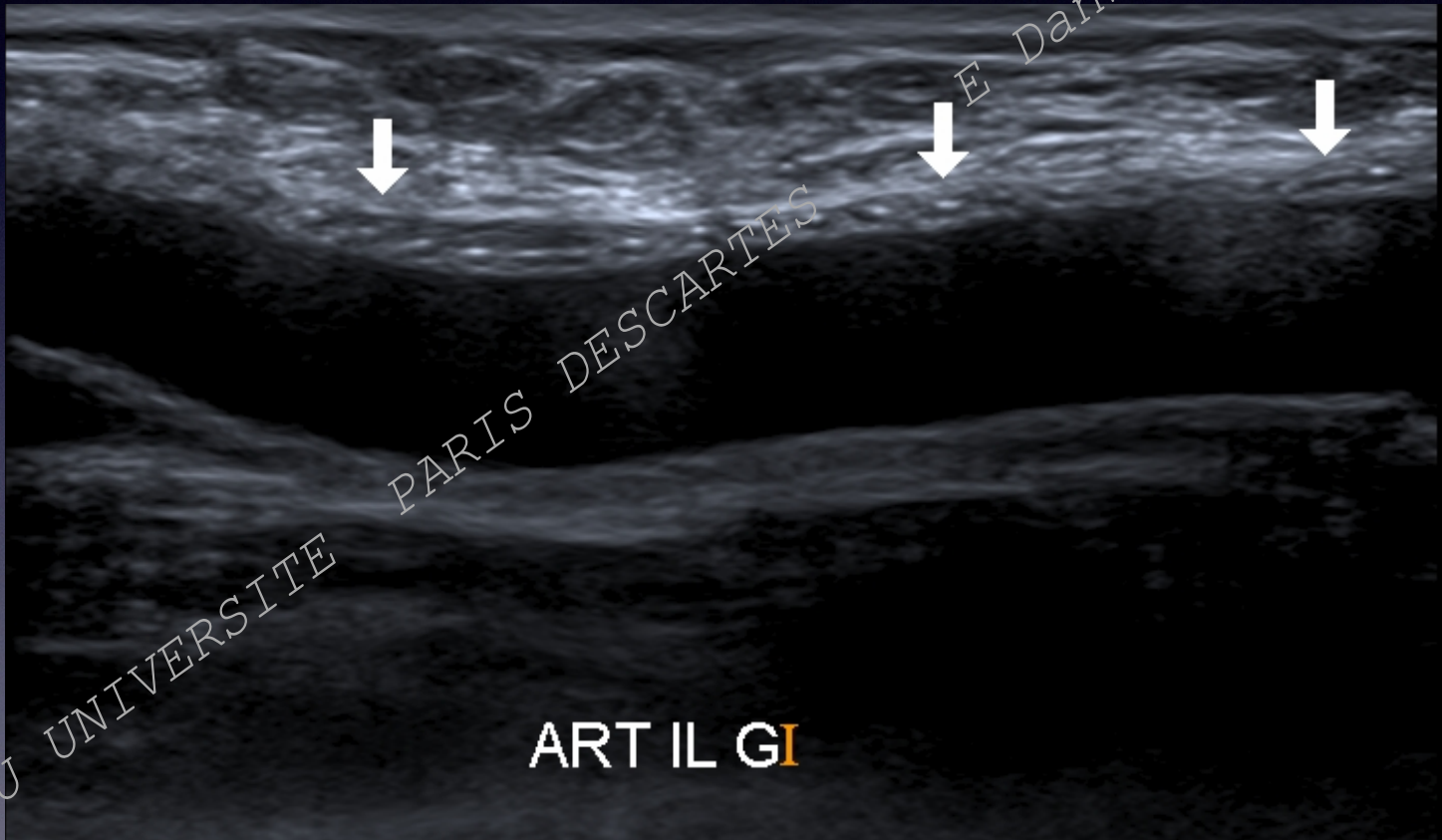


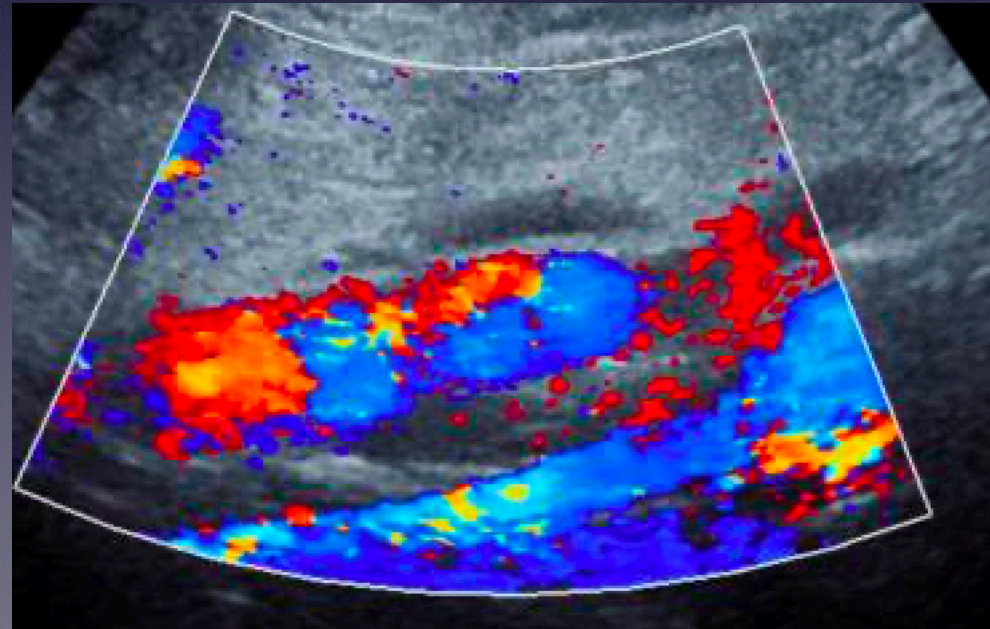
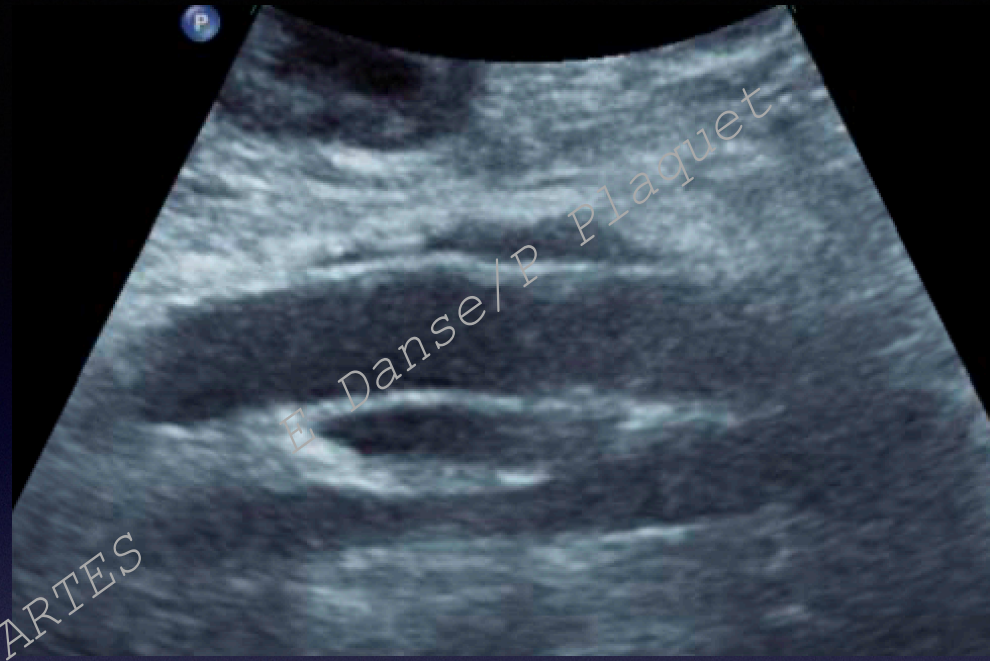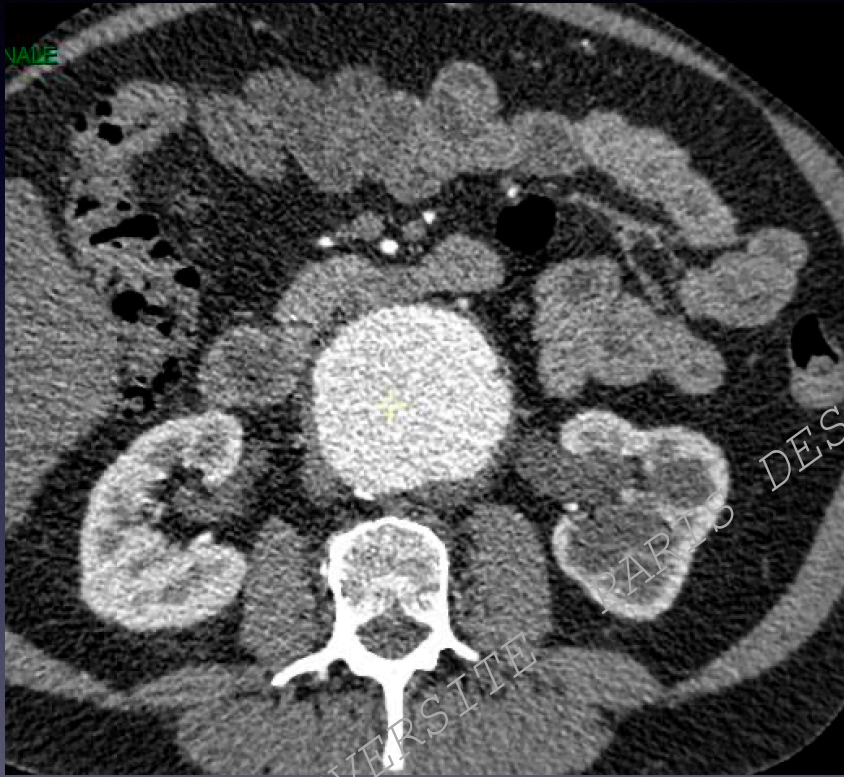
# Anévrisme aortique



Dist A	30.0 mm	Dist B	24.3 mm	Dist C	63.0 mm
Dist D	21.6 mm				

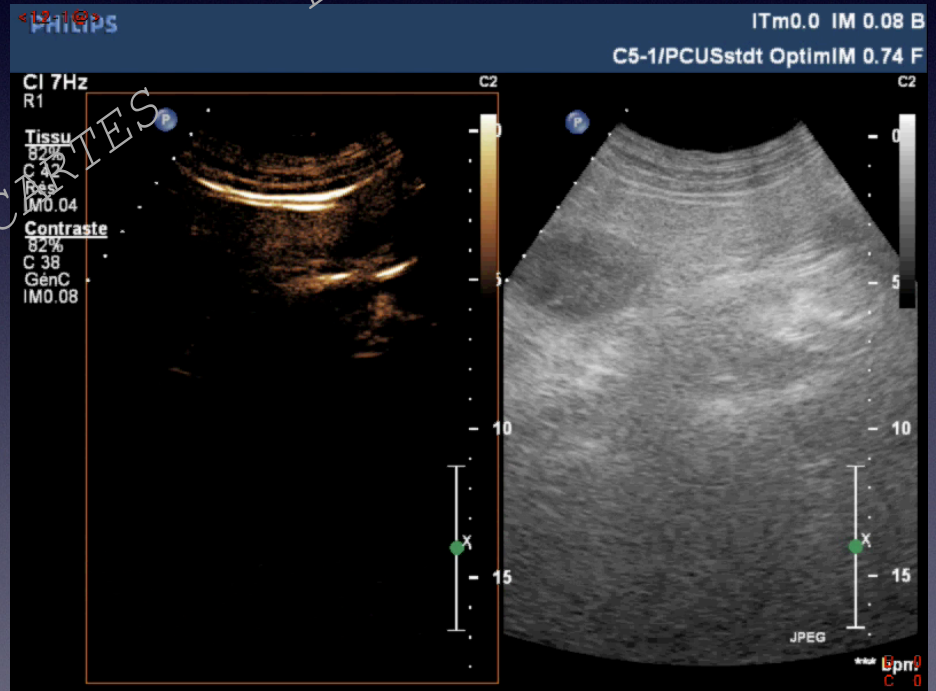
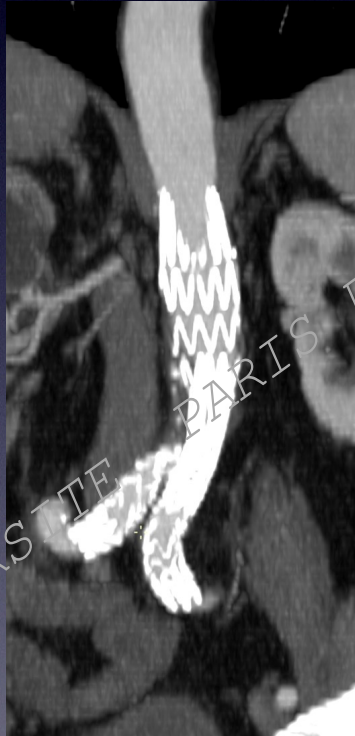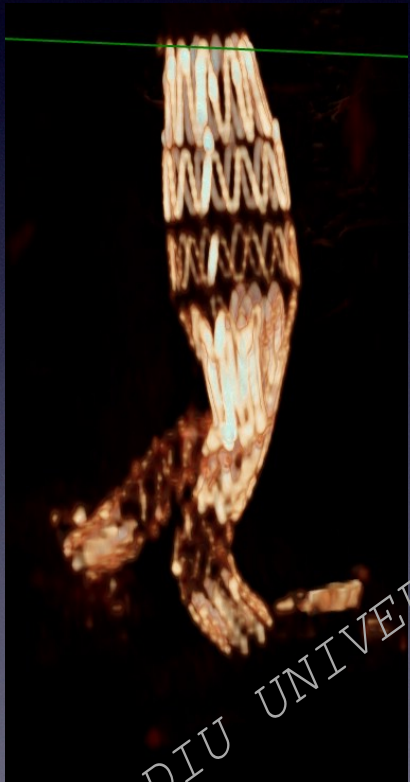
# Endoprothèse



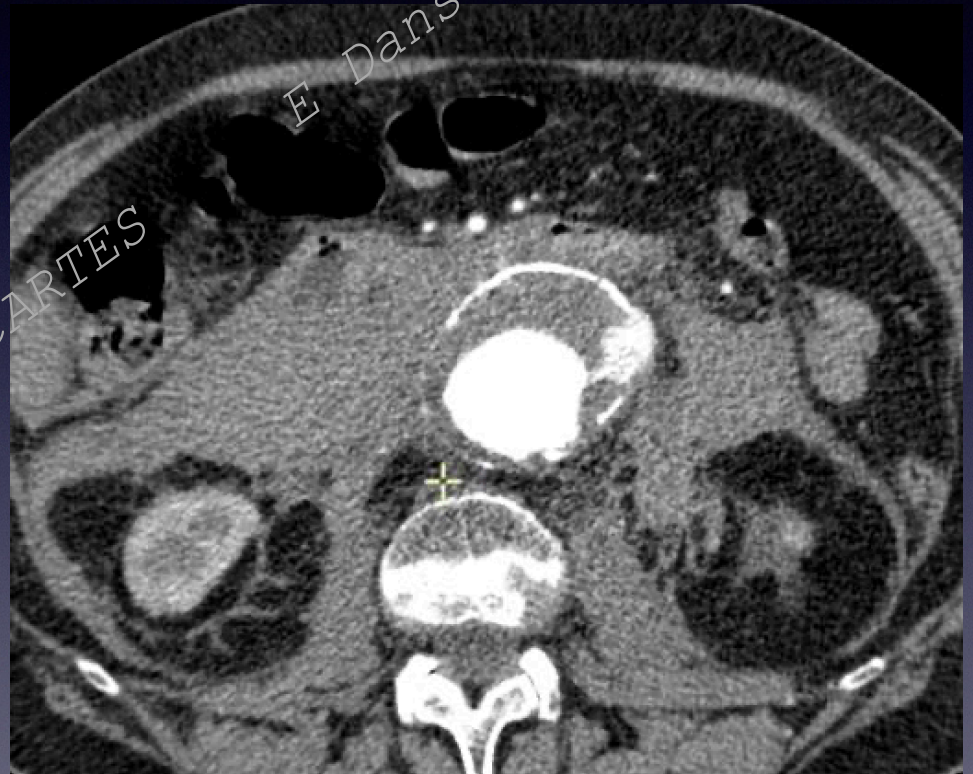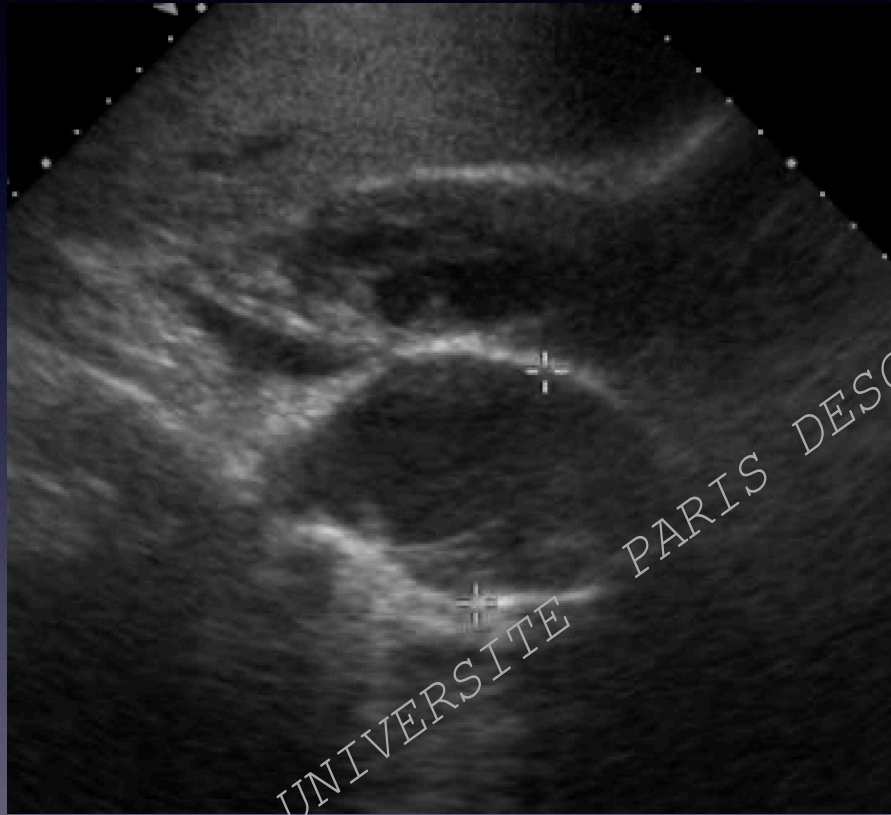


# Endoprothèse

E Danse/P Plaquet

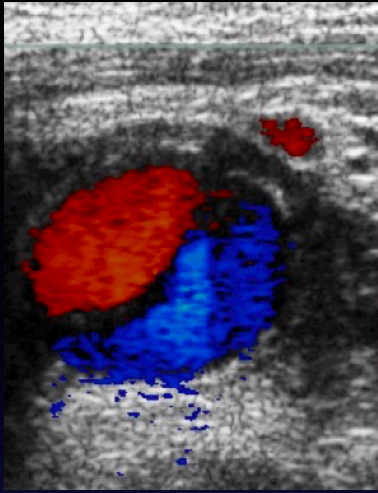






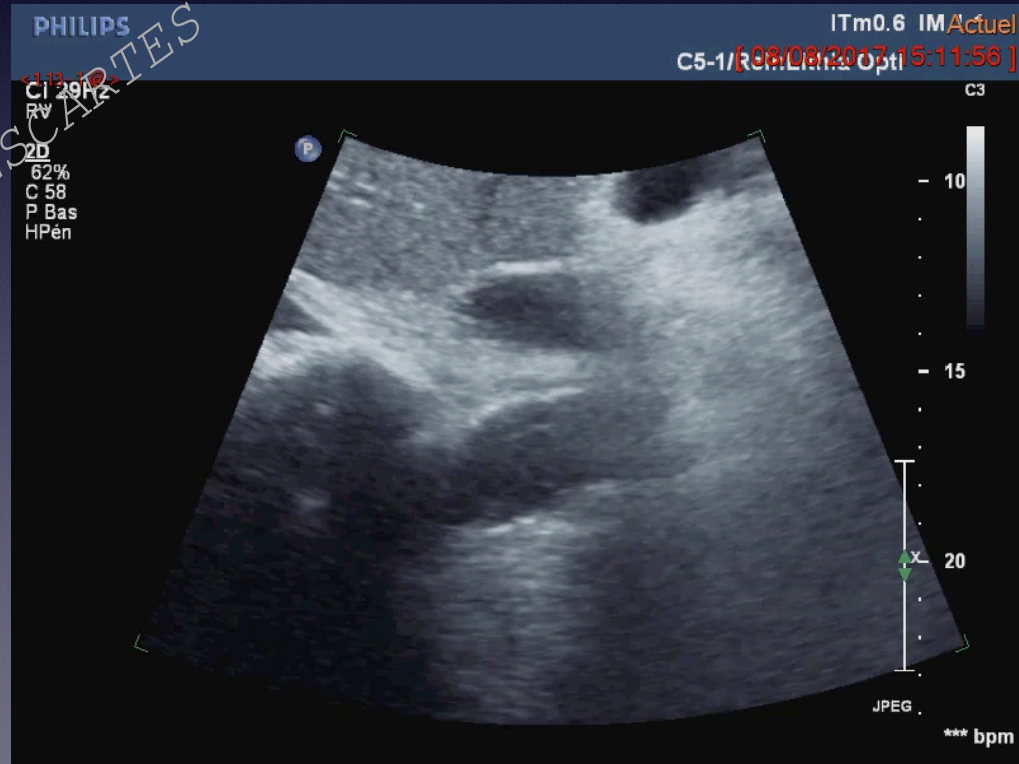
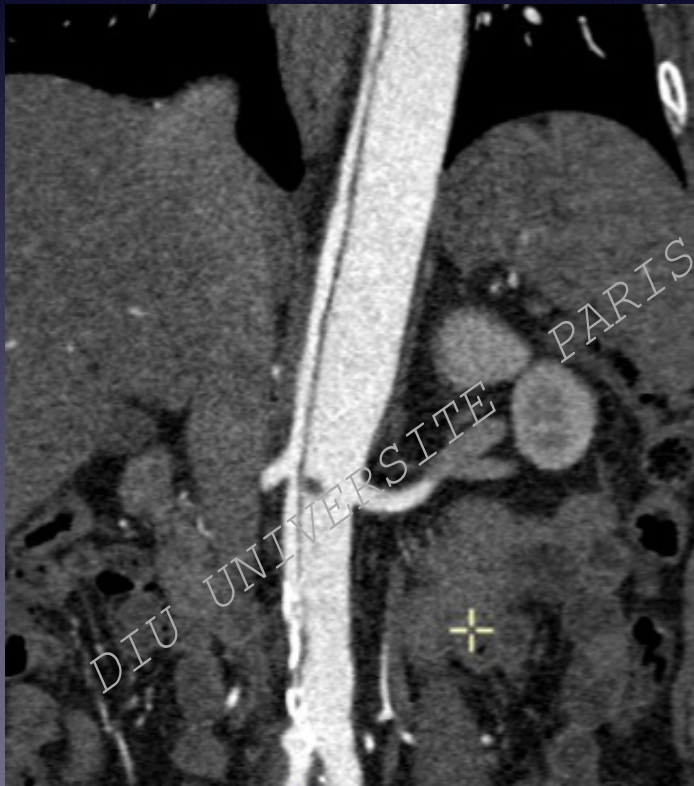DIU UNIVERSITE PARIS DESCARTES

E Danse/P Plaquet



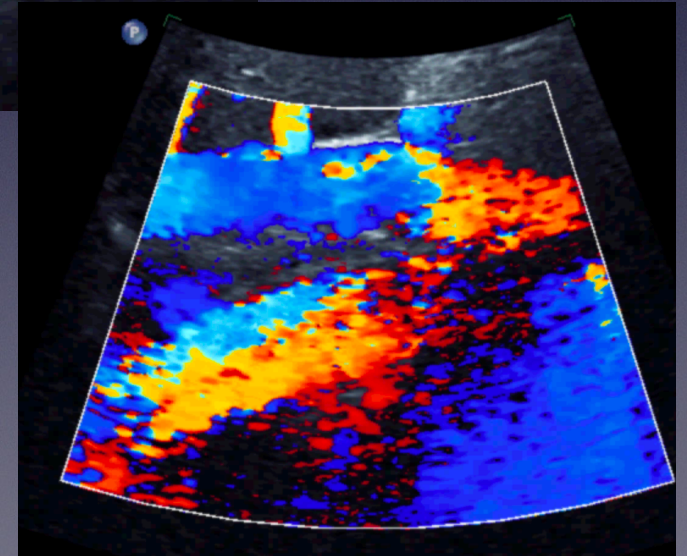
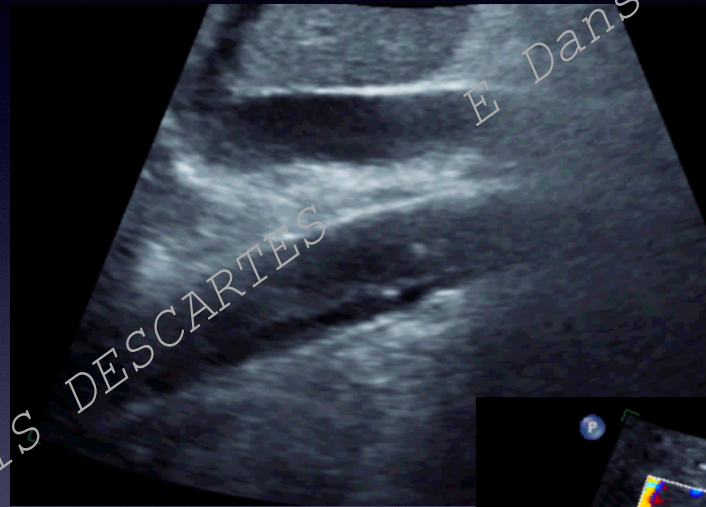
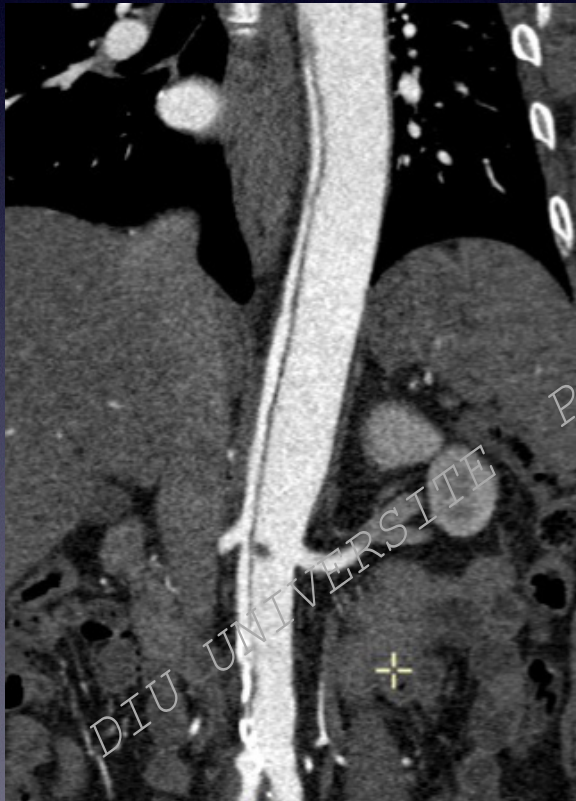# Dissection aortique

E. Danse, B. Plaquet



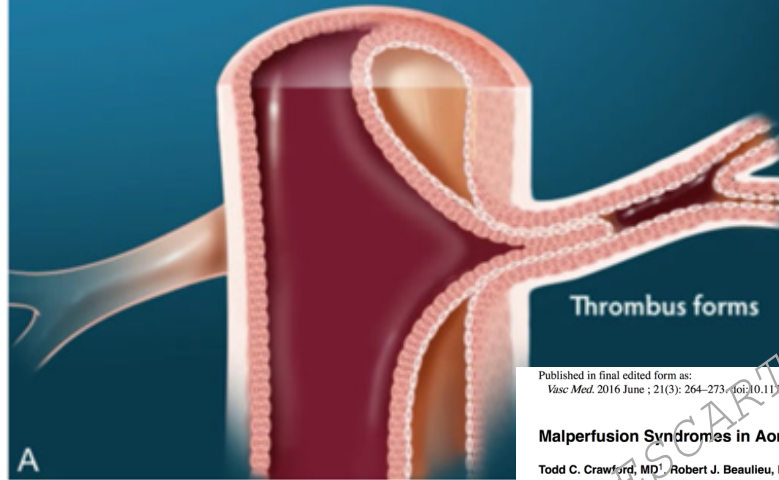
DIU UNIVERSITE PARIS DESCARTES

# Dissection aortique

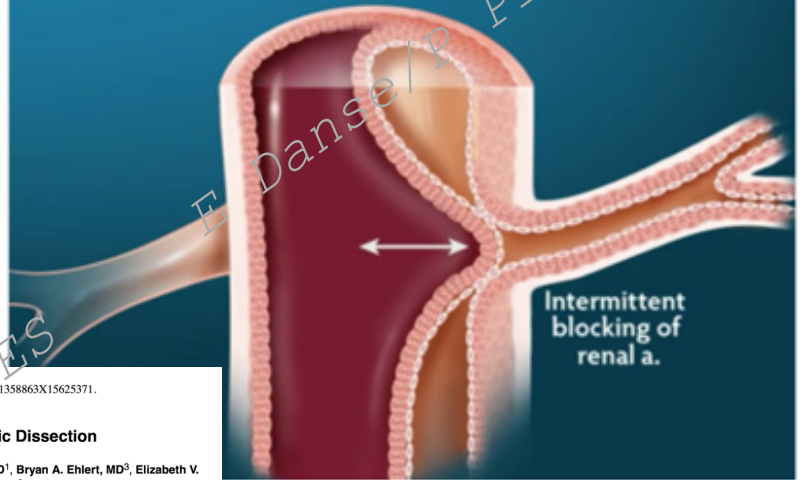


# Dissection aortique

Static



Dynamic

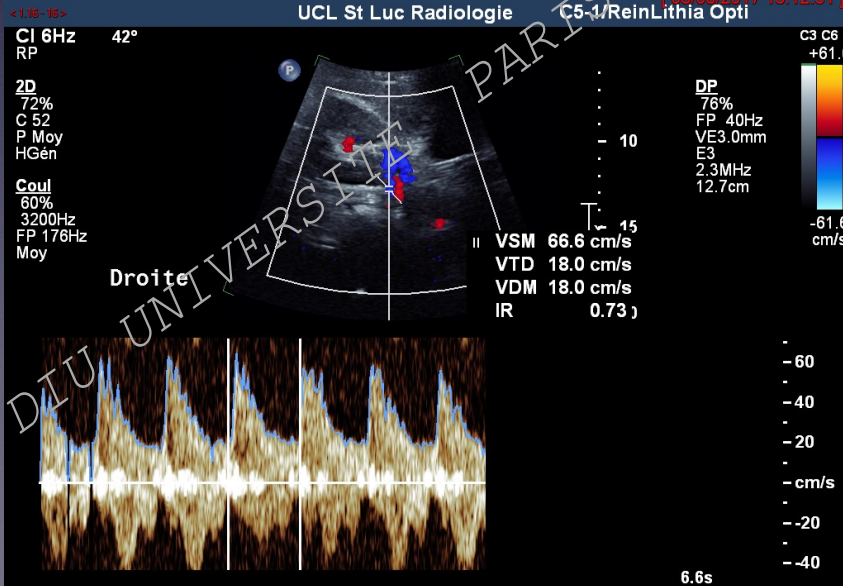


Published in final edited form as:  
*Vasc Med.* 2016 June ; 21(3): 264-273. doi:10.1177/1358863X15625371.

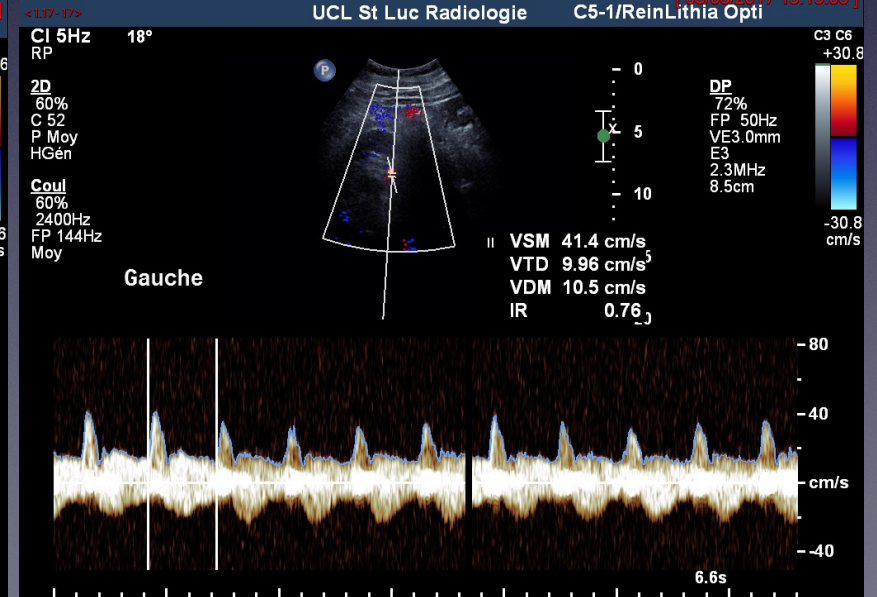
## Malperfusion Syndromes in Aortic Dissection

Todd C. Crawford, MD<sup>1</sup>, Robert J. Beaulieu, MD<sup>1</sup>, Bryan A. Ehler, MD<sup>2</sup>, Elizabeth V. Ratchford, MD<sup>3</sup>, and James H. Black III, MD, FACS<sup>4</sup>

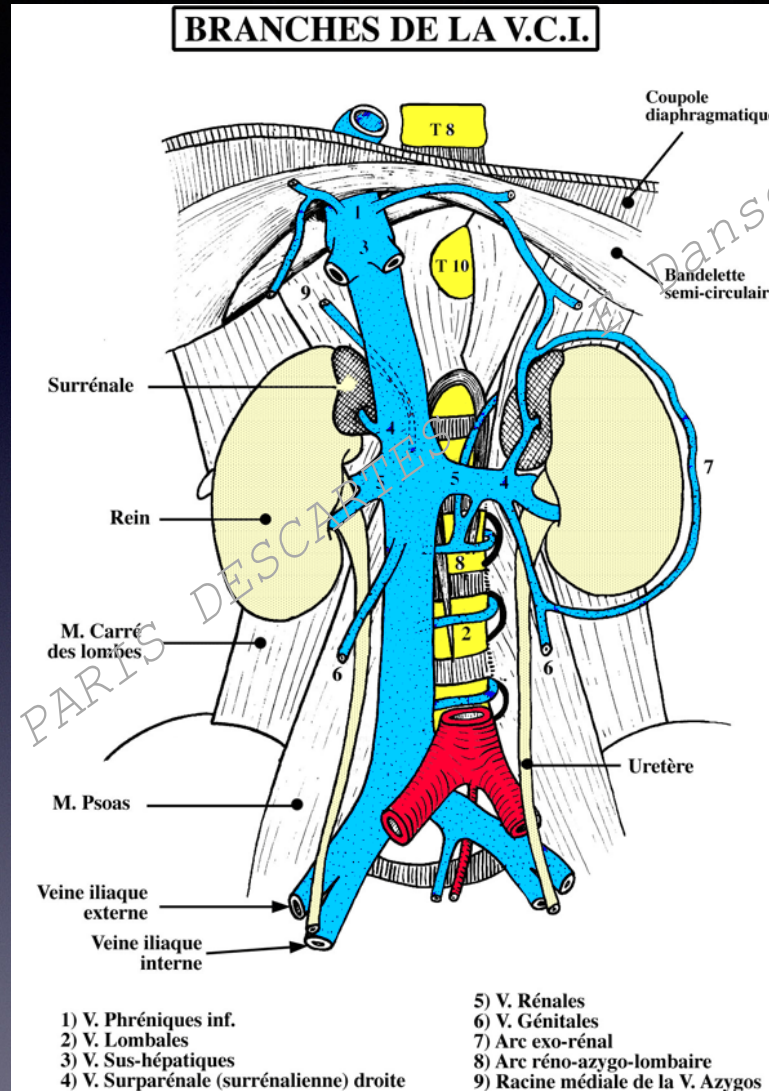
PHILIPS



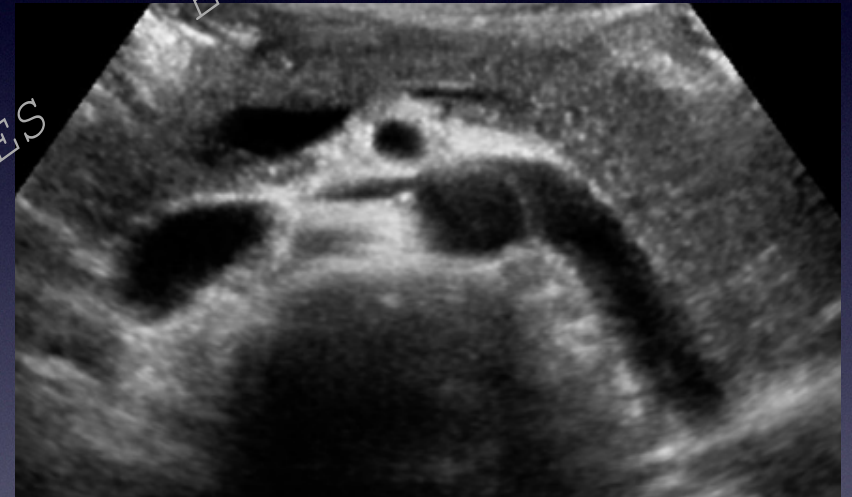
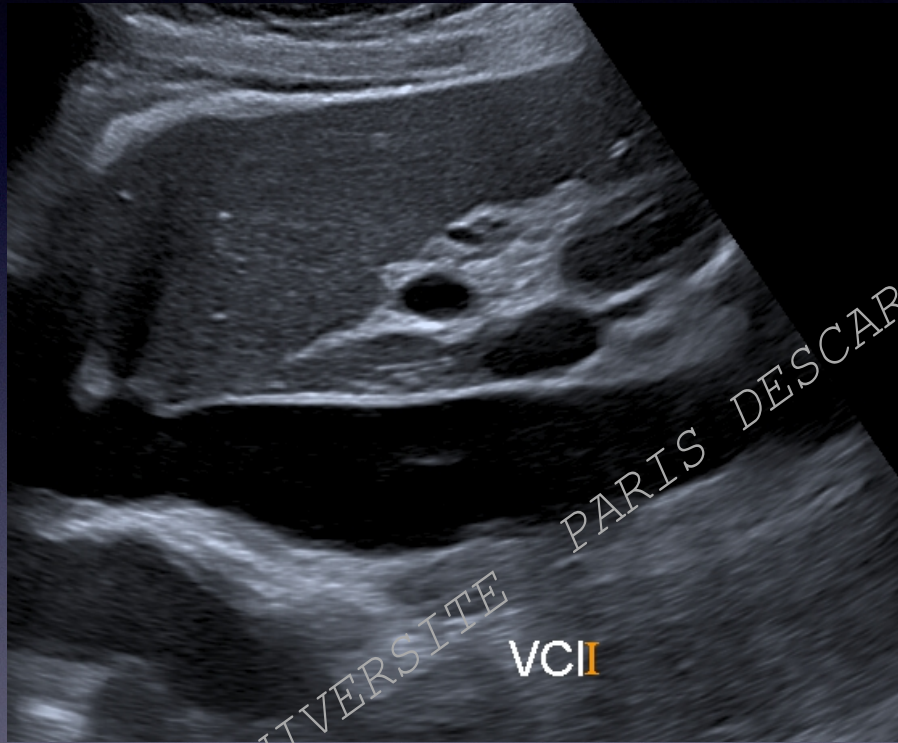
PHILIPS



# VEINE CAVE INFÉRIEURE



# VEINE CAVE INFERIEURE

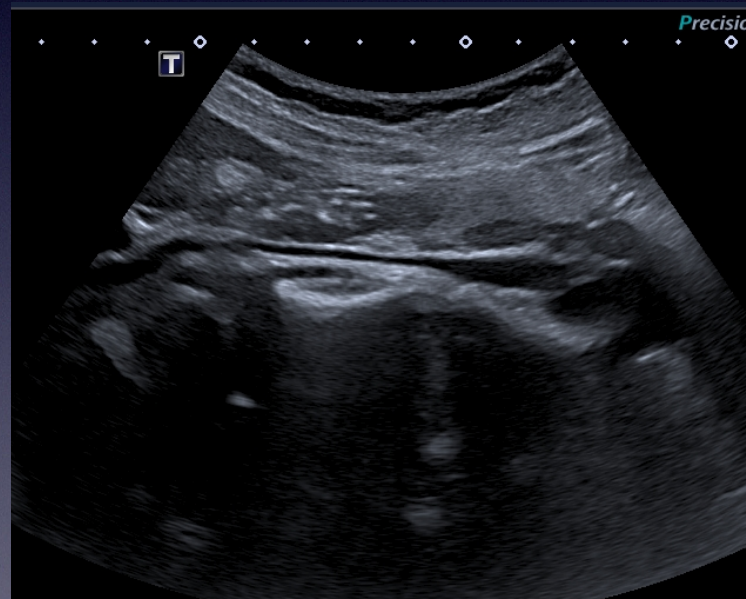
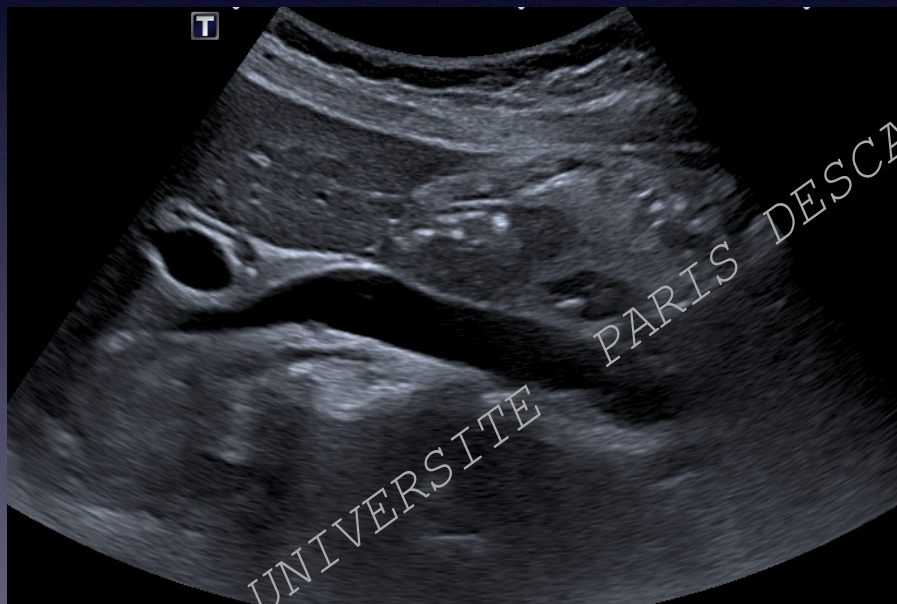


E Danse/P Plaquet

DIU UNIVERSITE PARIS DESCARTES

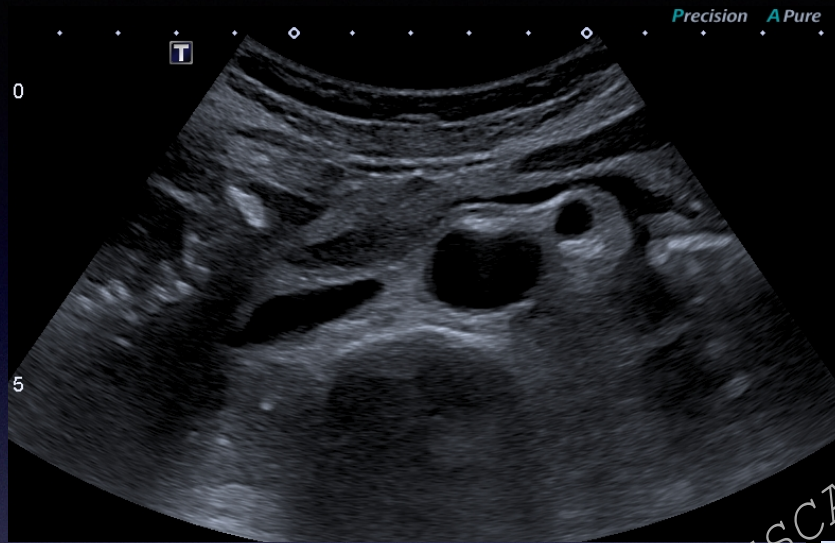
# VEINE CAVE INFÉRIEURE

E. Danse / P. Plaquet

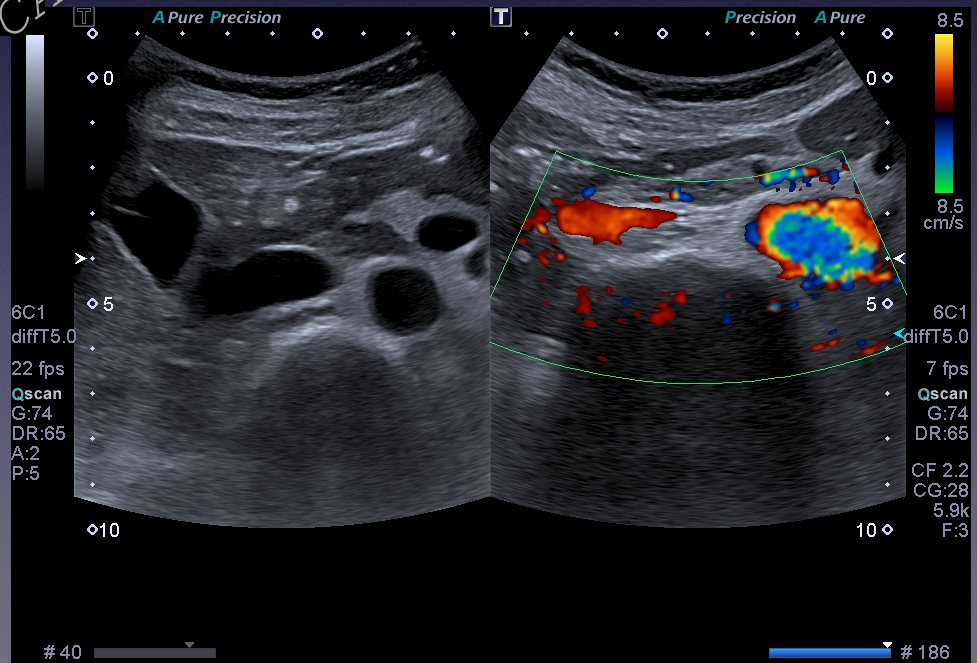


DIU UNIVERSITE PARIS DESCARTES

# VEINE CAVE INFERIEURE



E Danse/P Plaquet



DIU UNIVERSITE PARIS DESCARTES



## Normal Inferior Vena Cava: Caliber Changes Observed by Dynamic Ultrasound

Edward Grant<sup>1,2</sup>  
Franco Rendano<sup>3</sup>  
Erkan Sevinc<sup>4</sup>  
Jens Gammelgaard<sup>1</sup>  
Hans Henrick Holm<sup>1</sup>  
Sven Grönvall<sup>1</sup>

A review of the literature revealed conflicting reports on the physiologic variations of the caliber of the normal inferior vena cava as seen by sonography. In this study, 25 normal volunteers were examined using dynamic scanning, and the upper parts of their inferior vena cava were observed for changes during various phases of respiration as well as Valsalva maneuver. Optimum distension and, therefore, optimum visualization of the inferior vena cava were achieved after simple breath holding or at end expiration. Inspiration and Valsalva maneuver decreased the size of this vessel in most subjects, making it difficult to see.

**TABLE 2: Normal Inferior Vena Cava: Caliber Changes Observed by Ultrasound**

Phase of Respiration	Caliber of Inferior Vena Cava No. Patients (n = 25)		
	Increased	Decreased	No Change
Inspiration	0	25	0
End expiration	25	0	0
Breath held after full inspiration	25	0	0
<b>Valsalva maneuver:</b>			
After full inspiration:			
Men (n = 15)	0	15	0
Women (n = 10)	0	5	5
Subtotal	0	20	5
After half inspiration	0	25	0

**AJR 135:335-338, August 1980**  
0361-803X/80/1352-0335 \$00.00  
© American Roentgen Ray Society

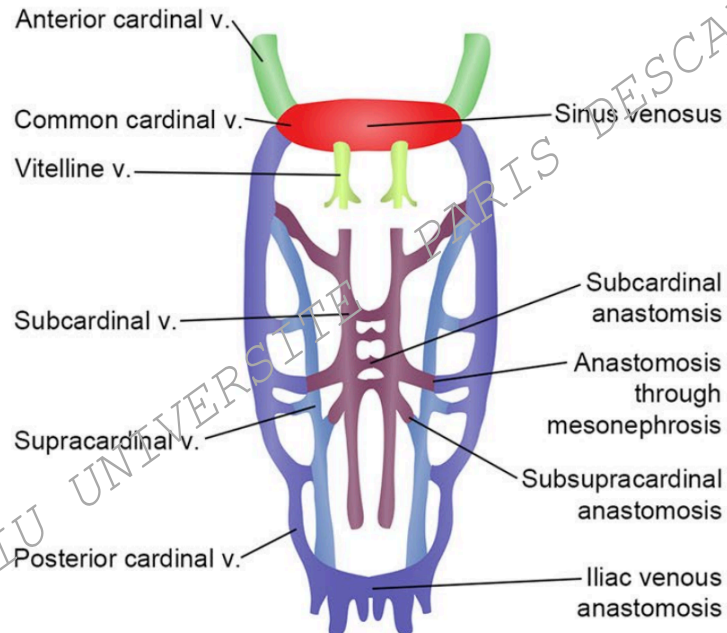


## The inferior vena cava: a pictorial review of embryology, anatomy, pathology, and interventions

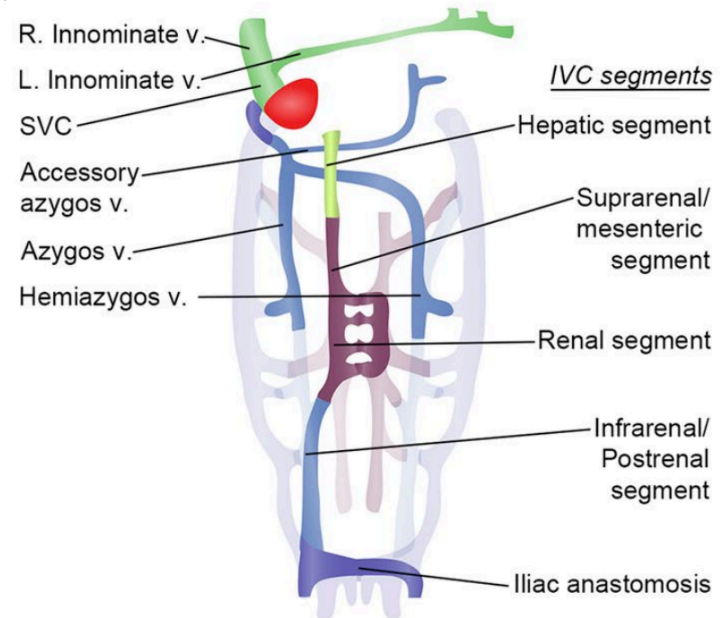
David S. Shin<sup>1</sup> · Claire K. Sandstrom<sup>1</sup> · Christopher R. Ingraham<sup>1</sup> · Eric J. Monroe<sup>1,2</sup> · Guy E. Johnson<sup>1</sup>

Published online: 1 April 2019  
© Springer Science+Business Media, LLC, part of Springer Nature 2019

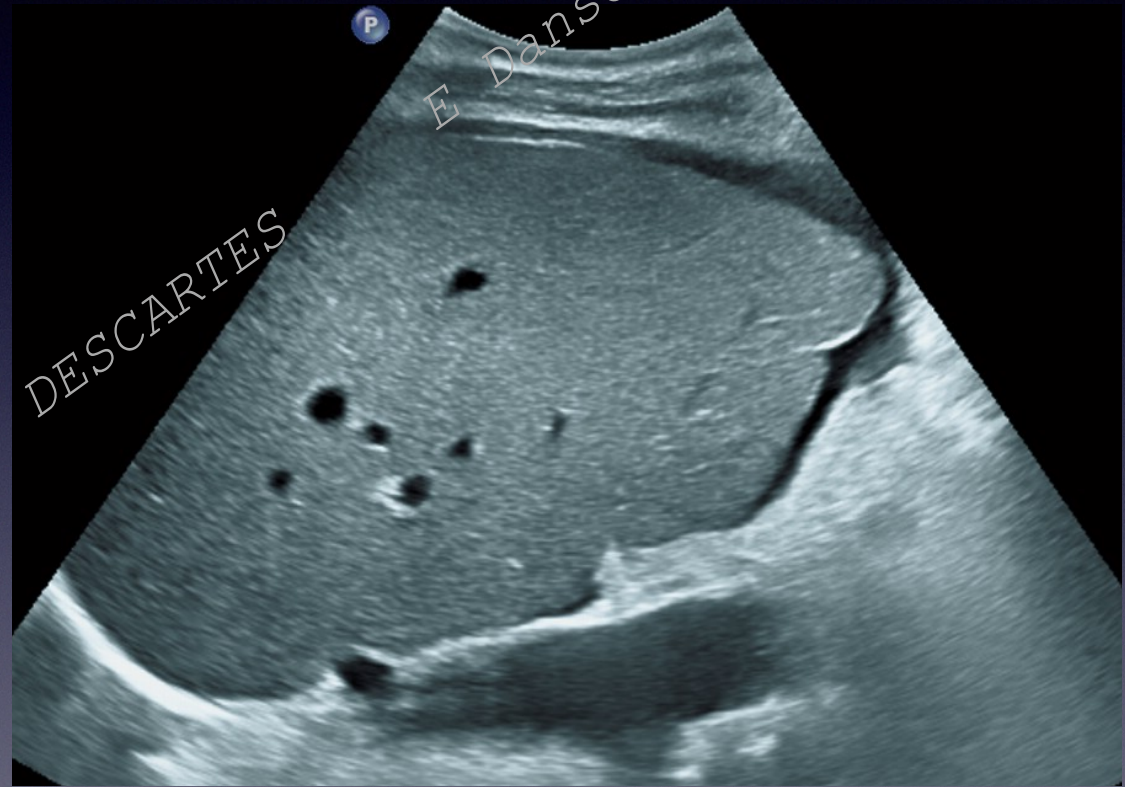
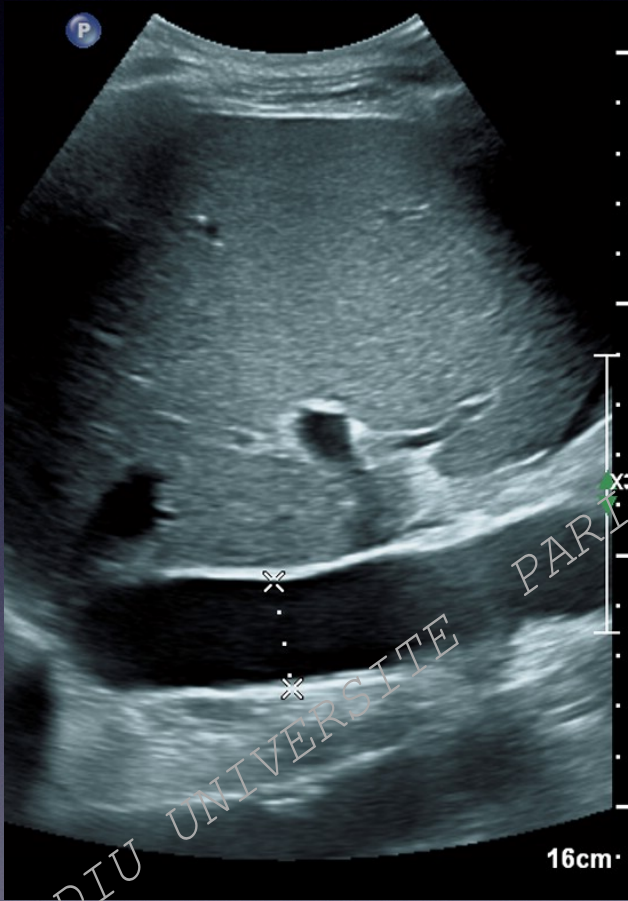
**A**



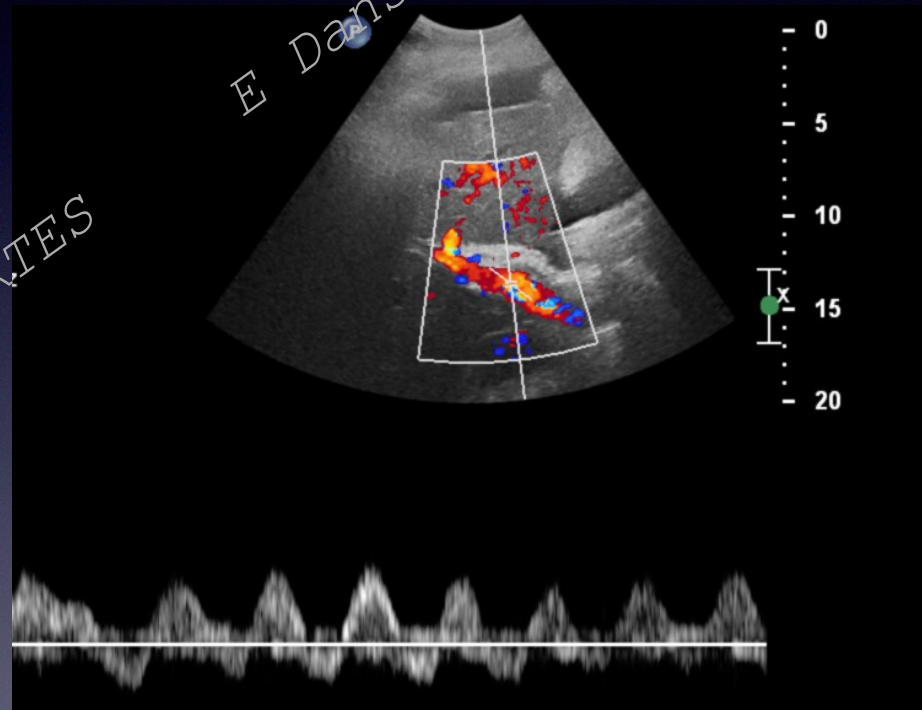
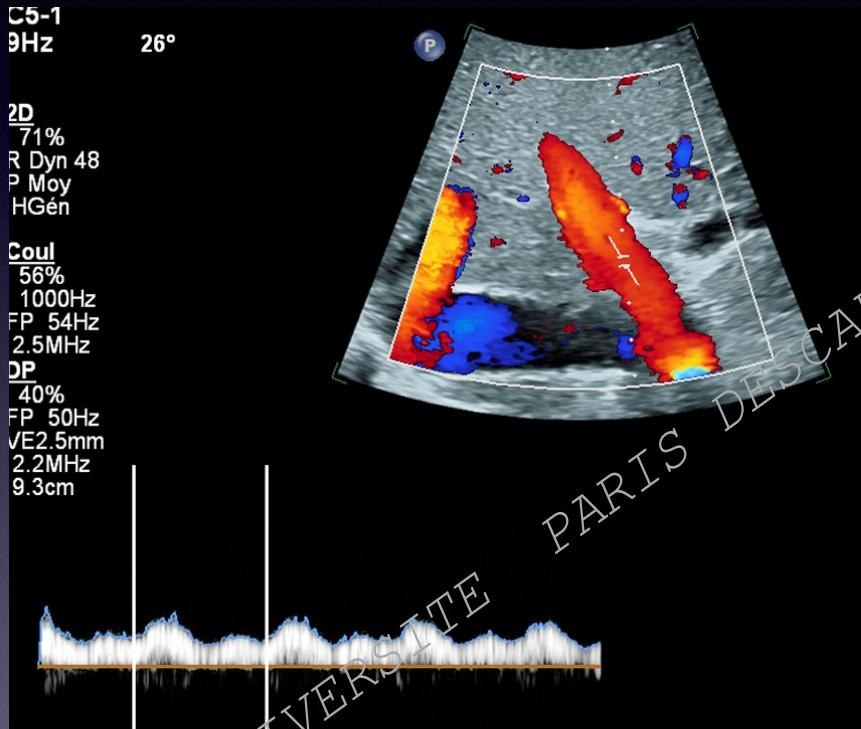
**B**



# Foie cardiaque



# Foie cardiaque



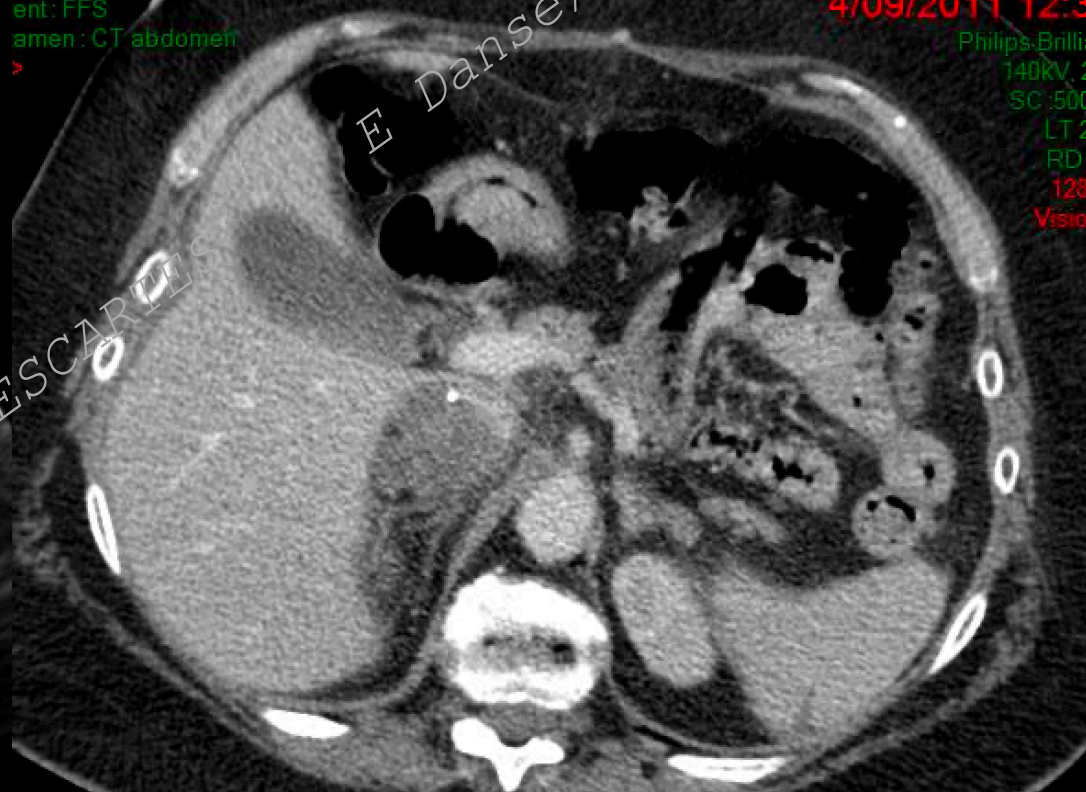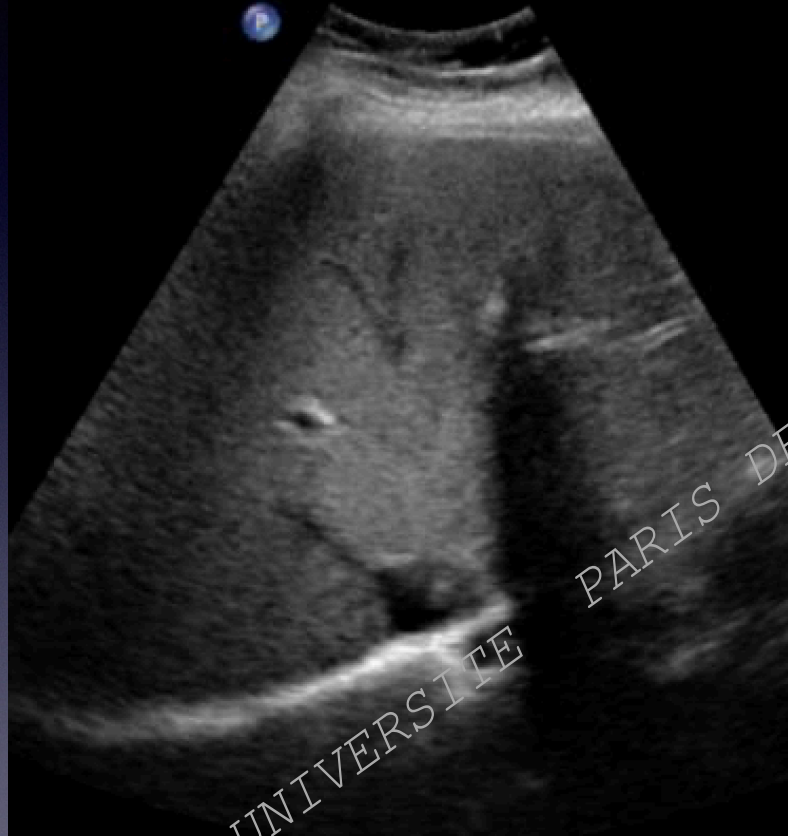eaux thorax/a...

8

ent: FFS  
amen: CT abdomen

4/09/2011 12:3

Philips Brilliance  
140kV, 2  
SC: 500  
LT 2  
RD  
128  
Visio

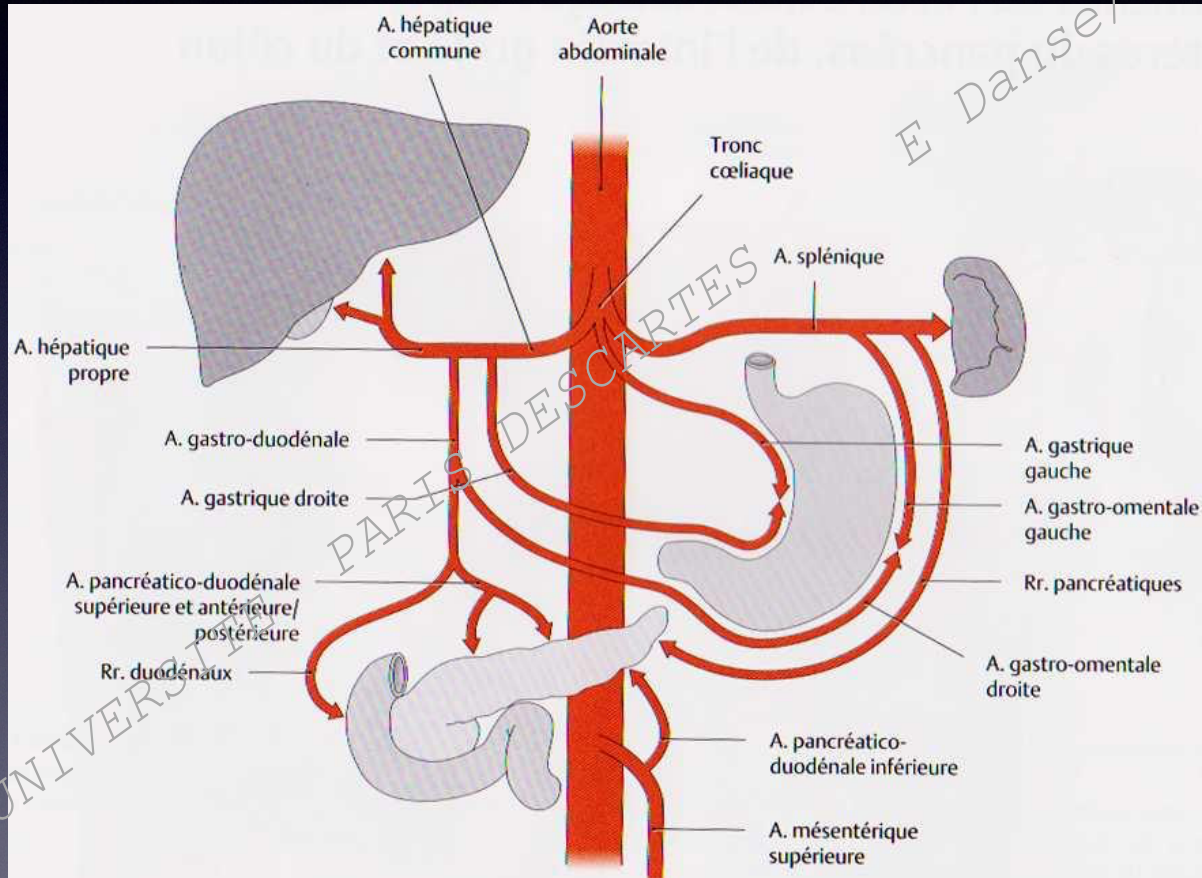


DIU UNIVERSITE

PARIS DESCARTES

E Danse/P Plaquet

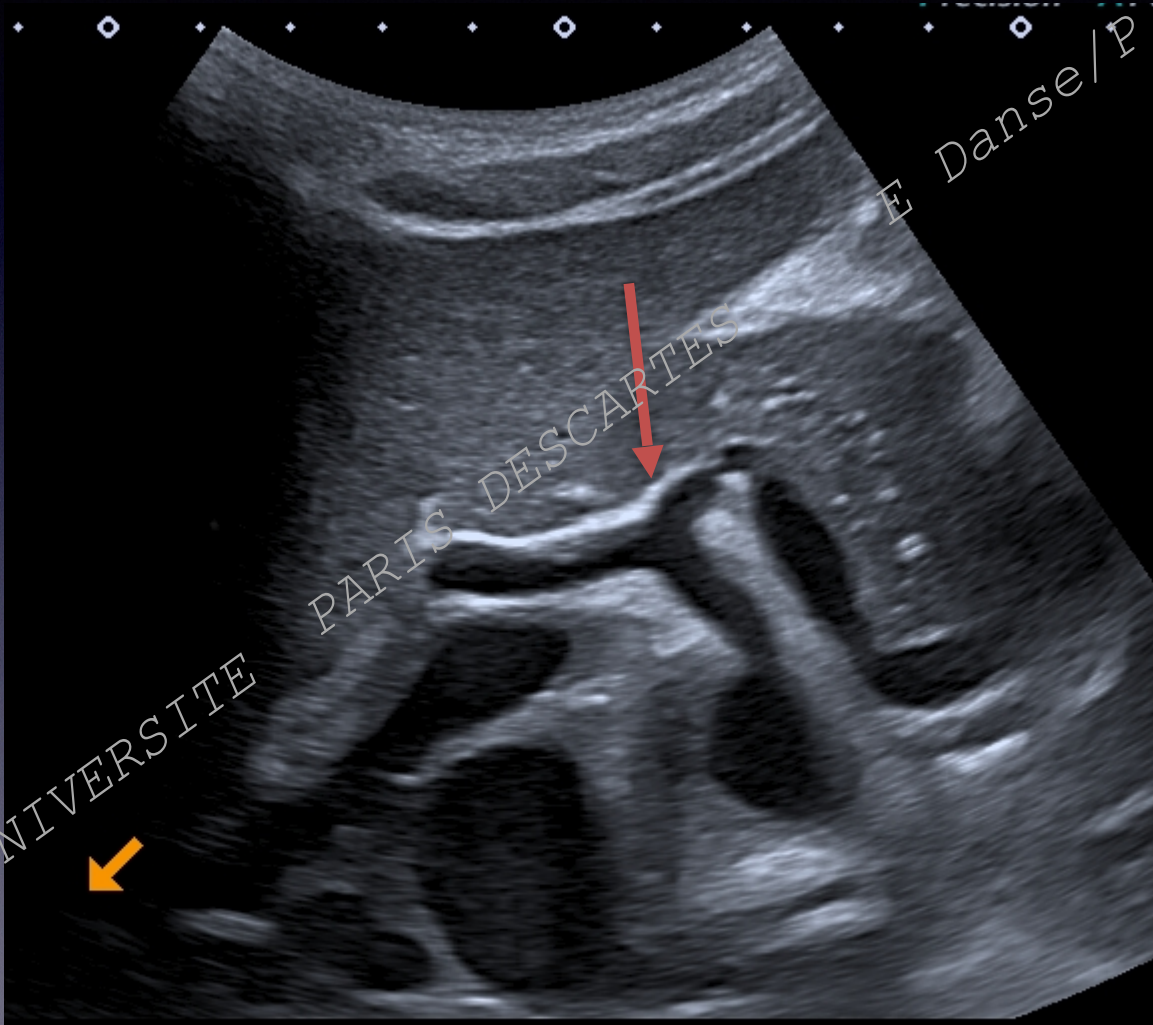
# Echo-anatomie des gros vaisseaux abdominaux



E. Danse/P. Plaguet

DIU UNIVERSITÉ PARIS DESCARTES

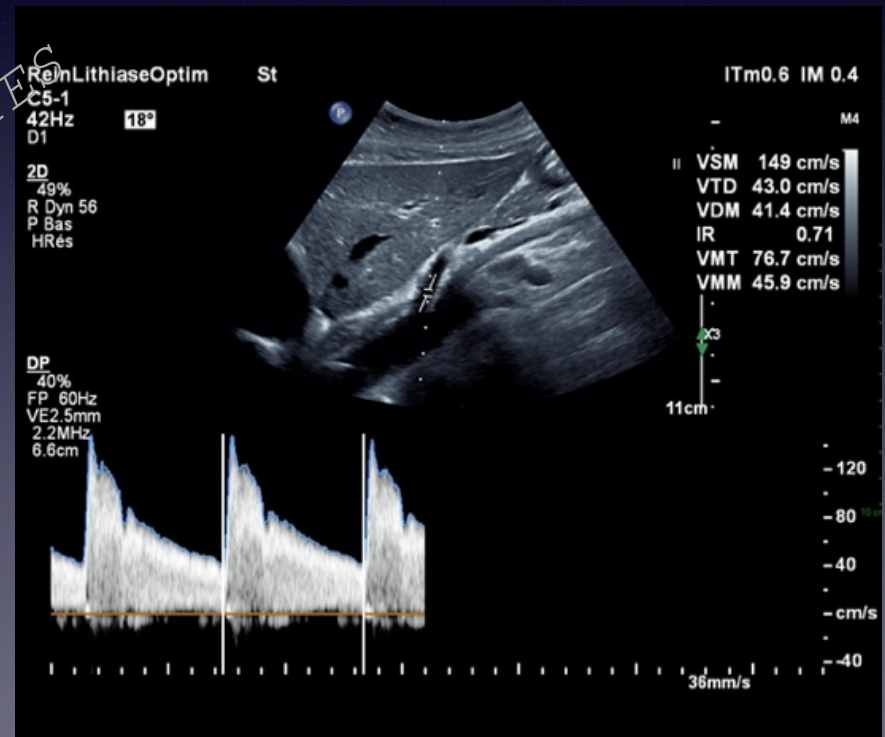
# Tronc coeliaque



# Tronc coeliaque

E. Danse / P. Plaquet

Diamètre normal : < 6 mm  
Pic systolique 100 - 200 cm/s  
IR 0,56 - 0,80

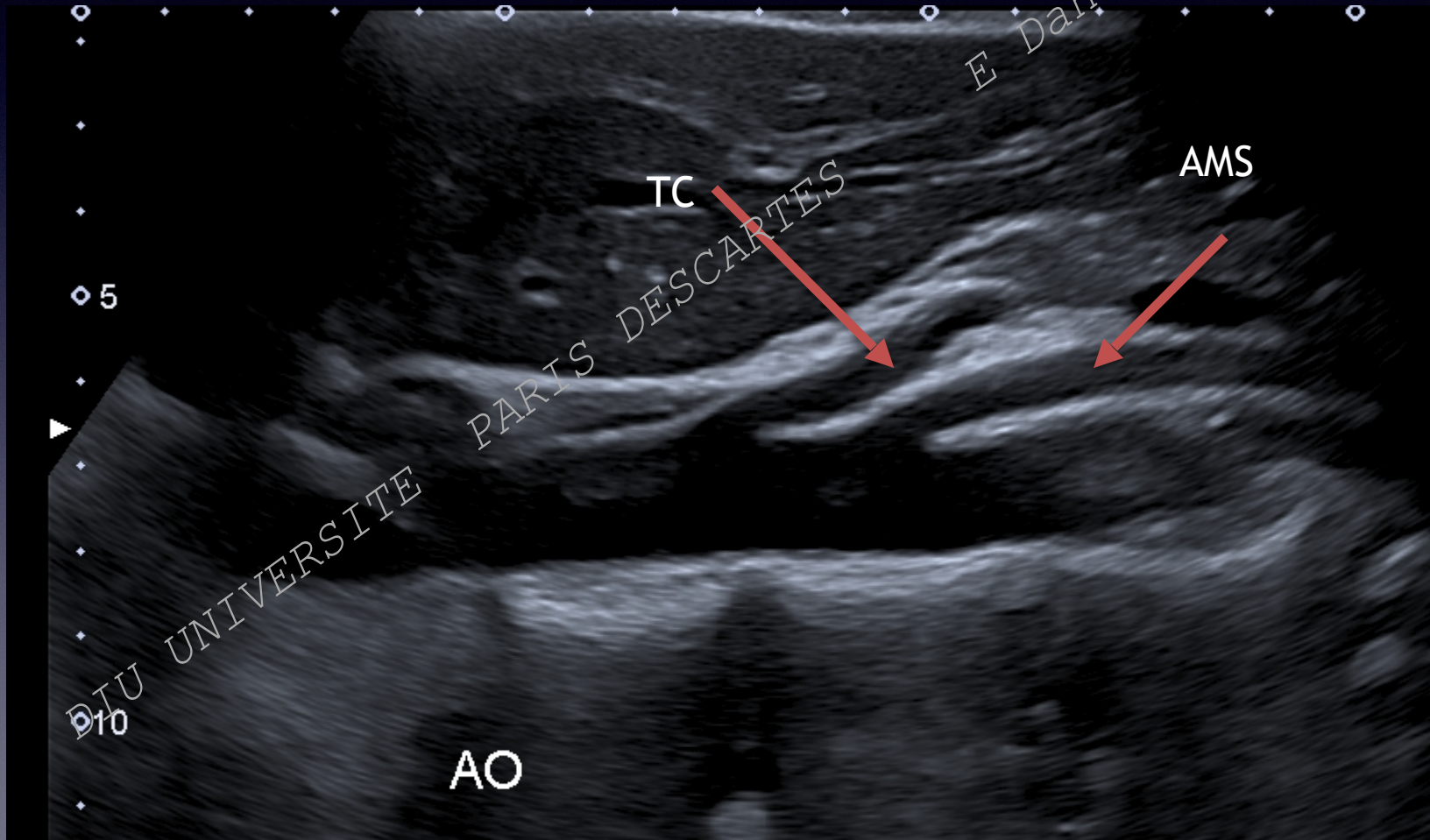


DIU UNIVERSITÉ PARIS DESCARTES

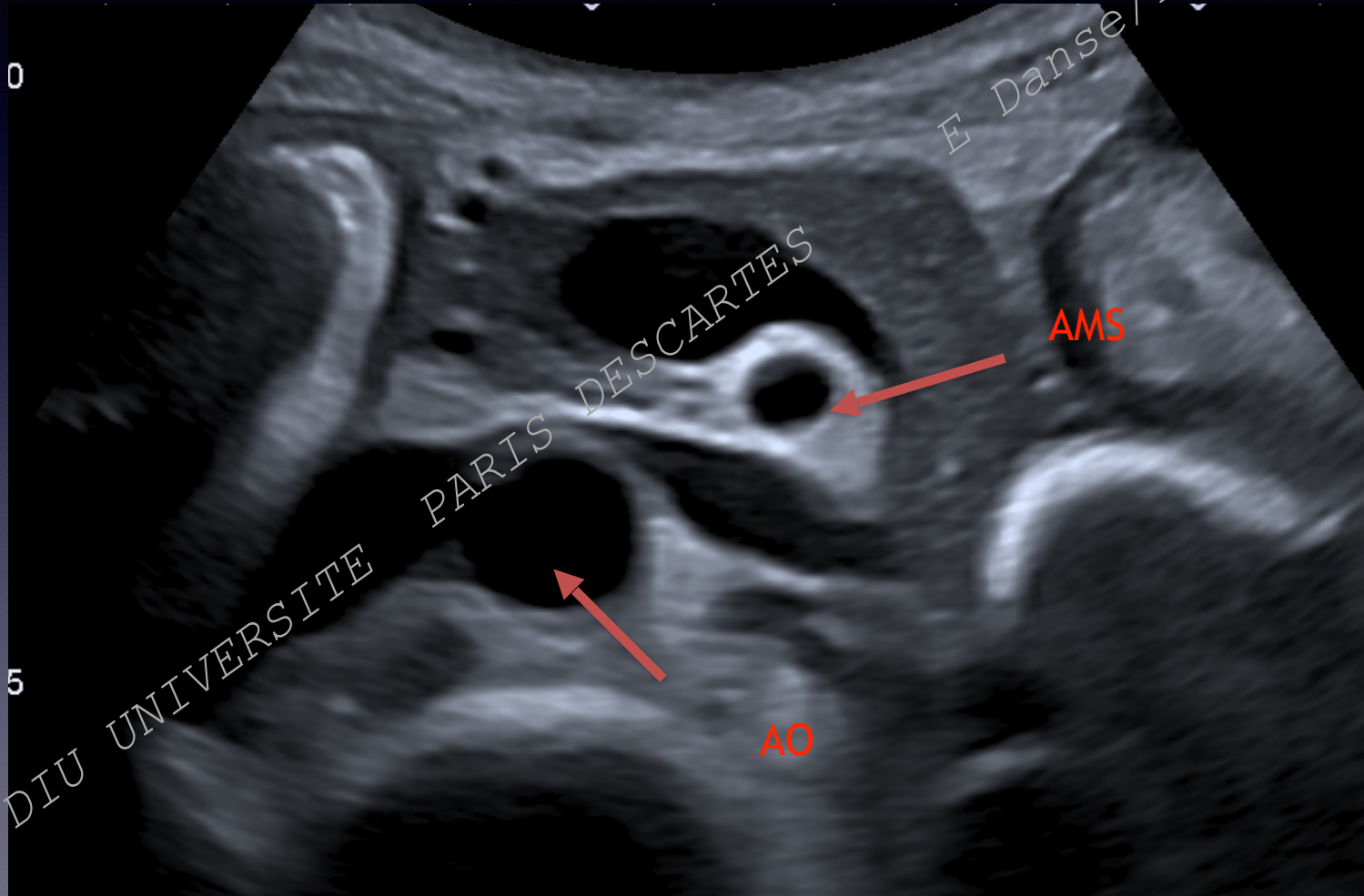


Tronc coeliaque

Artère mésentérique supérieure

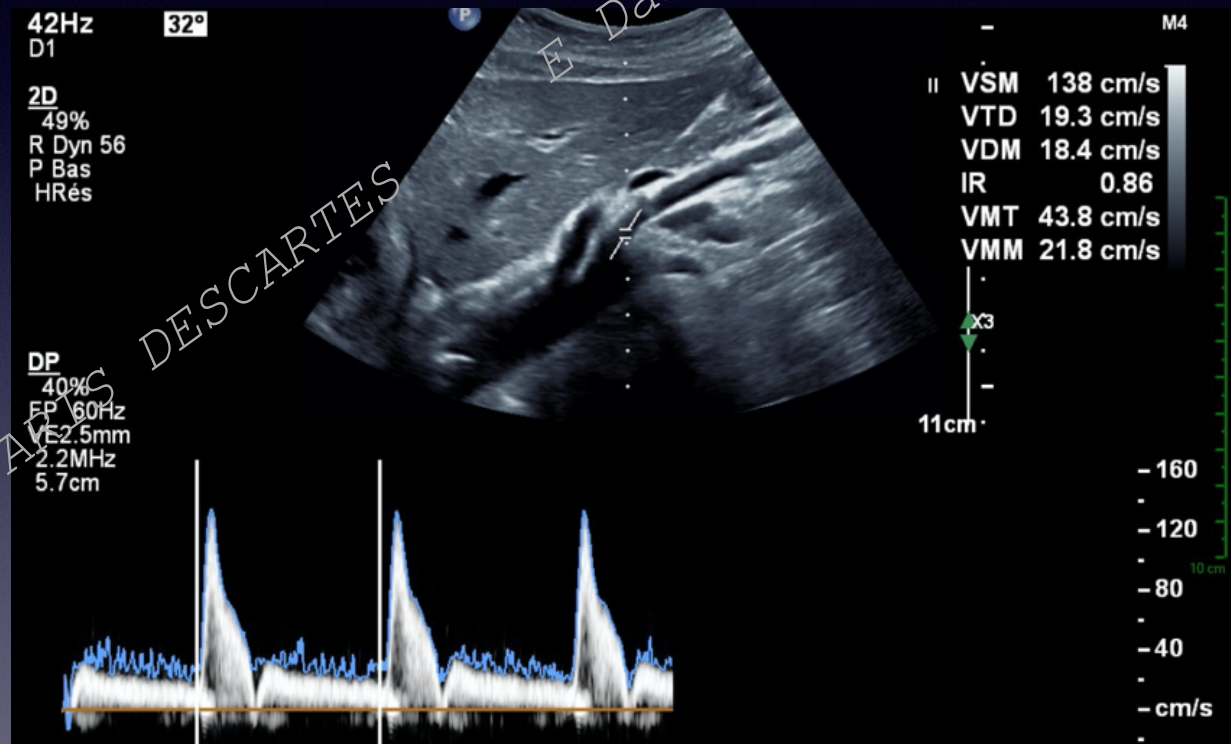


# Artère mésentérique supérieure

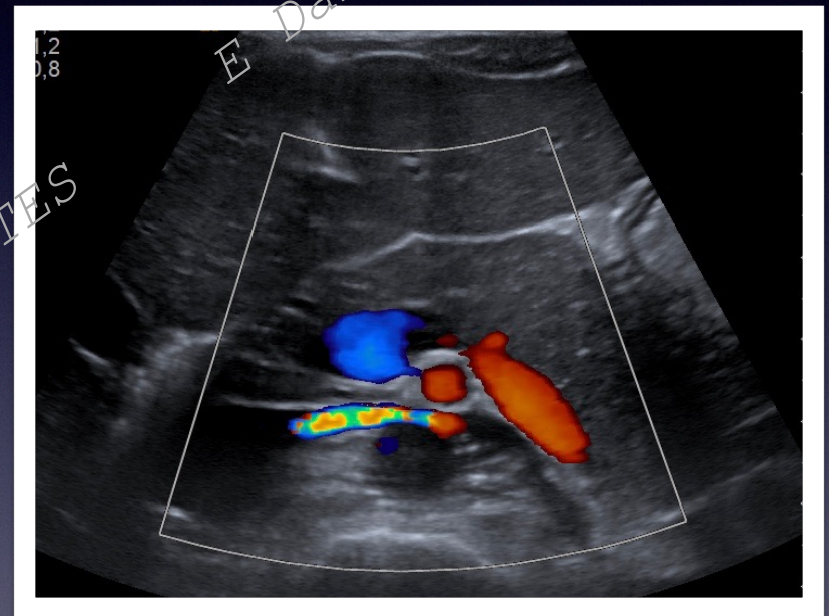
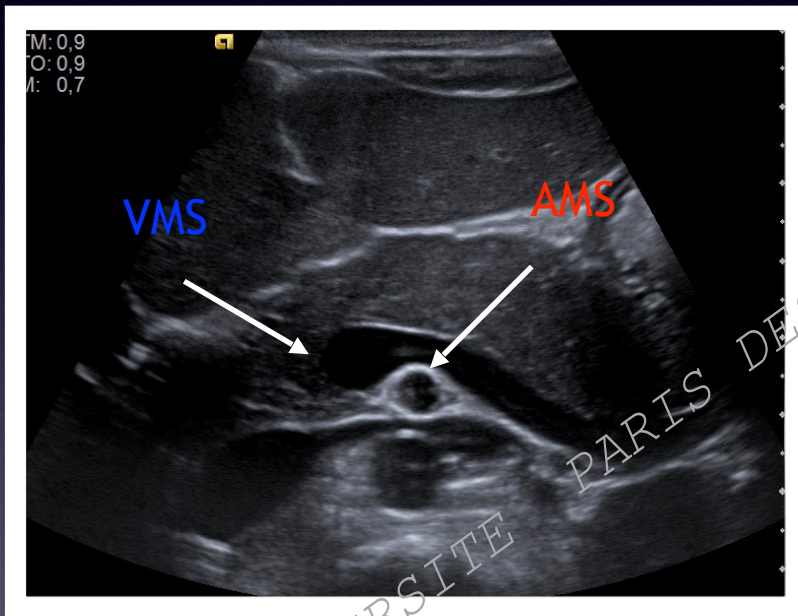


# Artère mésentérique supérieure

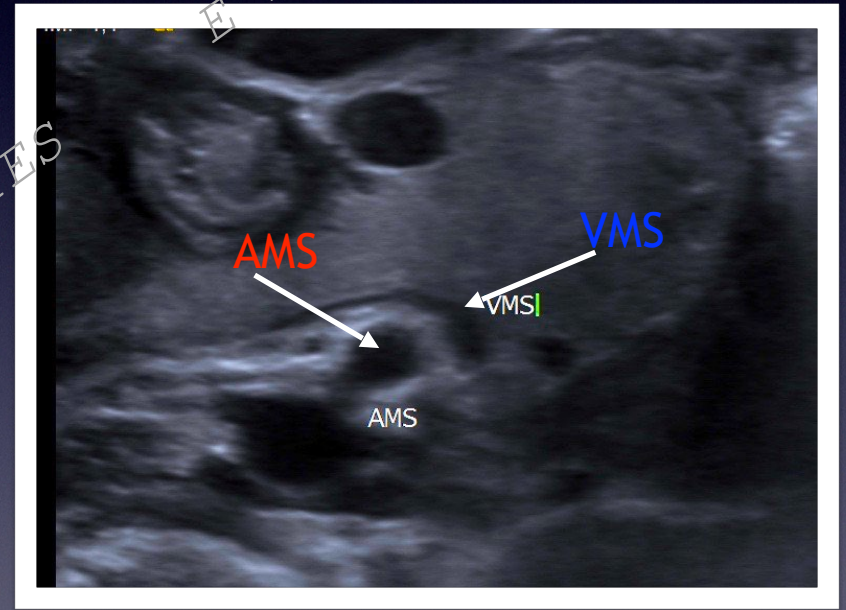
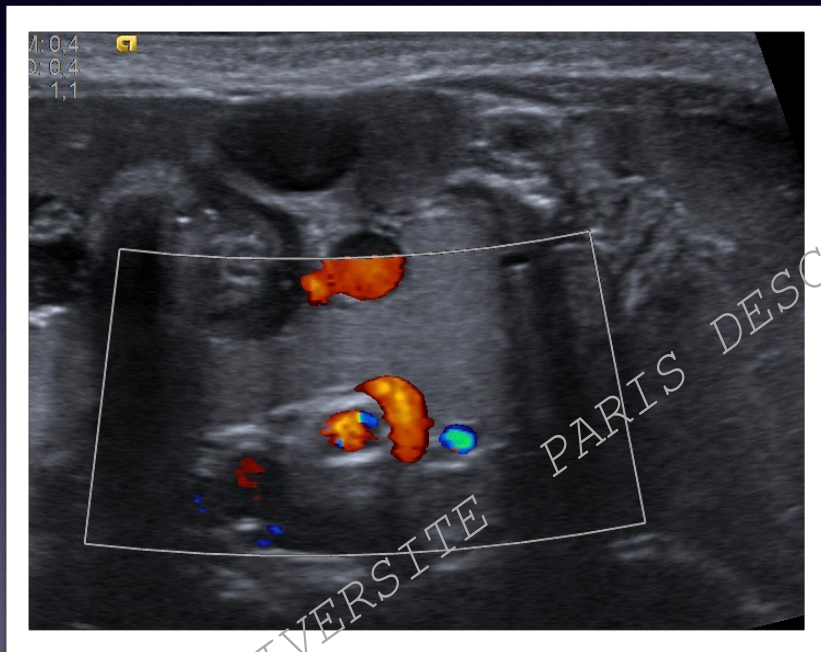
10 - 25 mm sous  
le TC  
Diamètre < 6mm  
Pic syst 125-180  
cm/s



# Artère et veine mésentériques supérieures



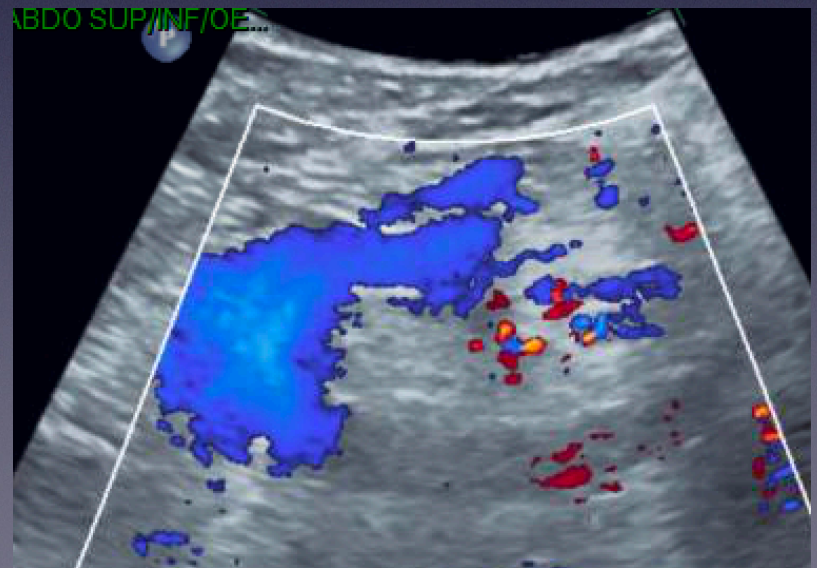
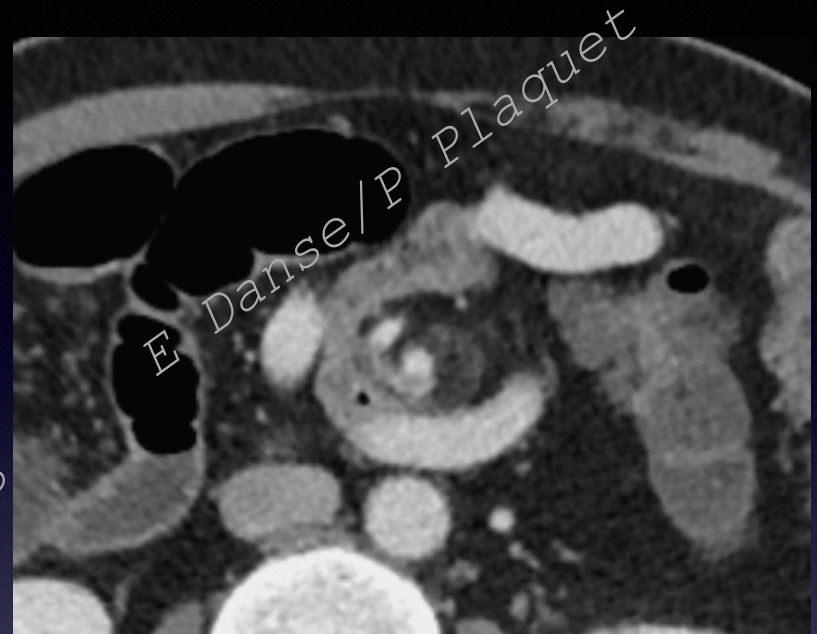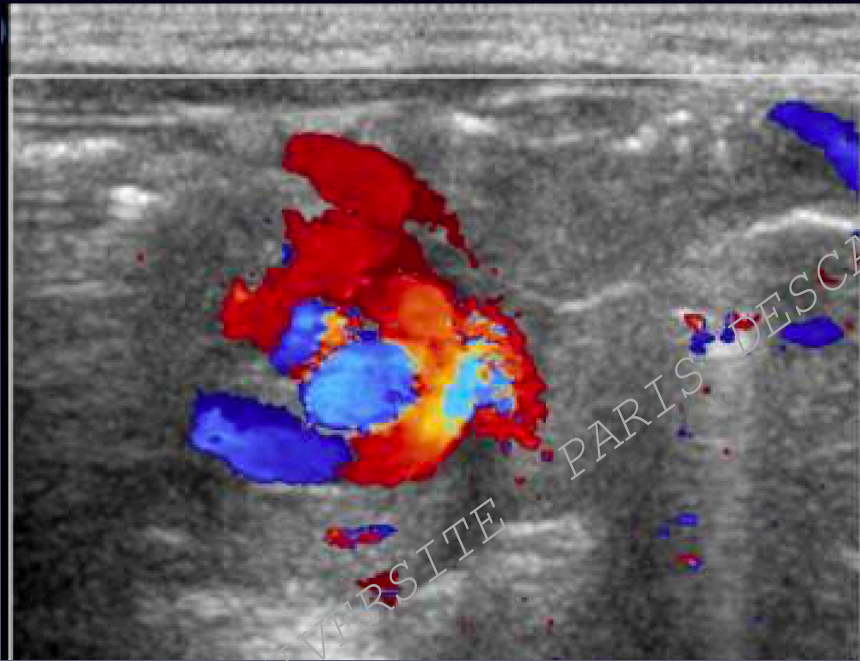
# Artère et veine mésentériques supérieures



E Danse/P Plaquet

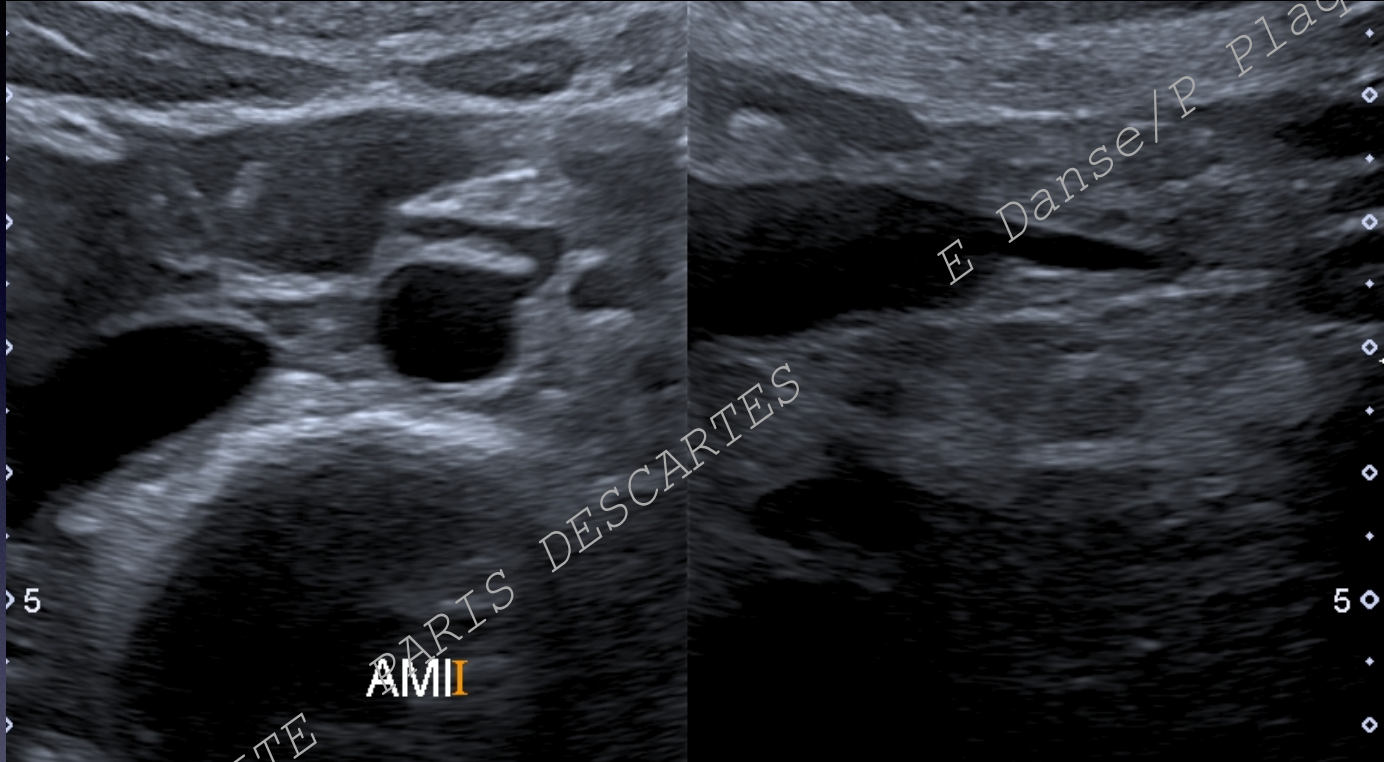
DIU UNIVERSITE PARIS DESCARTES

Volvulus sur malrotation => enfant ...=> adulte



DIU UNIVERSITE PARIS DESCARTES

# Artère mésentérique inférieure

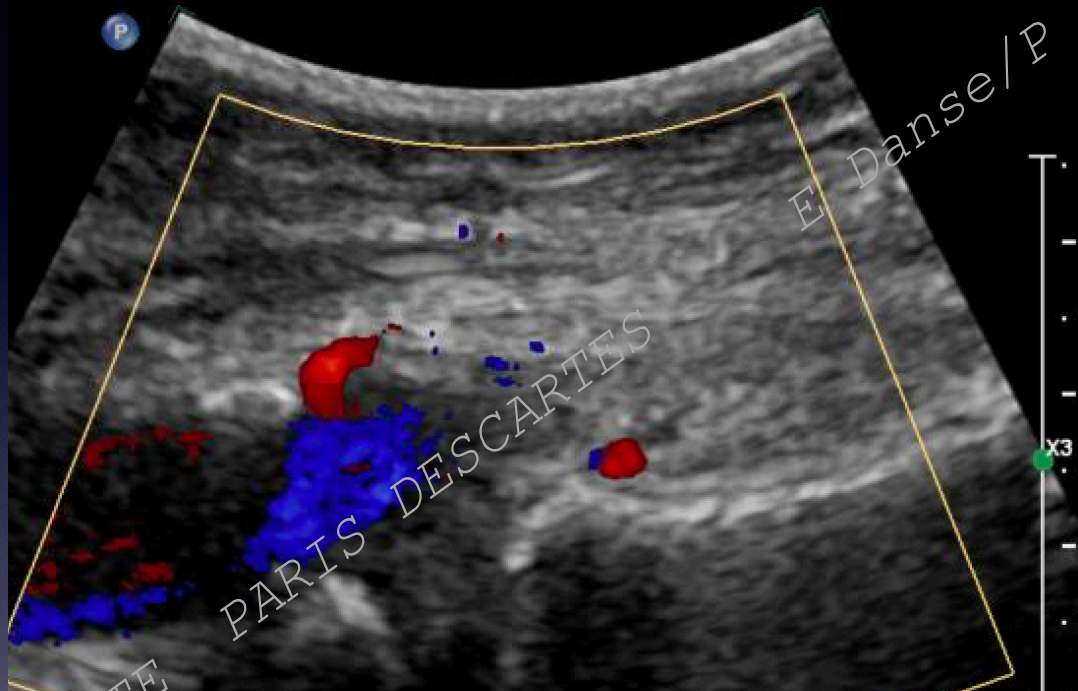


3 à 6 cm de la bifurcation

Diamètre 3 à 6 mm

Flux triphasique pic syst  $< 120$  cm/s

# Artère mésentérique inférieure



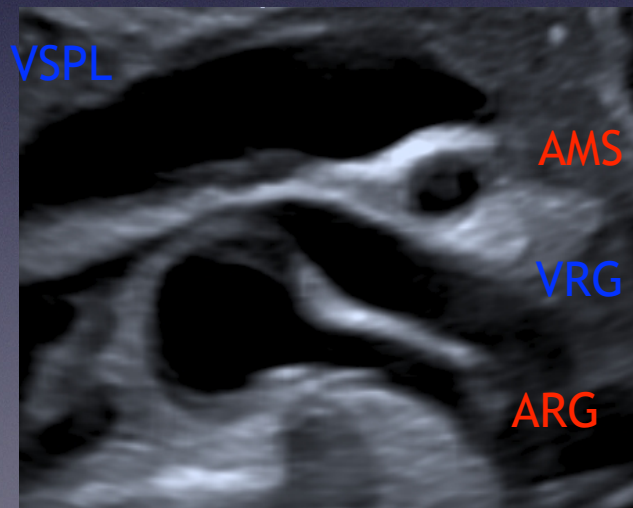
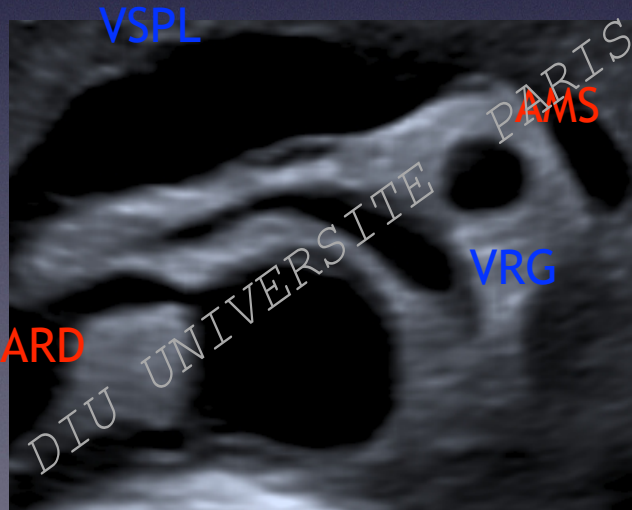
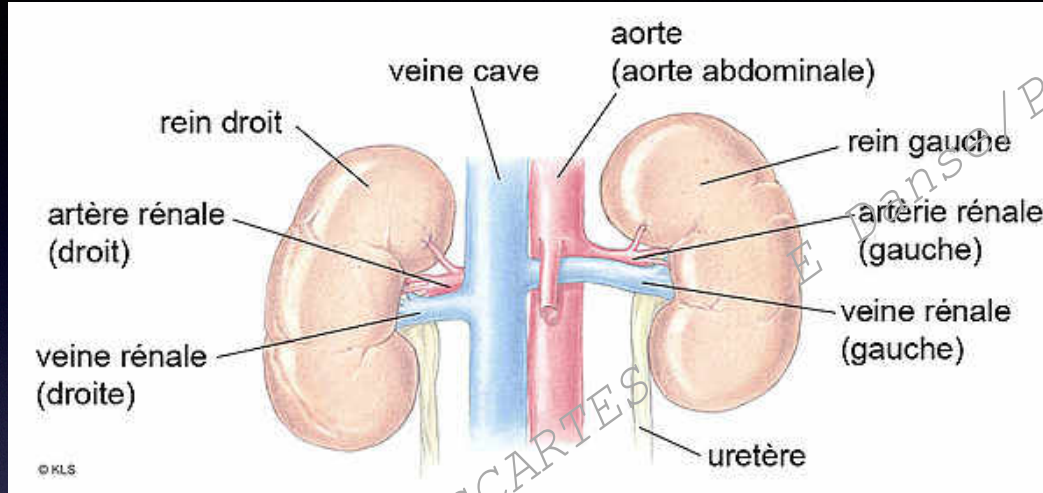
3 à 6 cm de la bifurcation

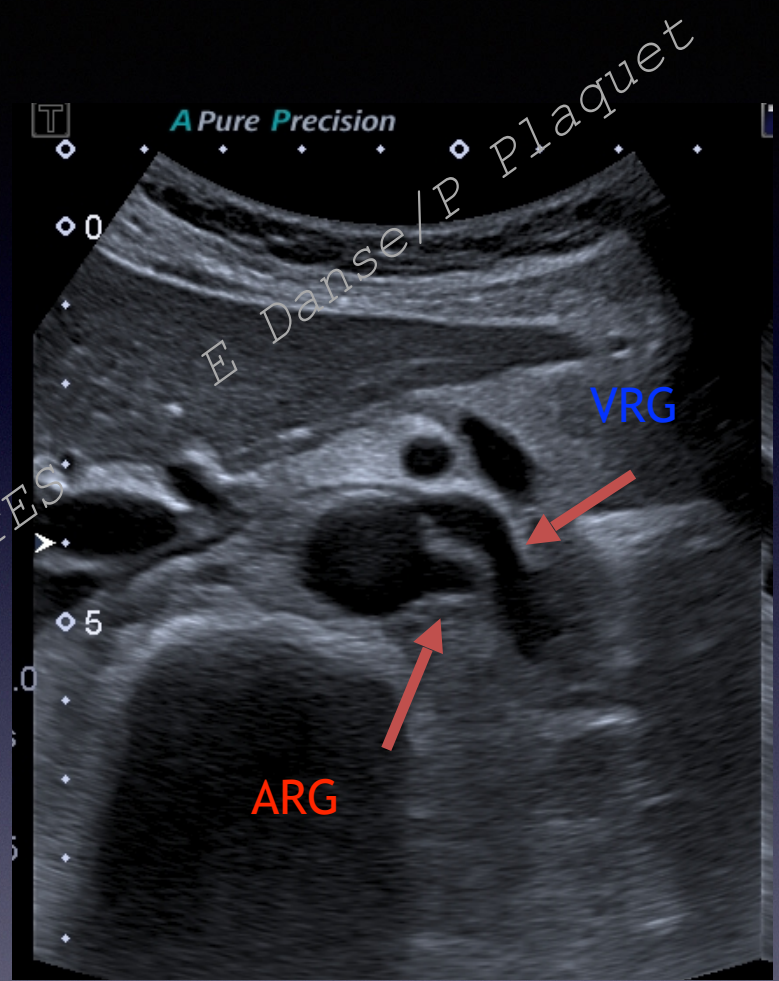
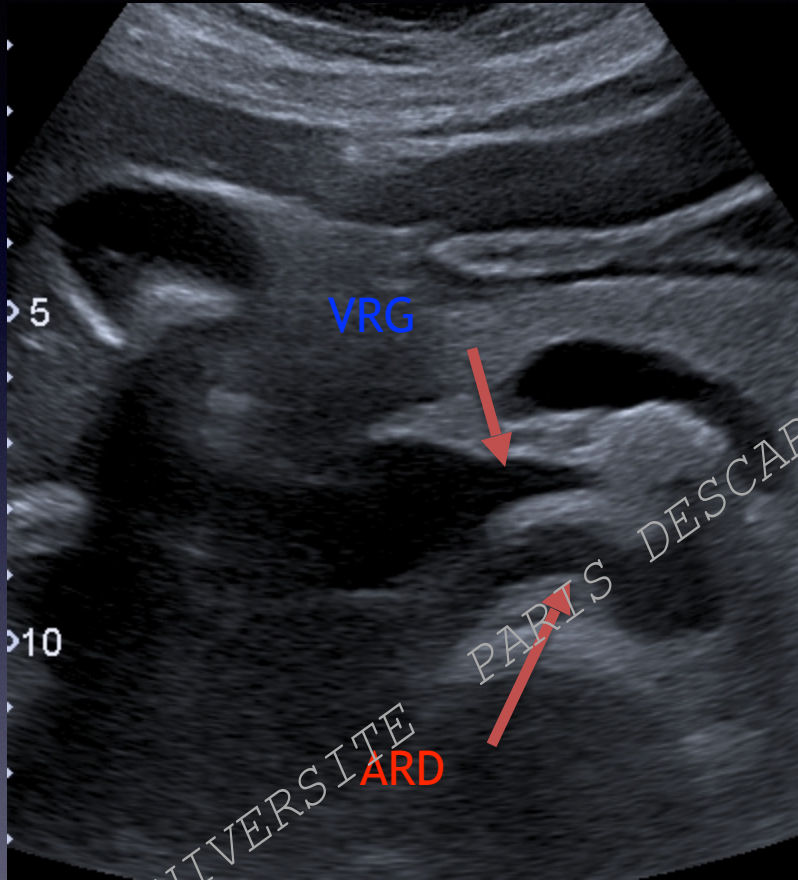
Diamètre 3 à 6 mm

Flux triphasique pic syst  $< 120$  cm/s



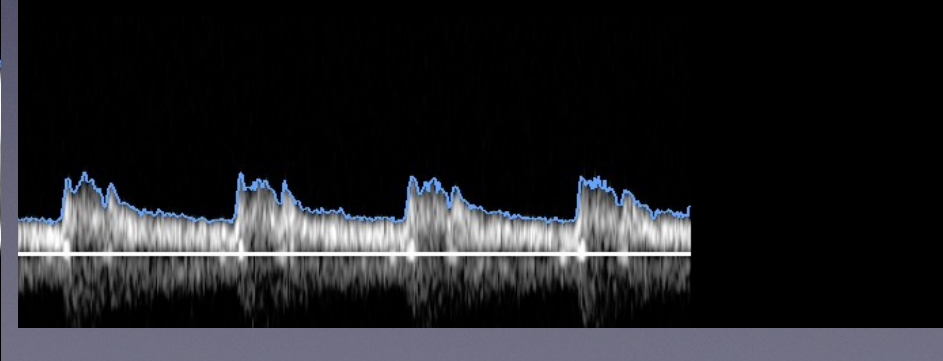
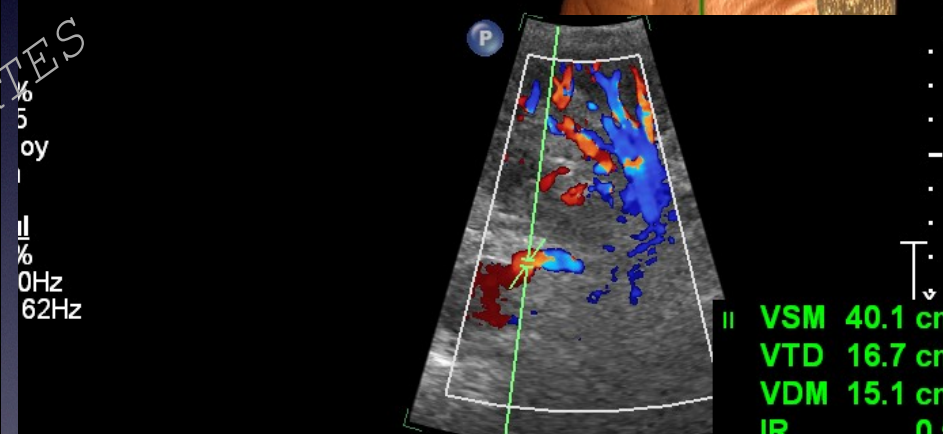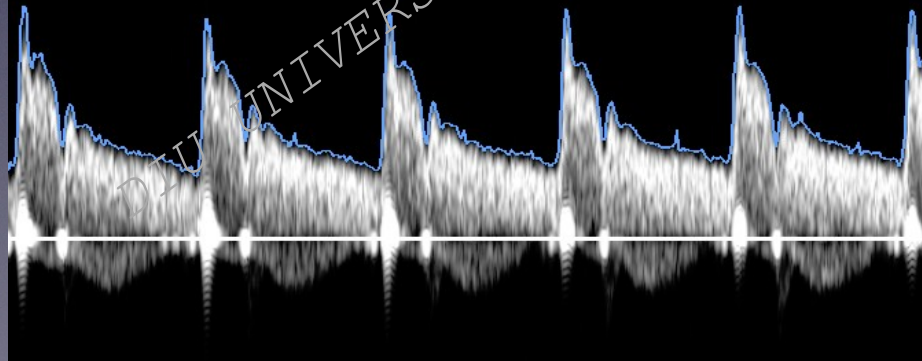
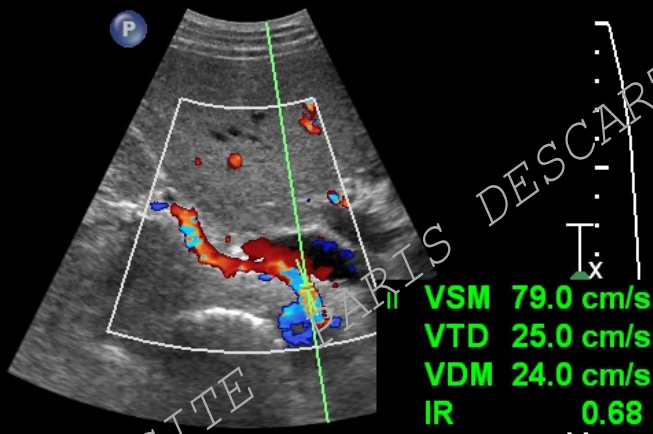
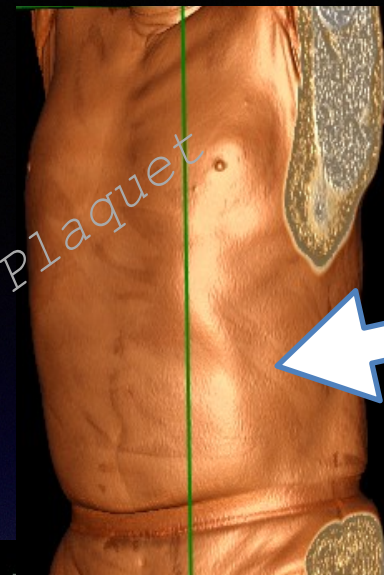
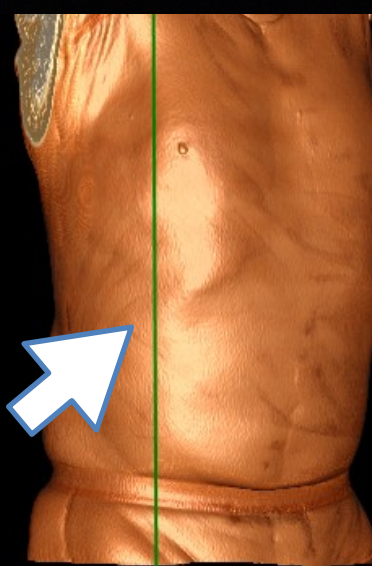
# Vaisseaux rénaux



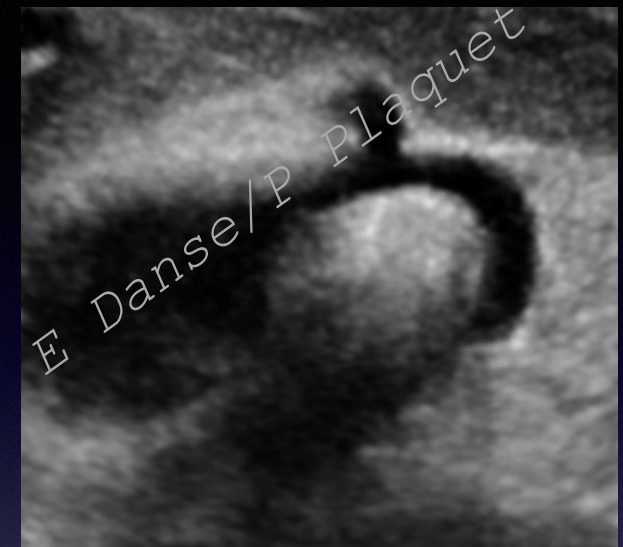

DIU UNIVERSITE

# Artères rénales

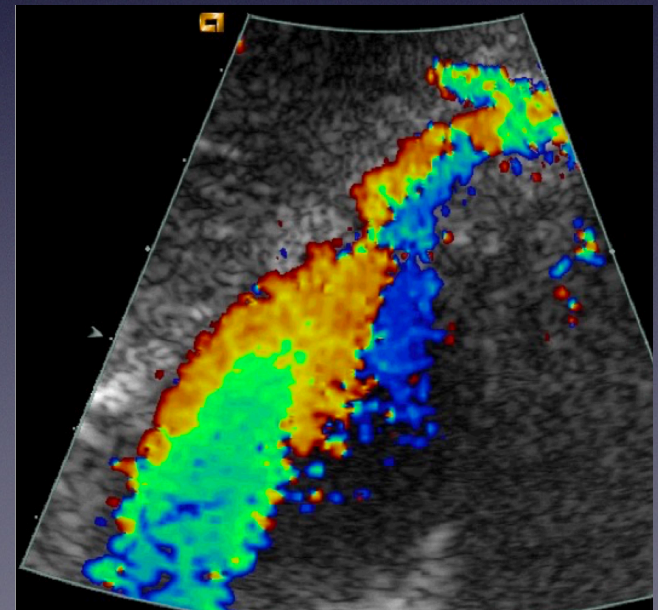


# Tronc coeliaque

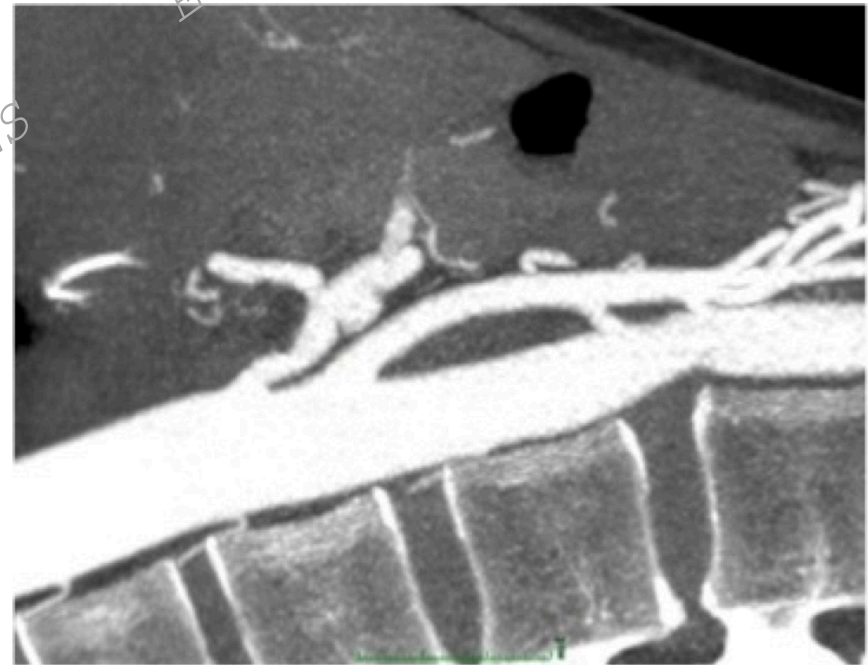
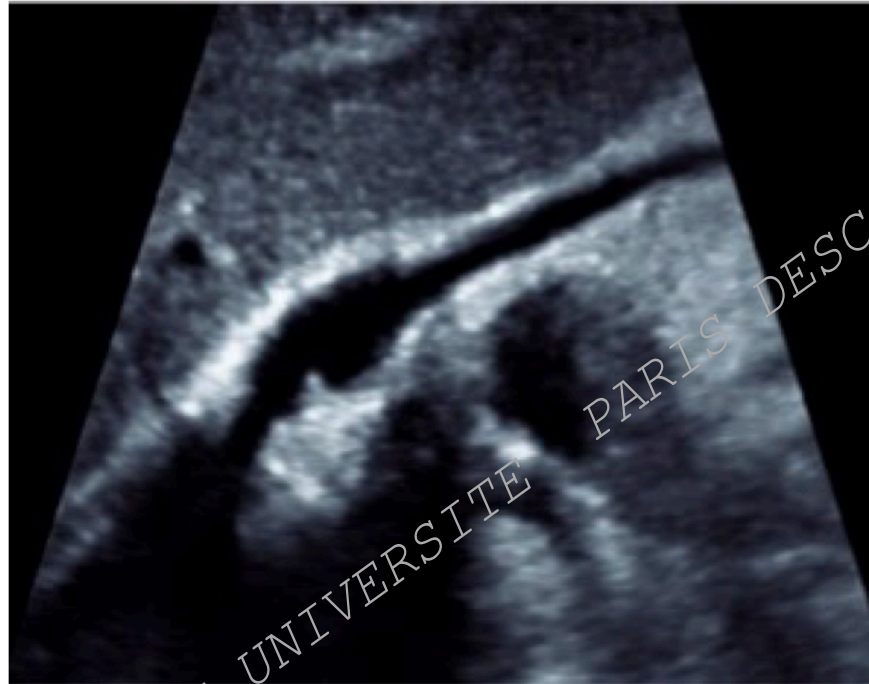
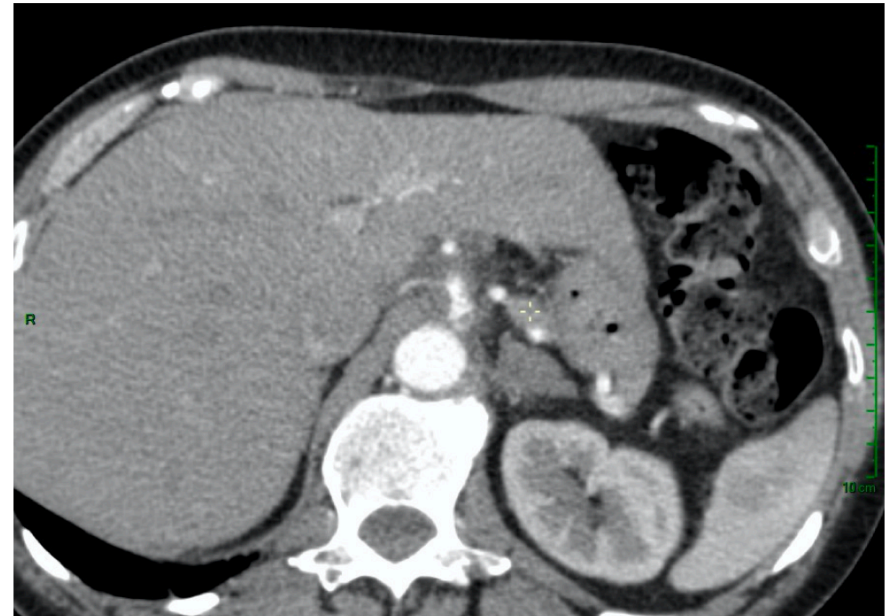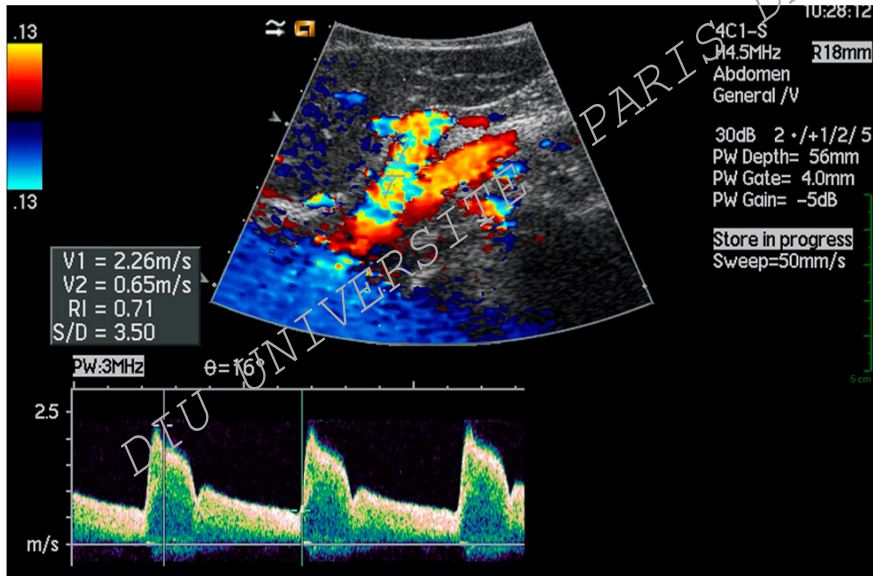
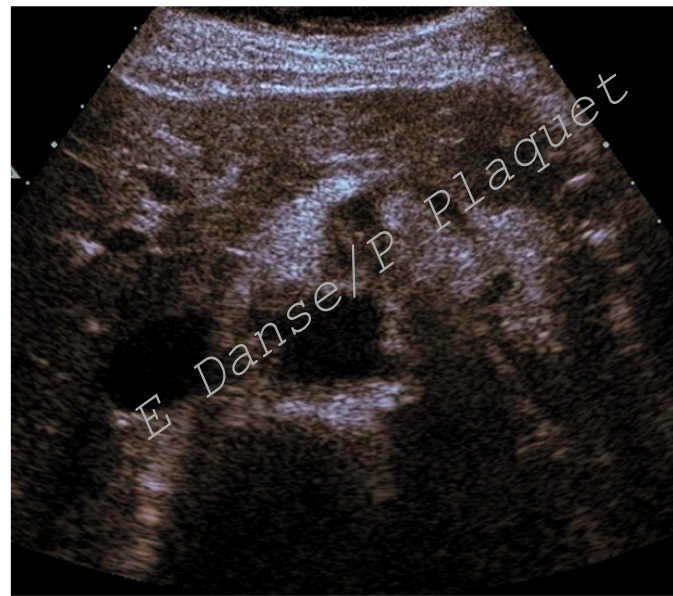
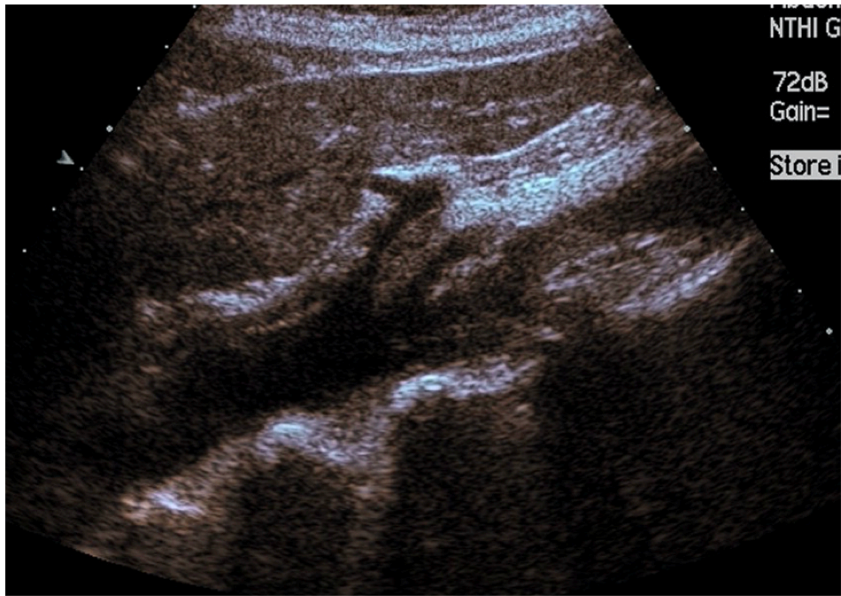
Réseau interconnecté ,  
collatéralité  
Calibre inhabituel perméabilité  
, anévrisme , thrombose

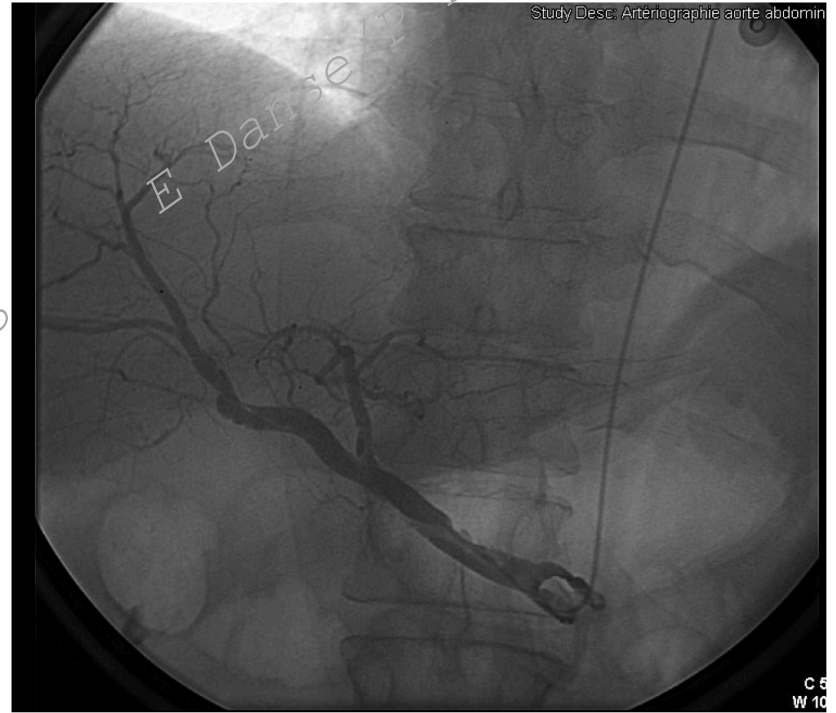
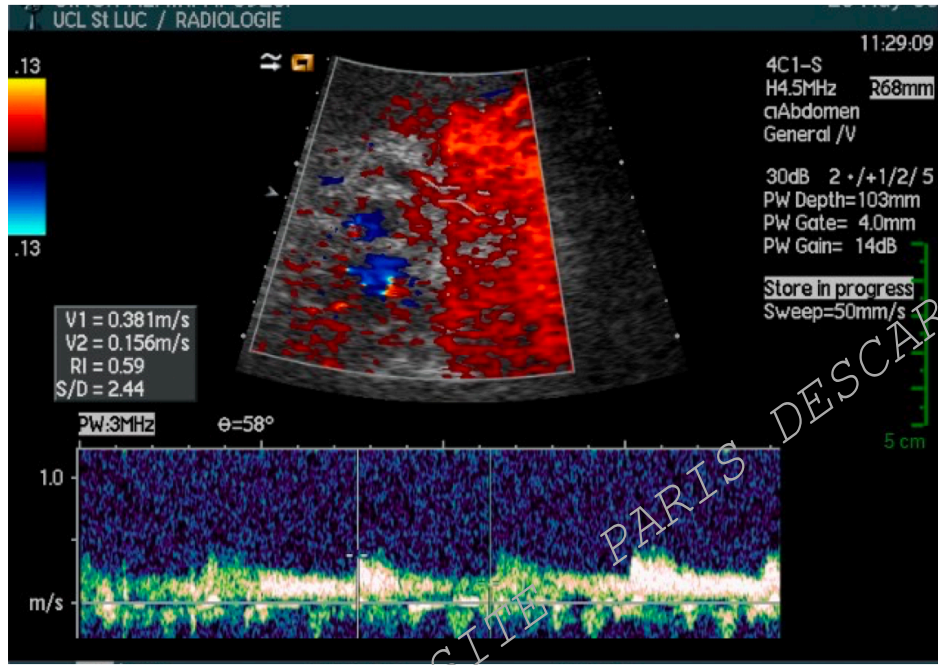
Tronc coeliaque :  
dissection



# Tronc coeliaque : dissection







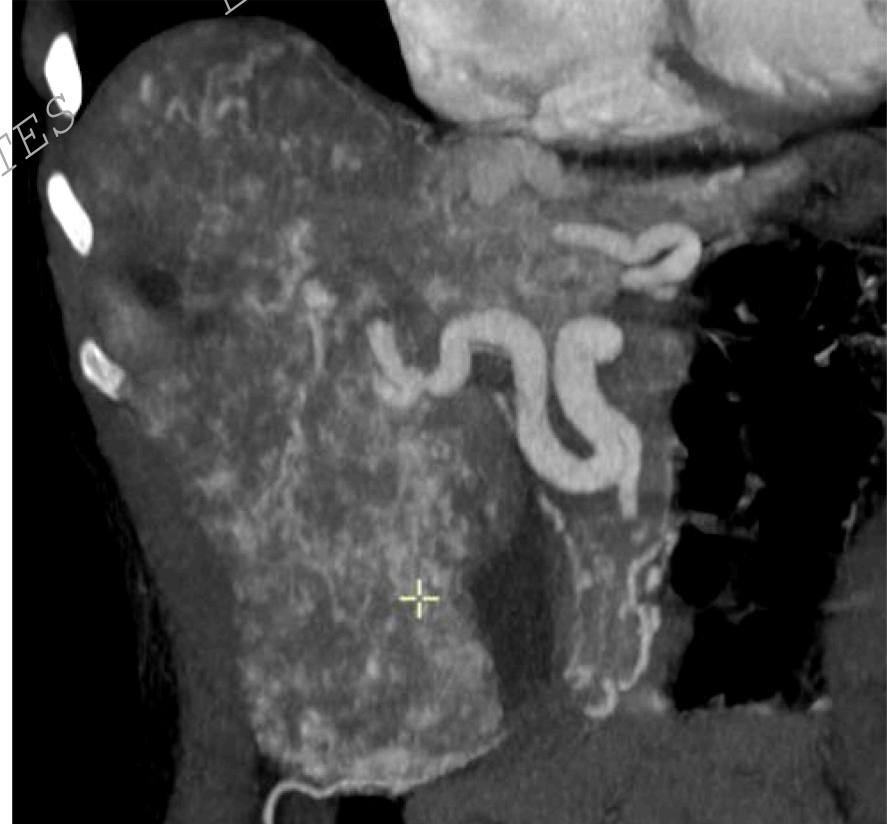
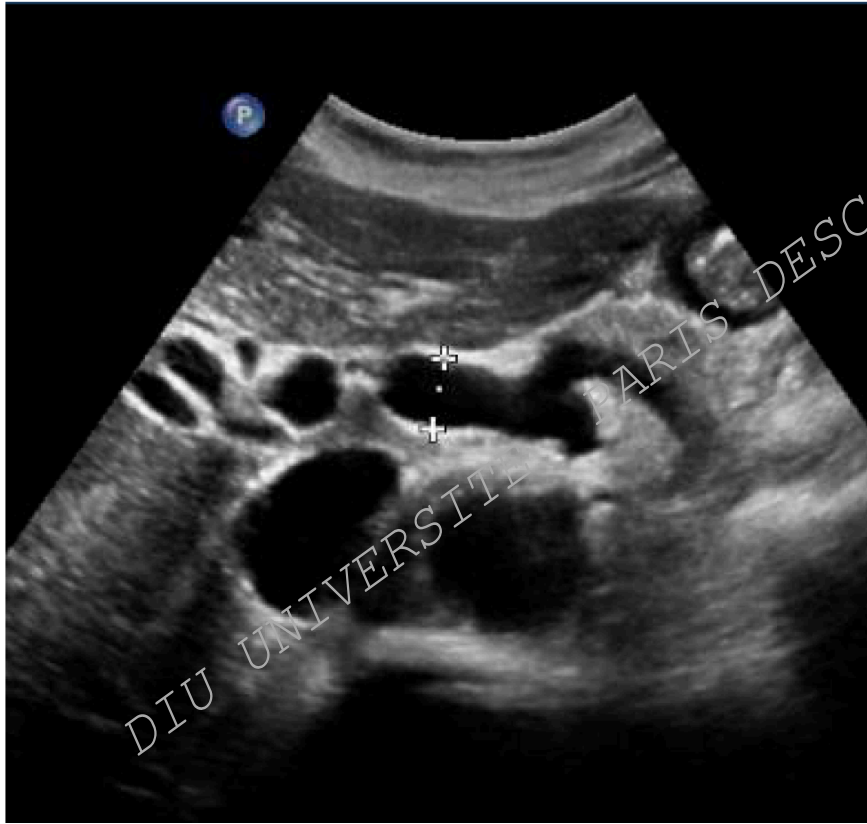DIU UNIVERSITE PARIS DESCARTES

PARIS DESCARTES

Plaquet

# Osler Rendu

E Danse/P Plaquet

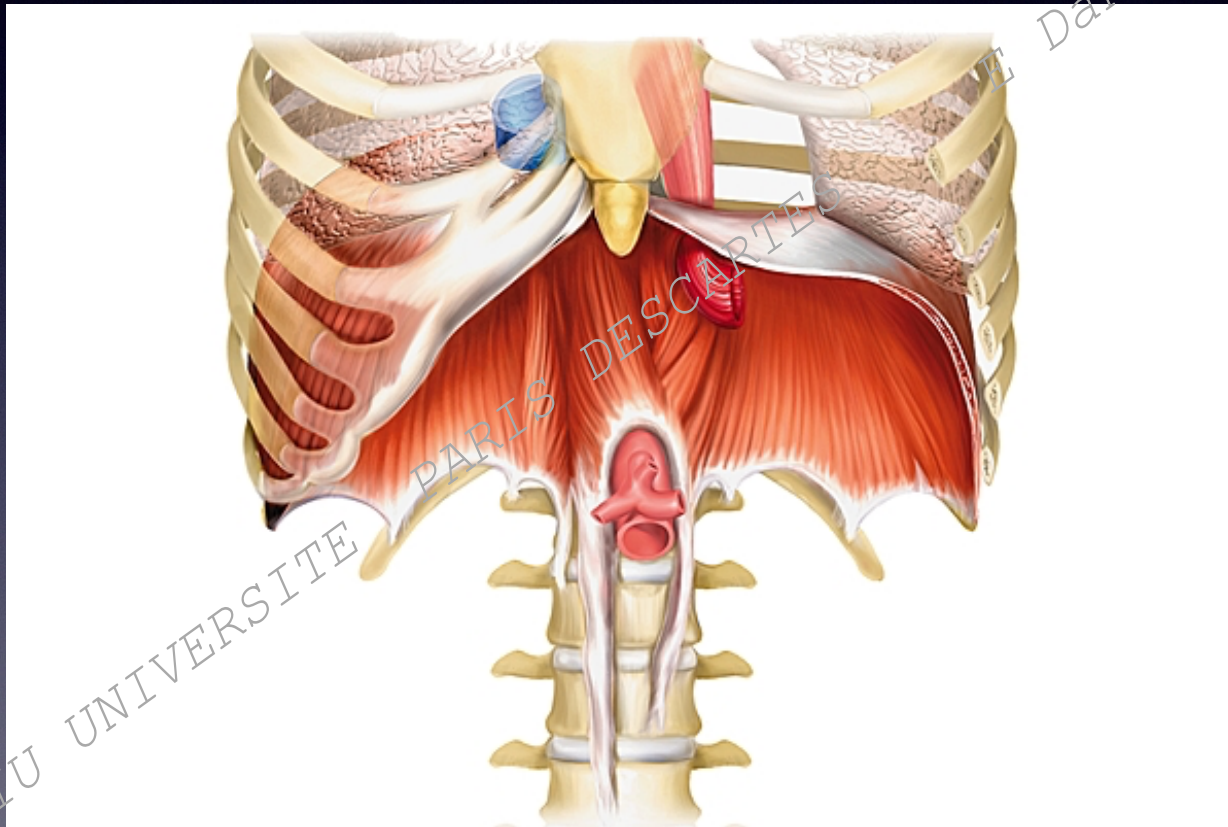




# Ligament arqué

Hiatus fibreux diaphragmatique  
inextensible

tronc coeliaque trop haut



# Ligament arqué

Compression sténose  
hémodynamiquement  
significative

$v > 200 \text{ cm/s}$

Image en crochet  
Disparité de calibre  
Aliasing

Signes digestifs post prandiaux  
Douleurs vomissements  
Souffle

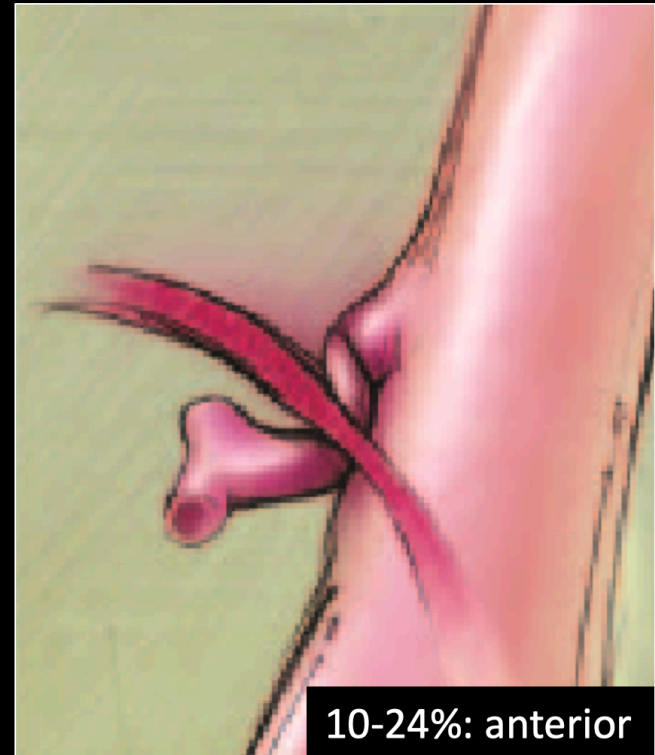
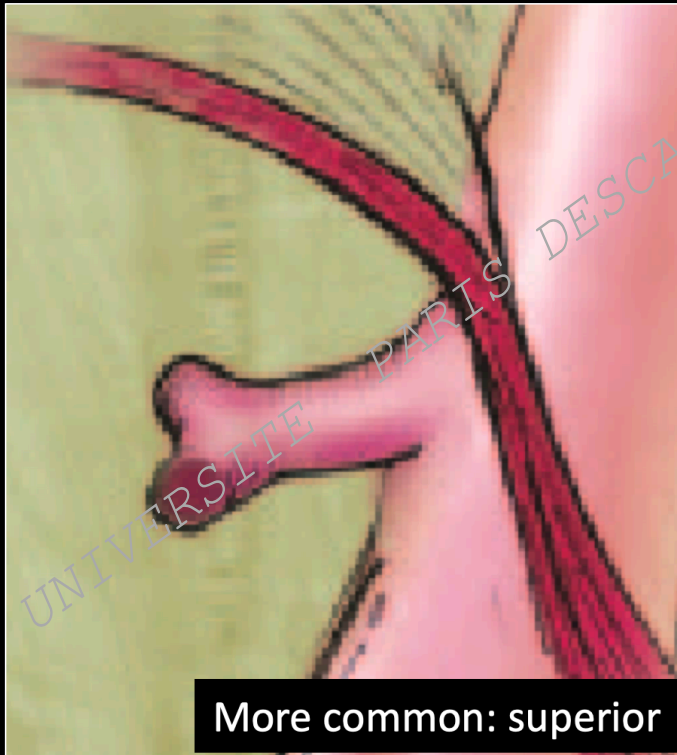
E Danse/P Plaquet

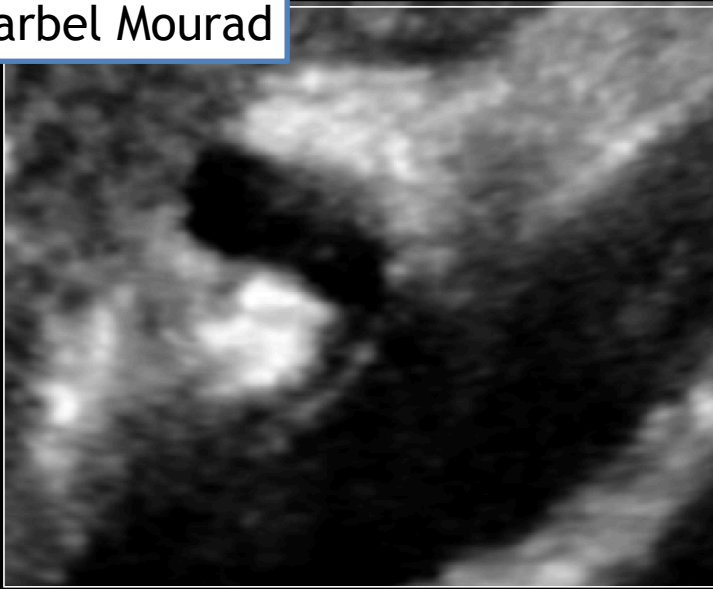
DIU UNIVERSITE PARIS DESCARTES

DIU UNIVERSITE

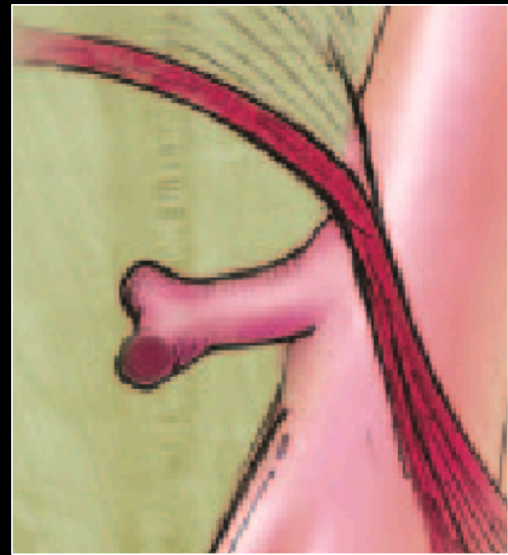
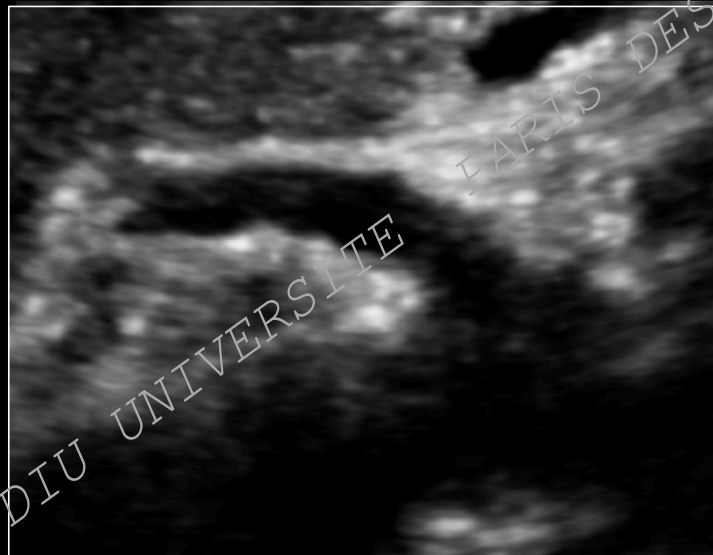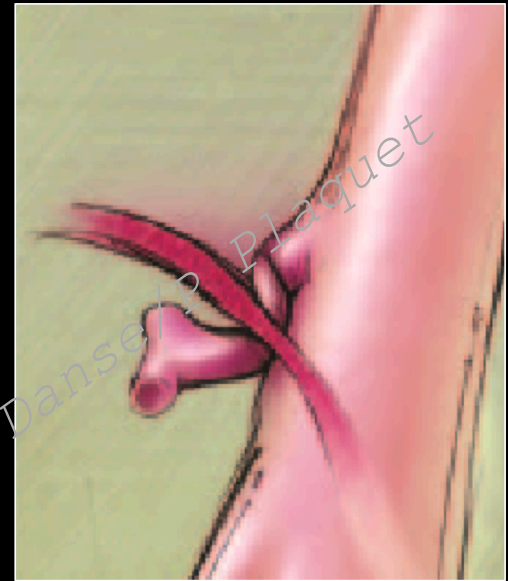
# Median arcuate Ligament

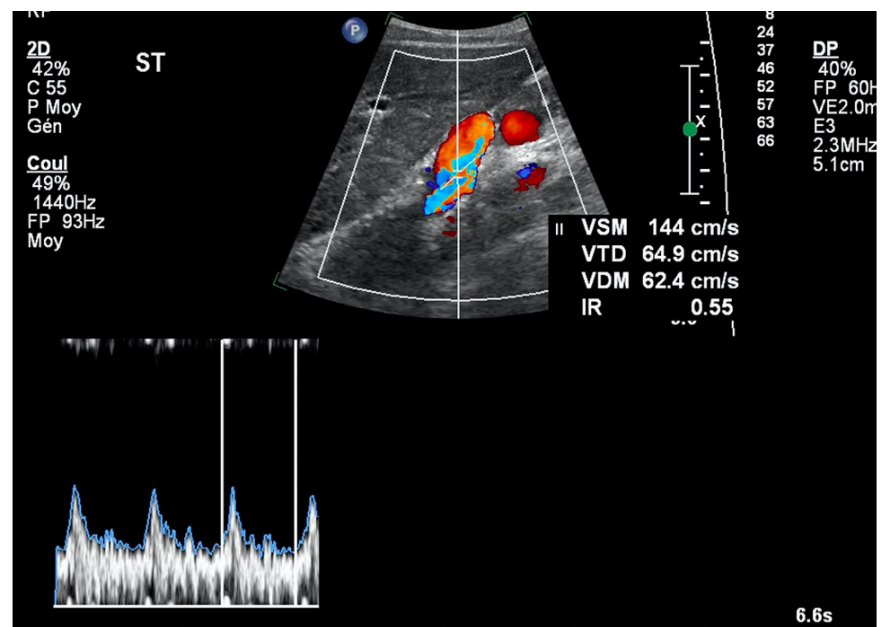
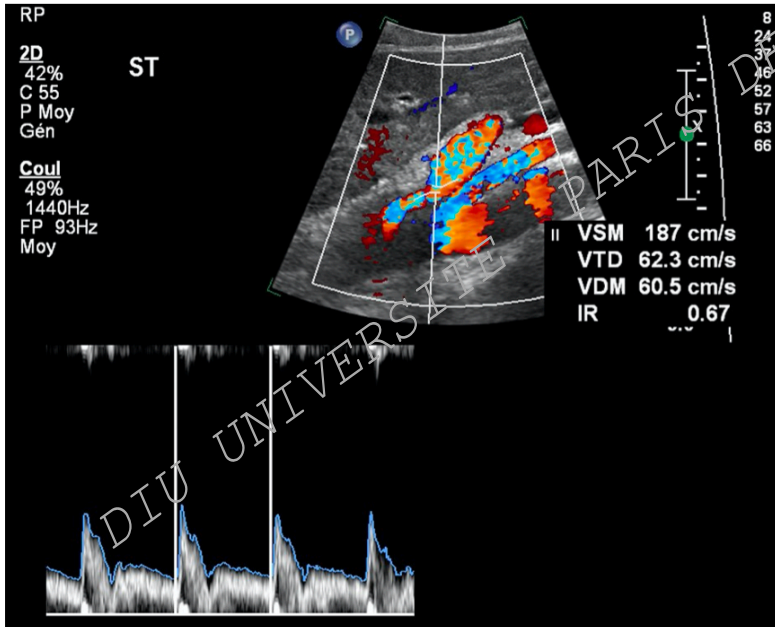
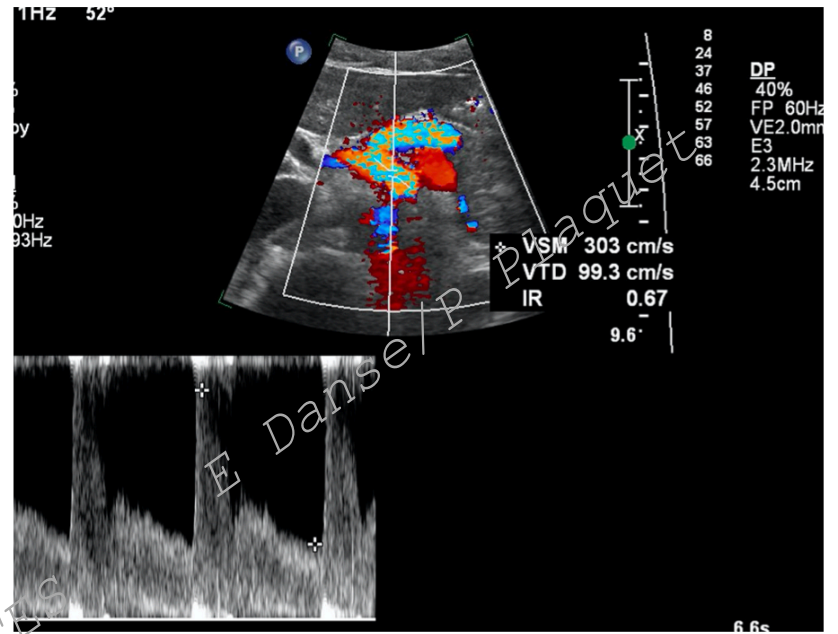
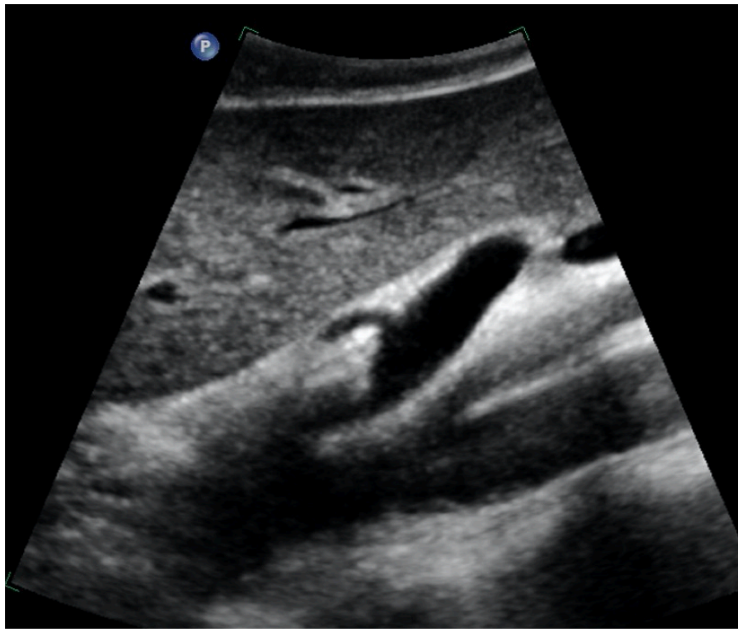- Fibrous band that unites the diaphragmatic crura
- At the level of aortic hiatus T12-L1



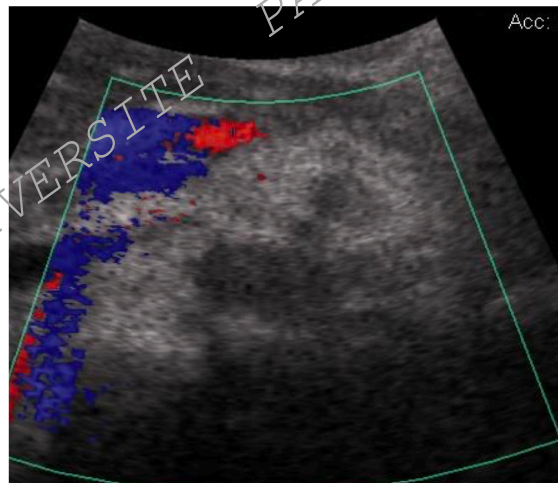
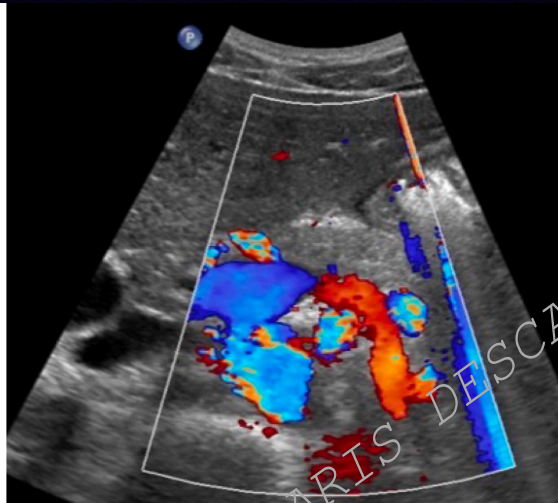


Expiration

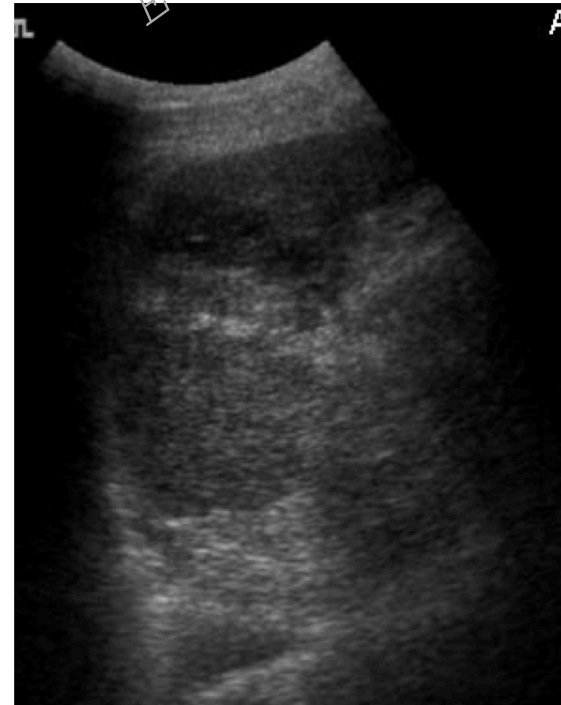



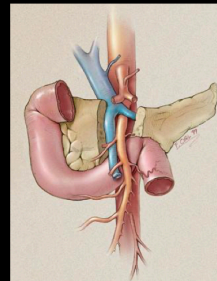
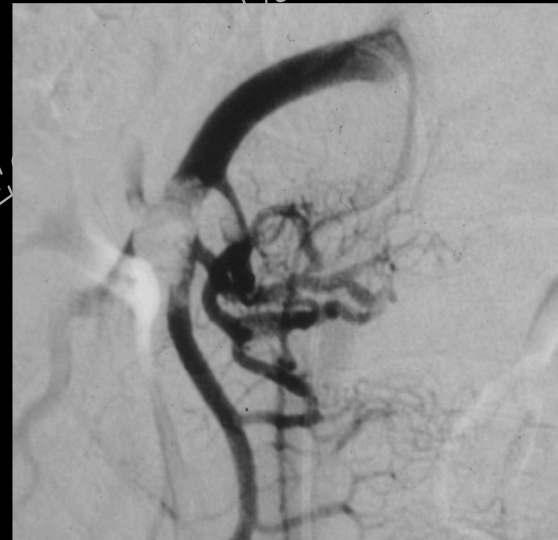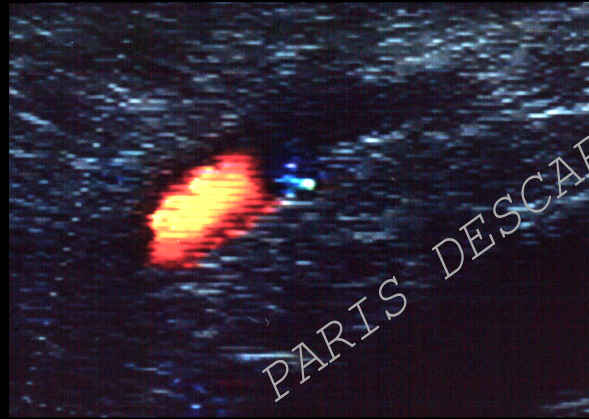
## Artère mésentérique supérieure



## Infarctus mésentérique



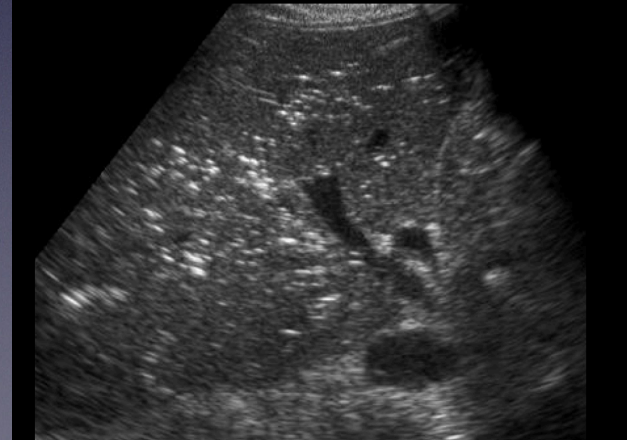
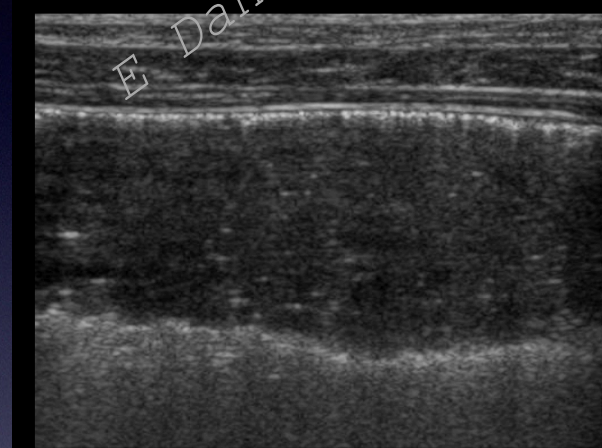
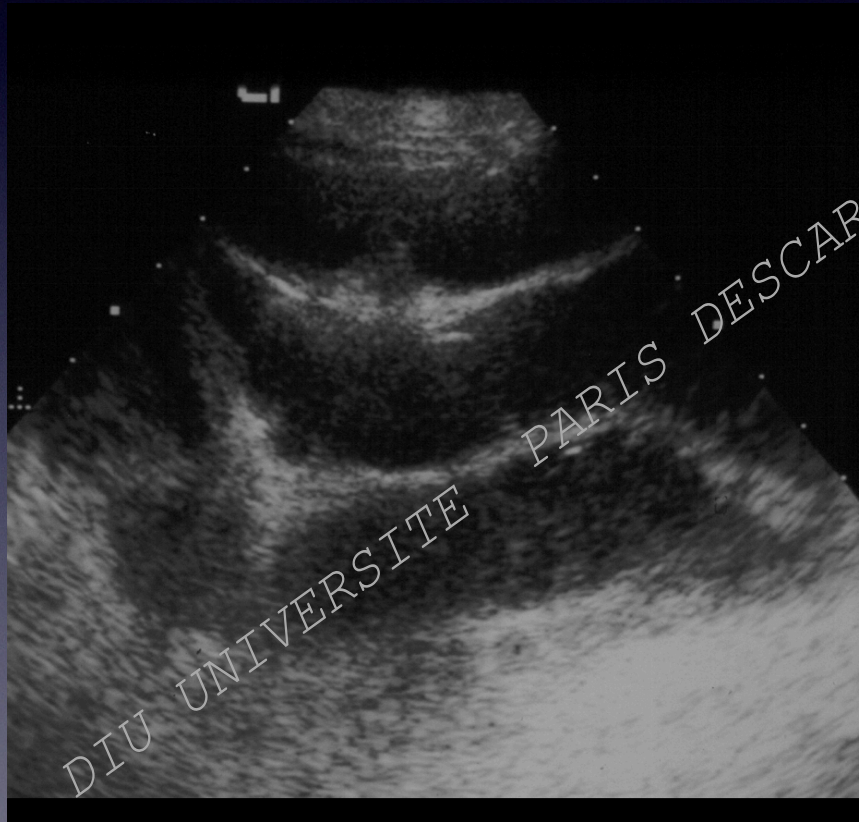
# Infarctus mésentérique



danse/P Plaquet

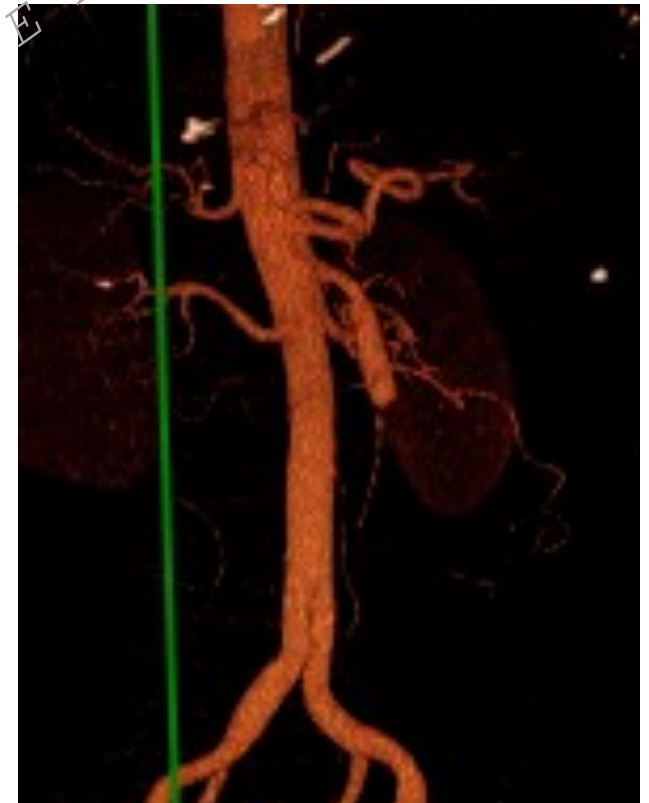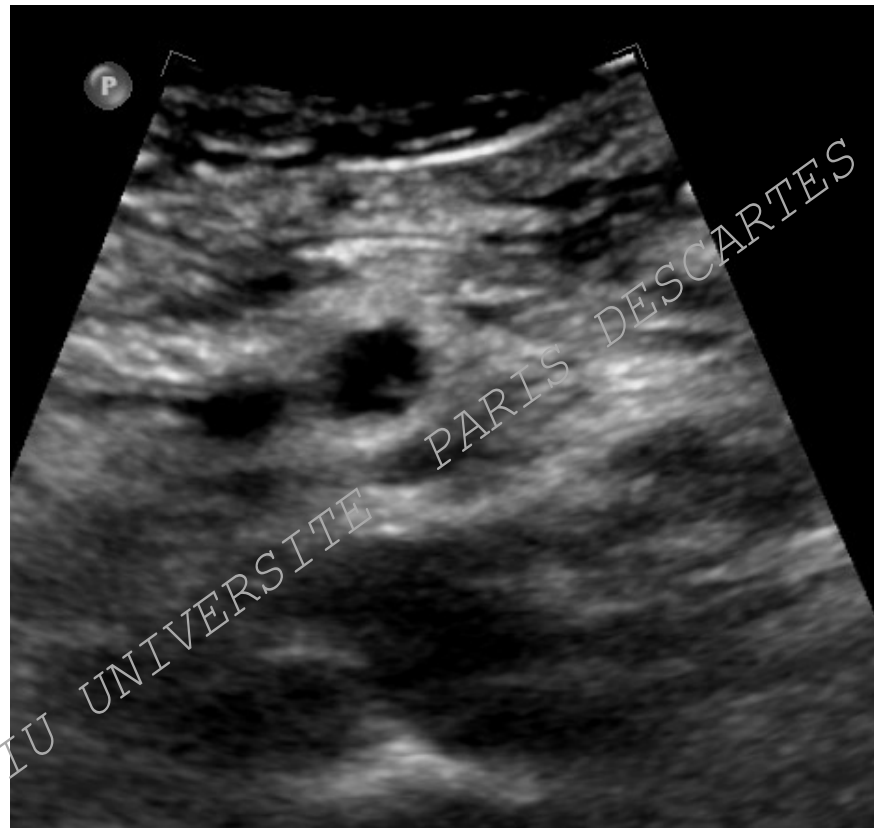DIU UNIVERSITE PARIS DESCARTE

# Infarctus mésentérique

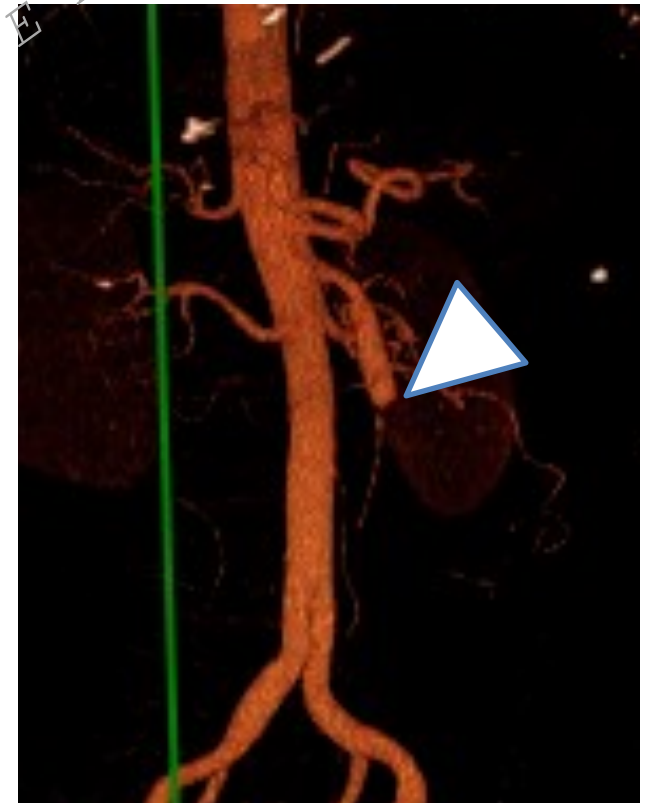
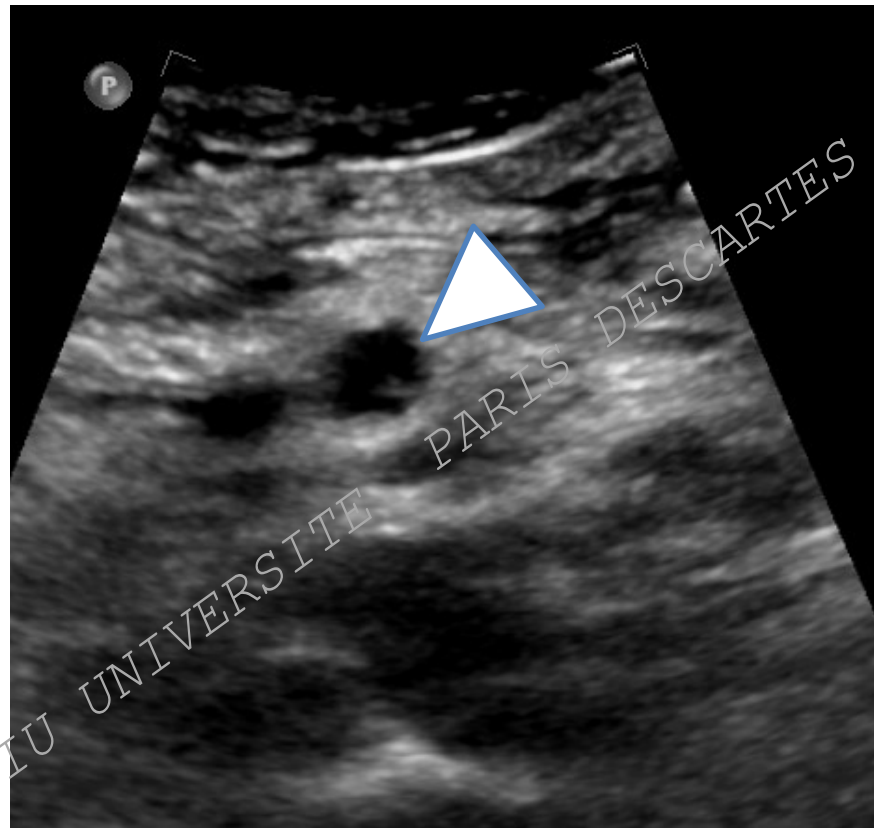




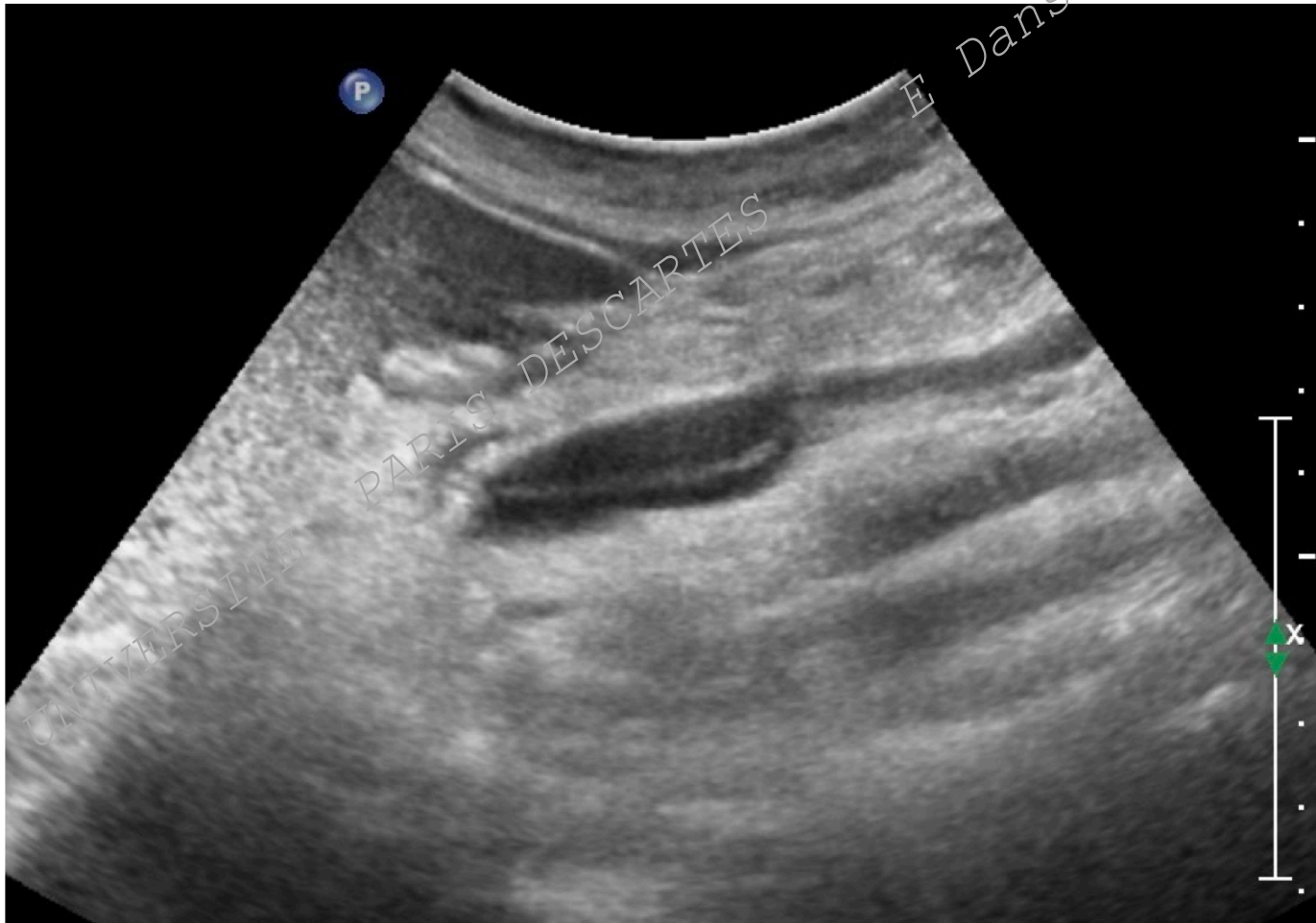
# Infarctus mésentérique et dissection AMS



# Infarctus mésentérique et dissection AMS



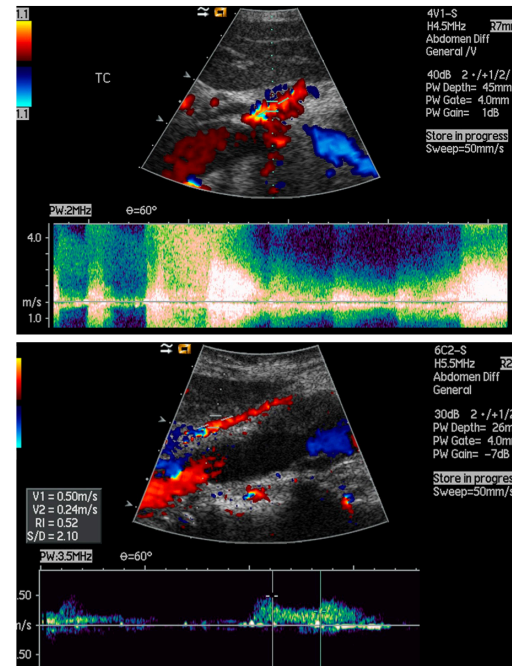
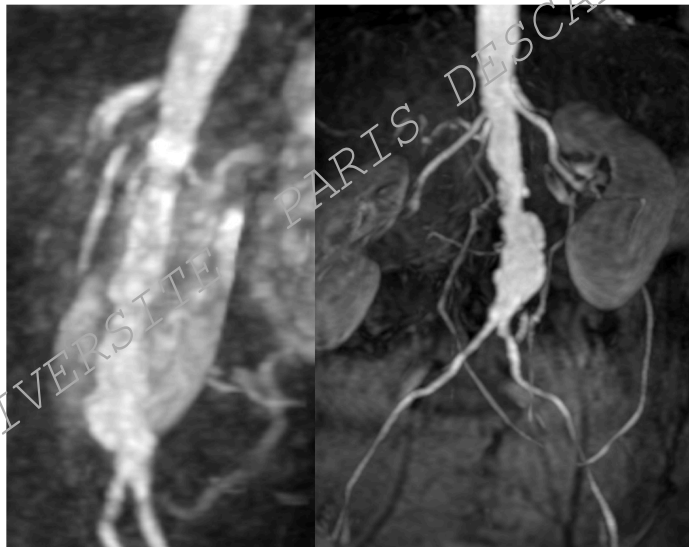
# Infarctus mésentérique et dissection AMS

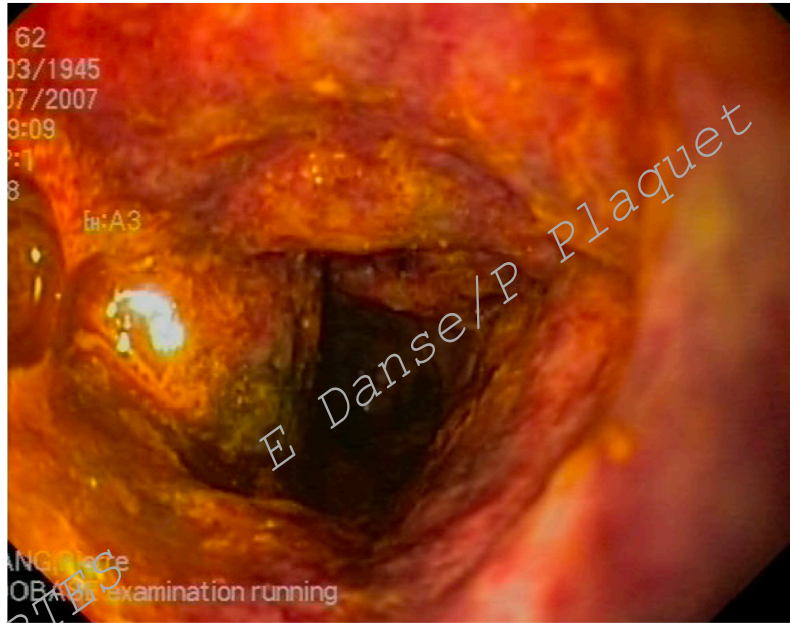
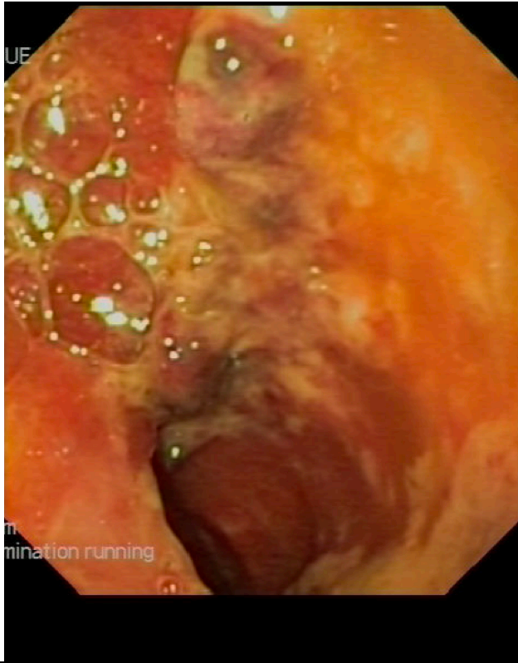


# Colite ischémique

« Chronique »

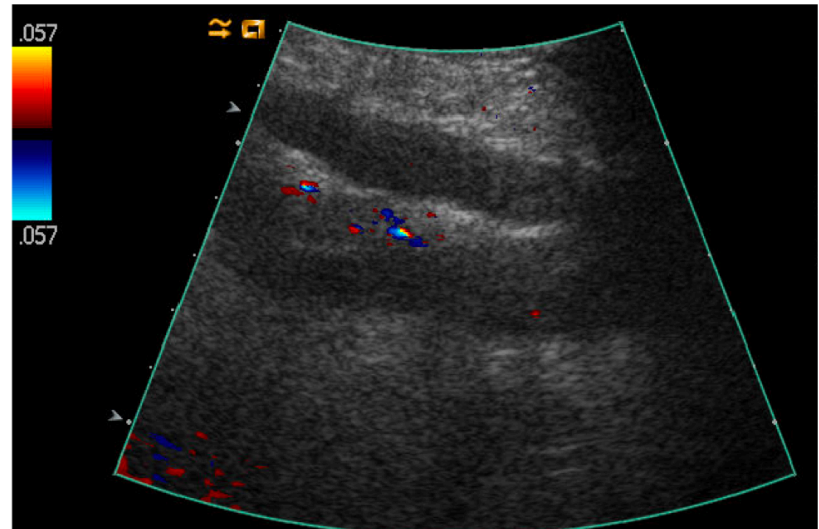
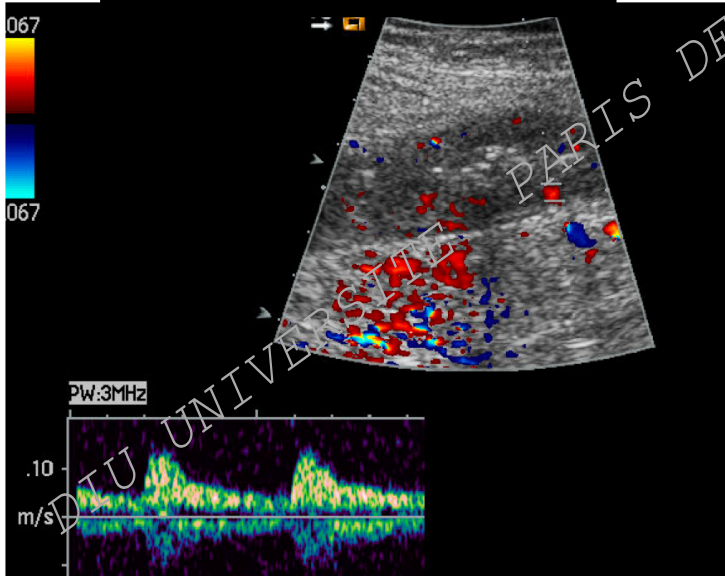
## US Doppler et colite ischémique





a

c

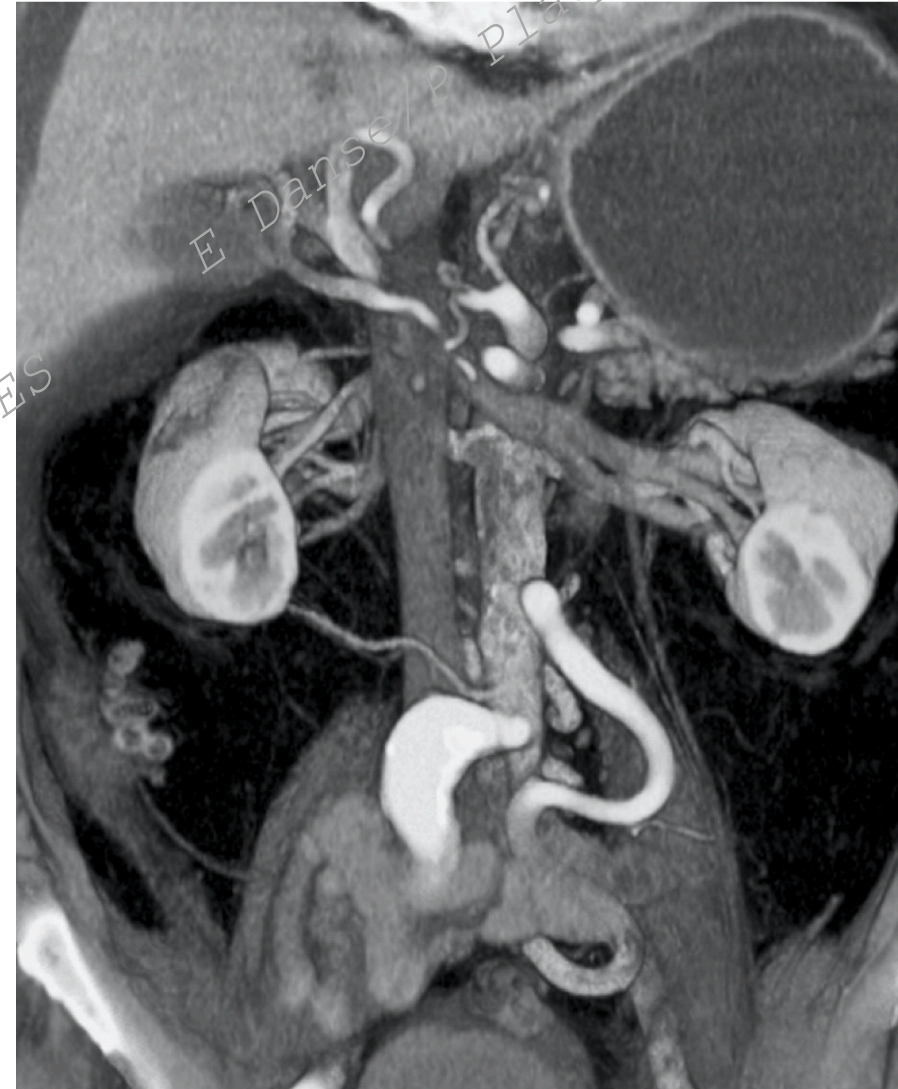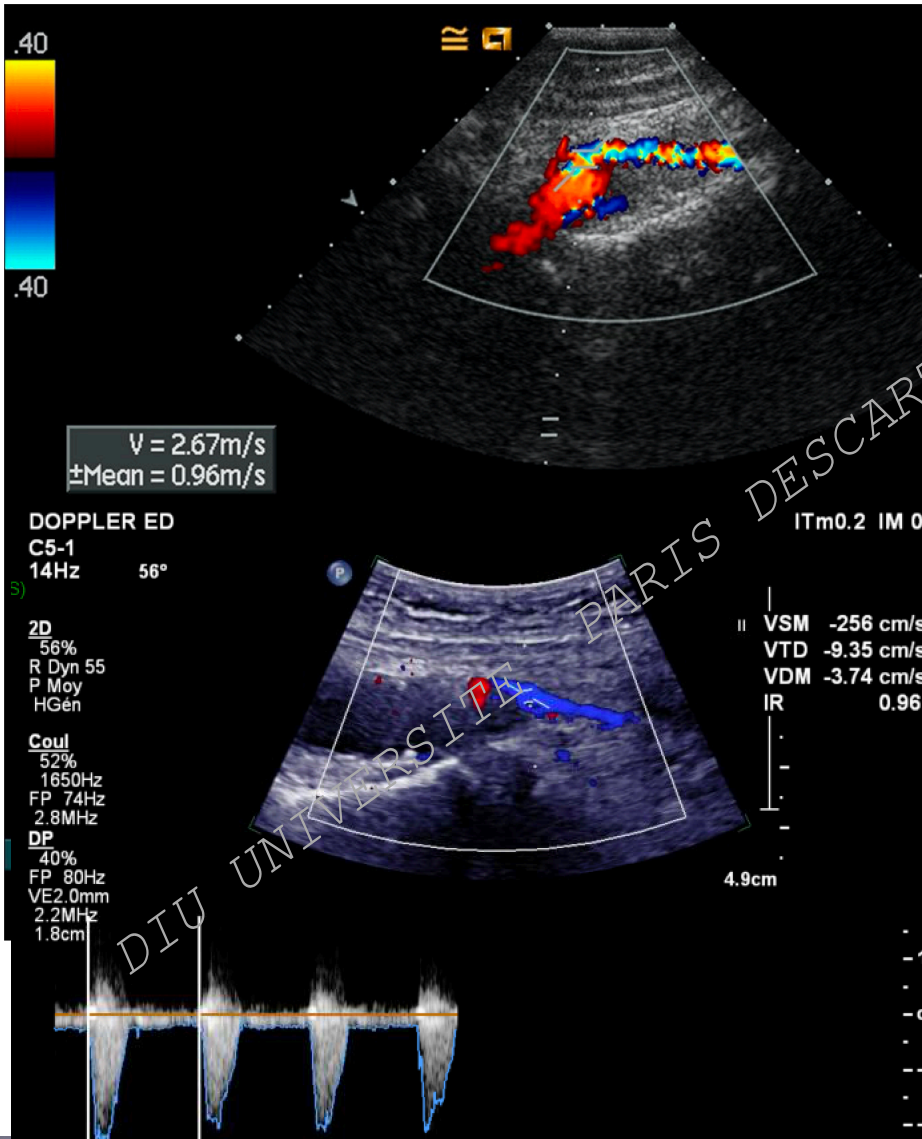


d

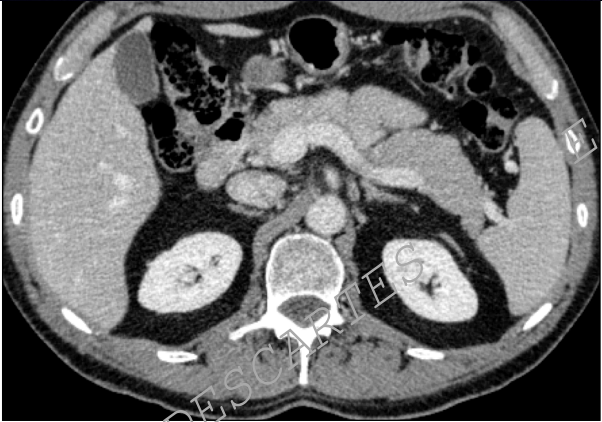
Résolution spontanée

Chirurgie pour nécrose

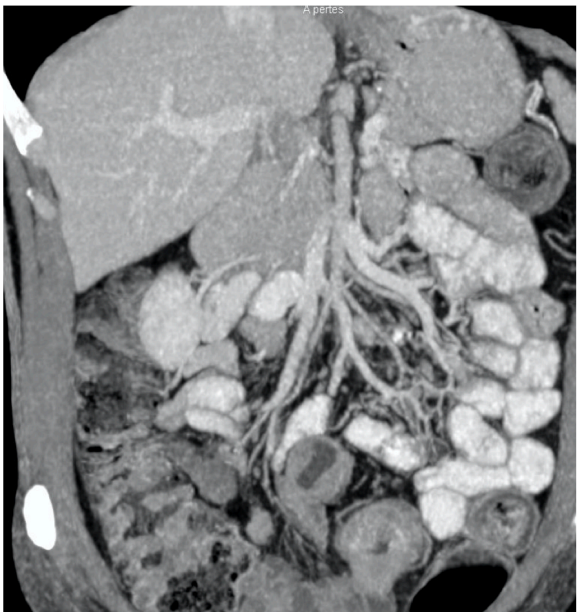
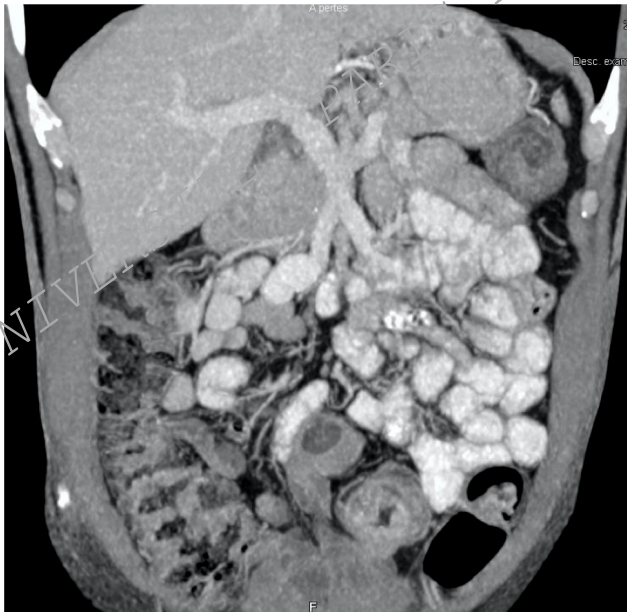# ANGOR INTESTINAL : sténose &/ou occlusions de 2 des 3 vx digestifs : TC, AMS-aml



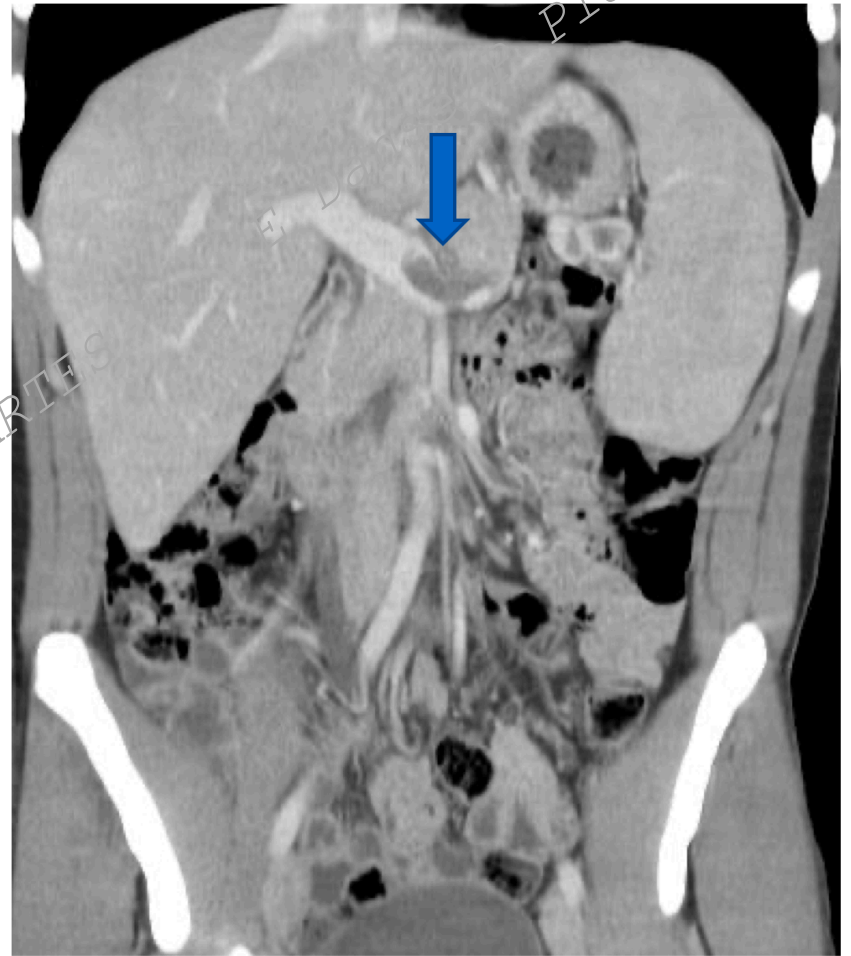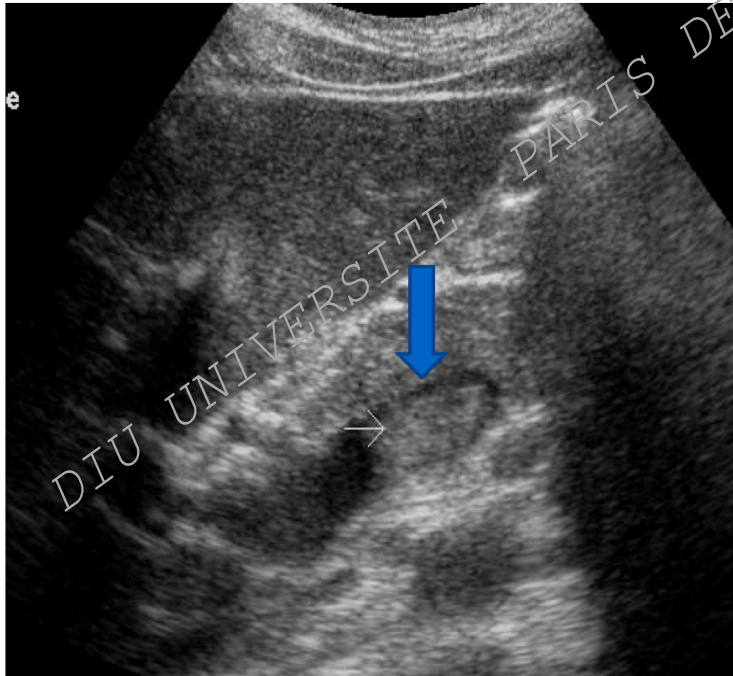
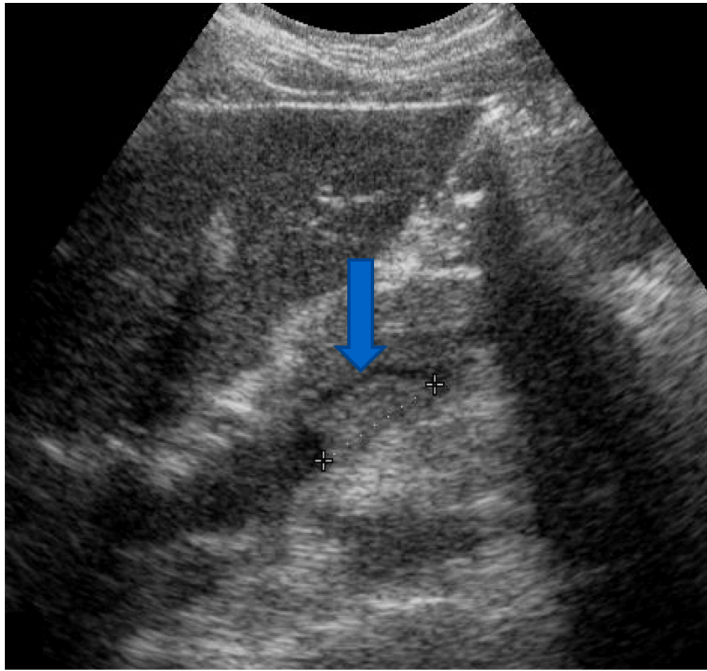
# Infarctissement mésentérique



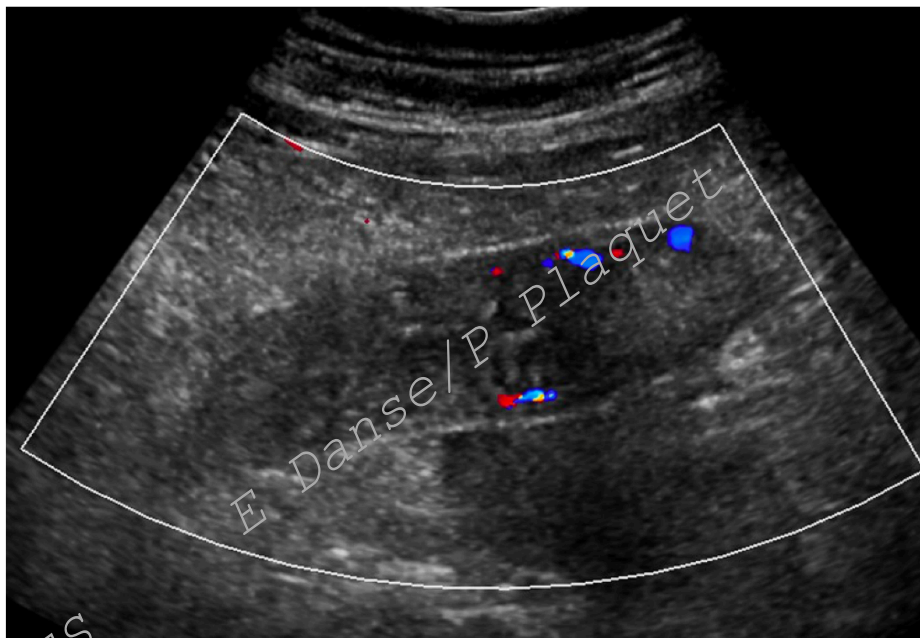
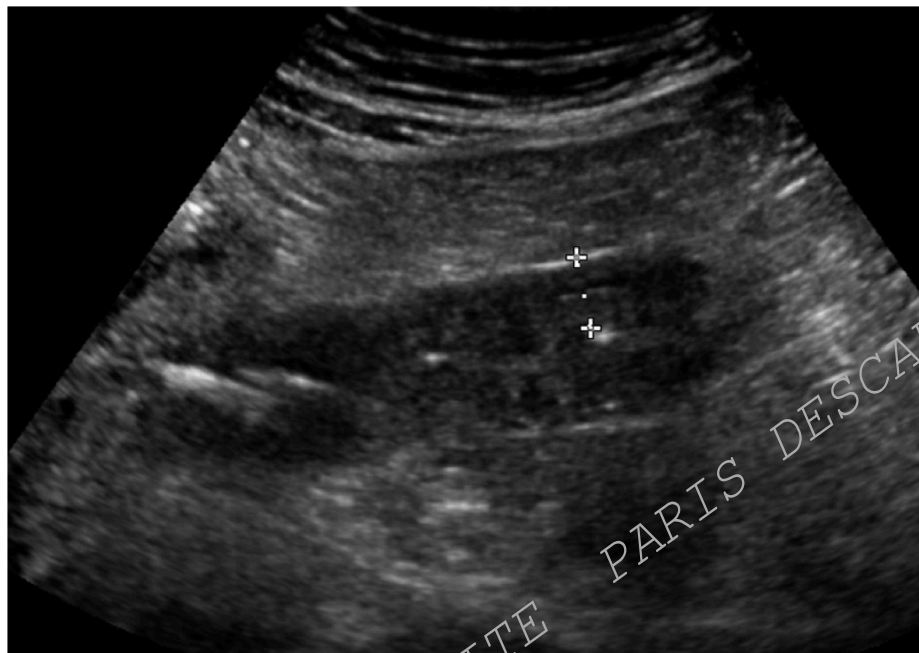Danse/P  
Plaquet



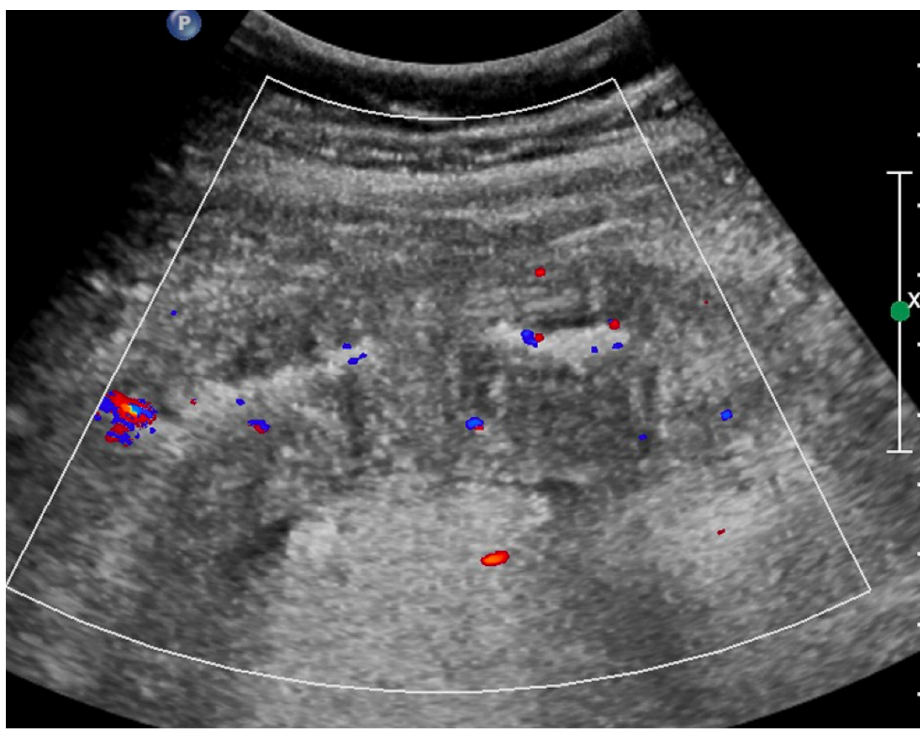
DIU UNIVL







DIU UNIVERSITE PARIS DESCARTES



réglages +++, changement de sondes  
et de fréquences  
Connaissance topographique  
balayage méthodique

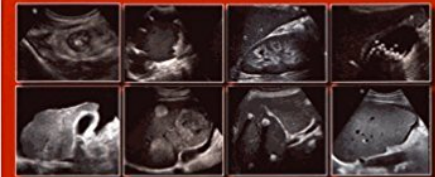
on ne trouve que ce que l'on cherche et  
que ce que l'on connaît

Merci de votre attention



# ÉCHOGRAPHIE ABDOMINALE de l'adulte

Etienne DANSE



SALRAMPS  
SOCIÉTÉ FRANÇAISE D'ÉCHOGRAPHIE